

# Osseous Proliferation of the Mandible after Placement of Endosseous Implants

Hidetaka Nakai, DDS<sup>1</sup>/Atsushi Niimi, DDS, DMSc<sup>2</sup>/Minoru Ueda, DDS, PhD<sup>3</sup>

*Spontaneous alveolar ridge growth in the posterior region of the mandible following placement of endosseous implants is reported. The study included 27 patients with totally edentulous mandibles and fixed prostheses supported by osseointegrated implants placed between the mental foramina. In 5 patients, an increase in the height of the alveolar crest was observed in the molar region; the increase ranged from 3.3% to 8.6%. This osseous proliferation may be a physiologic response to stress distribution in the molar region. (INT J ORAL MAXILLOFAC IMPLANTS 2000;15:419-424)*

**Key words:** alveolar process, endosseous dental implantation, mandible, osteogenesis

One structure may be affected by the functional stress applied to it. During occlusal function, the mandible absorbs the force applied by the muscles of mastication and also the load transmitted through the natural teeth or superstructures supported by osseointegrated implants. Evidence of increased radiographic density of the bone around the loaded osseointegrated implants has been reported.<sup>1,2</sup> This increased density is considered to be the physiologic response of the bone structure to functional stress.

However, a few authors have reported spontaneous subpontic osseous proliferation and have suggested that function is a major factor in such proliferation.<sup>3,4</sup> However, the actual rationale for this phenomenon is still unknown.

This paper reports alveolar ridge growth in the posterior region of the mandible associated with osseointegrated implant reconstruction.

## MATERIAL AND METHODS

### Patients

This study included 27 patients (11 females and 16 males) with completely edentulous mandibles and fixed prostheses supported by osseointegrated implants placed between the mental foramina. Patients who had undergone mandibular resection for the treatment of tumors or had systemic or metabolic disorders were not included. Patient age ranged from 39 to 84 years, with an average age of 66.3 years.

In all patients, Brånemark System implants (Nobel Biocare AB, Göteborg, Sweden) were used, and the implants had been placed following the method described by Brånemark et al<sup>5</sup> and Albrektsson et al.<sup>6</sup> Eight patients had 6 implants each, and the other 19 patients had 5 implants each between the mental foramina. In the opposing arch, 8 patients had a conventional complete denture, 5 patients had a conventional removable partial denture, 4 patients had natural teeth only, 5 patients had a fixed prosthesis supported by osseointegrated implants, and 5 patients had an implant-retained overdenture. Follow-up periods after fabrication of the implant-supported fixed mandibular restorations ranged from 9 to 66 months.

### Analysis

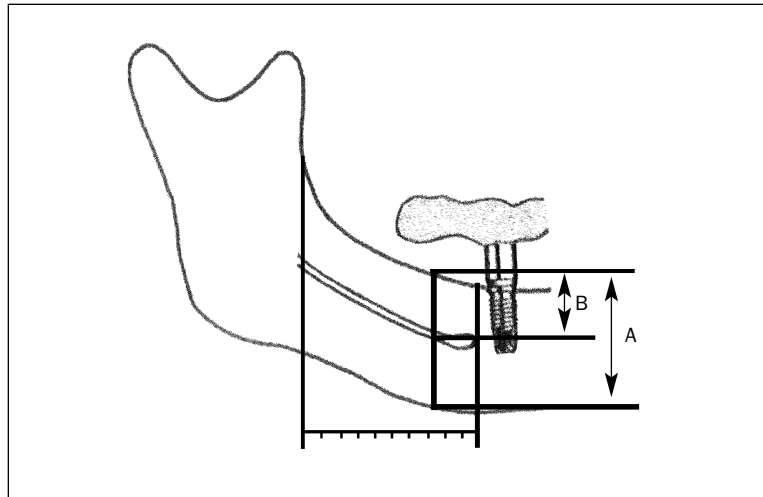
Panoramic radiographs were evaluated for the present analysis. The same machine and the same method were used for taking radiographs in all patients. Radiographs taken with angulation that obviously differed from the other radiographs were not used for measurement. Periapical film was not

<sup>1</sup>Instructor, Department of Oral & Maxillofacial Surgery, Nagoya University Postgraduate School of Medicine, Nagoya, Japan.

<sup>2</sup>Assistant Professor, Department of Oral & Maxillofacial Surgery, Nagoya University Postgraduate School of Medicine, Nagoya, Japan.

<sup>3</sup>Professor and Chairman, Department of Oral & Maxillofacial Surgery, Nagoya University Postgraduate School of Medicine, Nagoya, Japan.

**Reprint requests:** Dr Hidetaka Nakai, Department of Oral & Maxillofacial Surgery, Nagoya University Postgraduate School of Medicine, 65 Tsuruma-Cho, Showa-Ku, Nagoya 466-8550, Japan. Fax: +81-52-744-2352.



**Fig 1** Method used to calculate the ratio of mandibular bony height ( $B/A$ ).  $A$  = height from the inferior border of the mandible to the alveolar crest;  $B$  = height from the inferior border of the mandibular canal to the alveolar crest.

suitable to measure the change in bony height at the area away from the implants, because there was no index for measuring the height. For all patients, ratios of the height from the inferior border of the mandible to the alveolar crest and the height from the inferior border of the mandibular canal to the alveolar crest were calculated. These ratios were based on measurements made at 10 points at regular intervals between the implants placed in the most distal region and the ramus of the mandible. Lines used for measurement were drawn perpendicularly from a line connecting the infraorbital borders. The most distal measurement point was determined to be the region at which the perpendicular line passed through the most medial point of the coronoid process and intersected with the body of the mandible (Fig 1). Five examiners made the measurements, and then the average of 3 measurements, except for the highest and lowest, was calculated.

## RESULTS

In 5 patients (3 females and 2 males) aged 57 to 74 years, with an average age of 64 years, there was an increase of more than 3.3% in the height of the bony alveolar crest. This increase occurred in the mandibular molar region distal to the terminal implant (Table 1; Figs 2 to 4). In the panoramic radiographs taken during the follow-up period after fabrication of the superstructure, the superior border of the mandibular alveolar crest was unclear

compared with the radiographs taken before superstructure fabrication and at the time of superstructure fabrication. In the other 22 patients, no significant change was seen in the bone height in the posterior region, and no patients showed a loss of more than 0.6% in bone height in the posterior region (Table 1). In the 5 patients who demonstrated bony growth of more than 3% in the alveolar crest, the increase ranged from 3.3% to 8.6%, and all had 5 implants placed between the mental foramina. Three of the 5 patients had a conventional complete denture in the opposing arch, and the other 2 had a conventional removable partial denture (Fig 5).

## DISCUSSION

Several authors have reported osseous recontouring around osseointegrated implants. Albrektsson<sup>1</sup> reported that radiographic density around implants increased after the application of loads. Adell et al<sup>2</sup> reported in their 15-year study that bone remodeling was seen radiographically as an increasing perifixtural radiopacity after 2 to 3 years in approximately 10% of implant sites.

Recently, authors have reported spontaneous osseous proliferation in the posterior region of the mandible. Burkes et al<sup>3</sup> described 9 patients in whom excessive bone growth occurred beneath the pontic of the posterior fixed prosthesis. They suggested that functional stress on bone during occlusion may be

one reason for bone growth. They also observed a high percentage of mandibular tori or buccal exostoses in patients with increased bony height. Morton and Natkin<sup>4</sup> also reported hyperostosis under fixed partial prosthesis pontics in 16 patients. They performed biopsies of the proliferated bone, and all specimens had a similar histologic appearance, which demonstrated hyperplastic lamellar bone.

A combination of both local and genetic factors may contribute to the development of these subpontic hyperostoses. Taylor<sup>7</sup> described a patient with spontaneous alveolar ridge growth beneath the cantilevers of an implant-supported fixed prosthesis. In these reports, however, no conclusions as to the possible etiology were made.

In this paper, 5 of 27 patients who showed increases in posterior bony height were reported. The mandibular molar region was the only site at which this phenomenon occurred, which corresponds to other reports in the literature. However, the reason for this occurrence remains obscure.

Functional load applied to fixed prostheses supported by osseointegrated implants causes a slight distortion in the mandible, and in every part of the mandible the stress distribution differs because of the shape of the mandible.<sup>8,9</sup> Stress distribution in

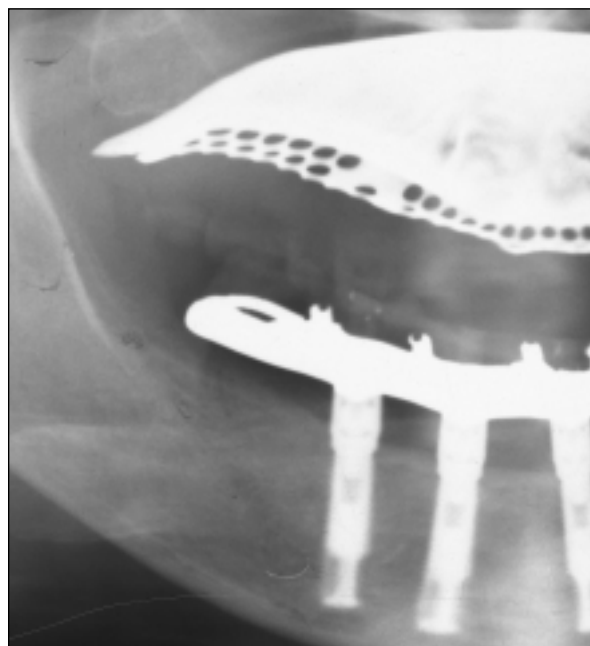
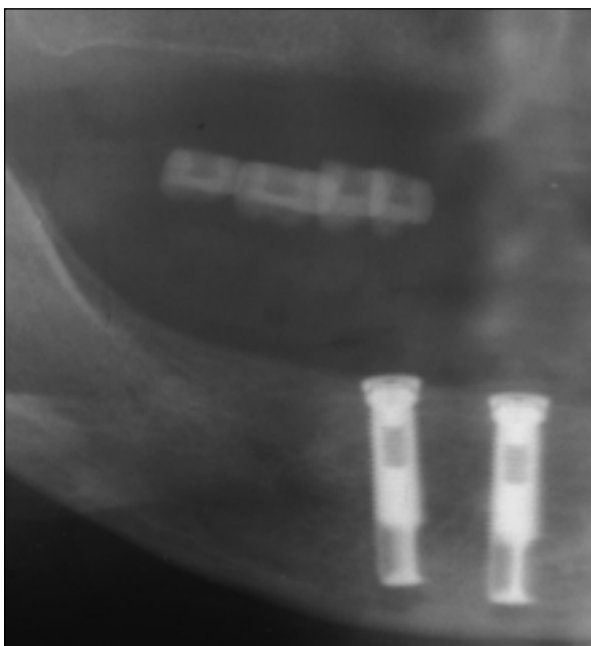
the molar region of the mandible may differ from that in the maxilla or the anterior mandible and may cause a physiologic response, producing the osseous proliferation.

In this series of patients, the amount of increase in bony height was different in each patient, as were the size and density of the resorbed mandible before

**Table 1 Ratios of Increase in the Bony Height of the Mandible**

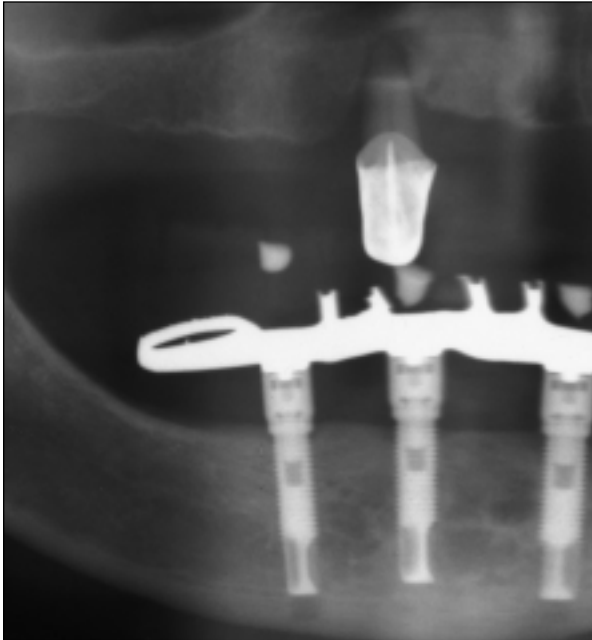
Ratio (%)	No. of patients*
$-1.0 \leq R < -0.5$	3
$-0.5 \leq R < 0.0$	3
$0.0 \leq R < 0.5$	11
$0.5 \leq R < 1.0$	5
$1.0 \leq R < 2.0$	0
$2.0 \leq R < 3.0$	0
$3.0 \leq R < 4.0$	2
$4.0 \leq R < 6.0$	1
$6.0 \leq R$	2

\*In 5 of 27 patients obvious increase of bony height was observed.

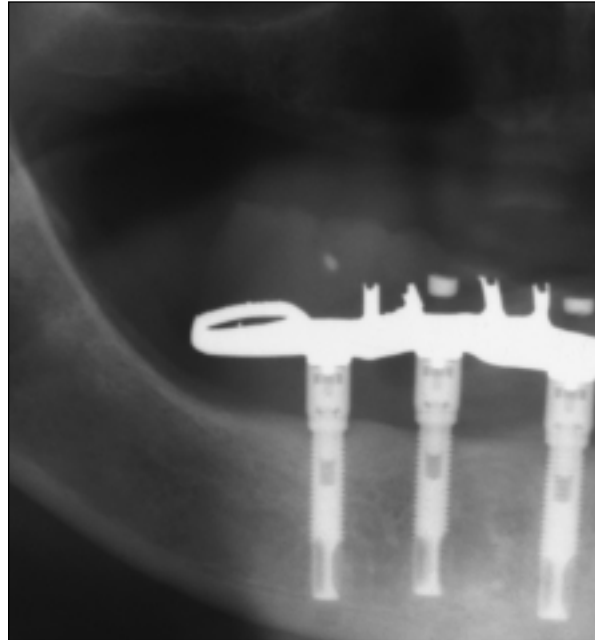


**Figs 2a and 2b** Radiographs showing the increase in the height of the bony alveolar crest in patient 1. (Left) Image obtained at the time of superstructure fabrication. (Right) Image obtained 25 months after superstructure fabrication.

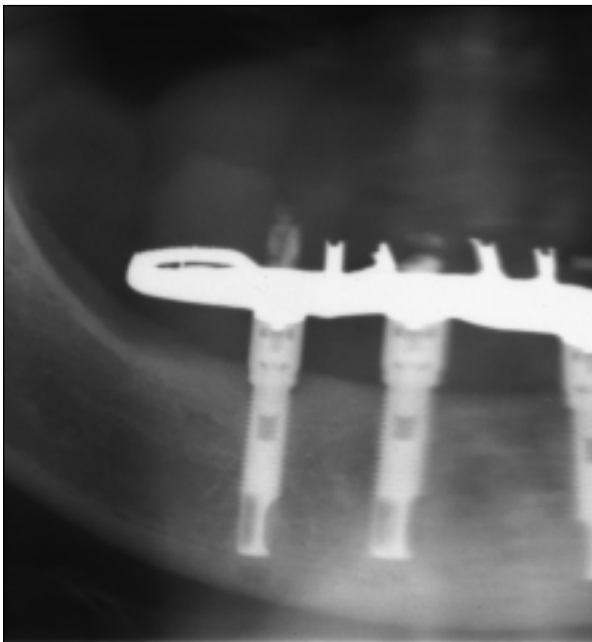
**Figs 3a to 3d** Radiographs showing the increase in the height of the bony alveolar crest in patient 3.



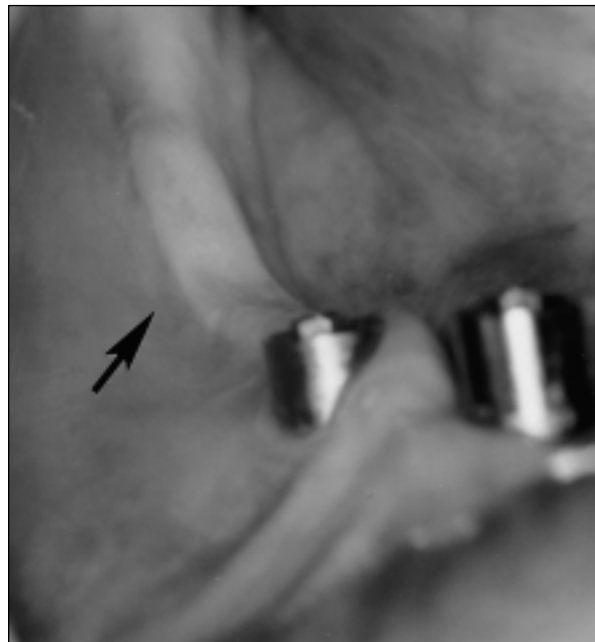
**Fig 3a** Image obtained at the time of superstructure fabrication.



**Fig 3b** Image obtained 28 months after superstructure fabrication.



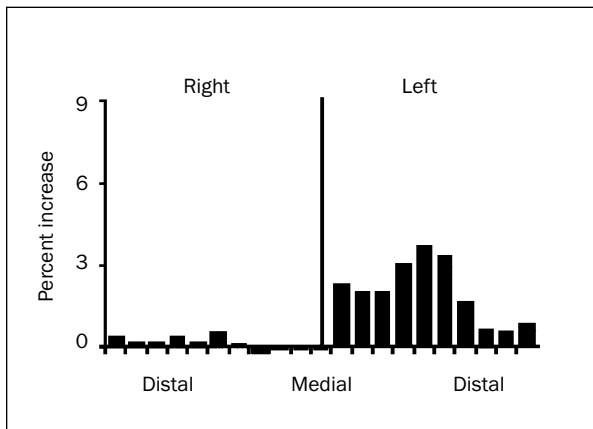
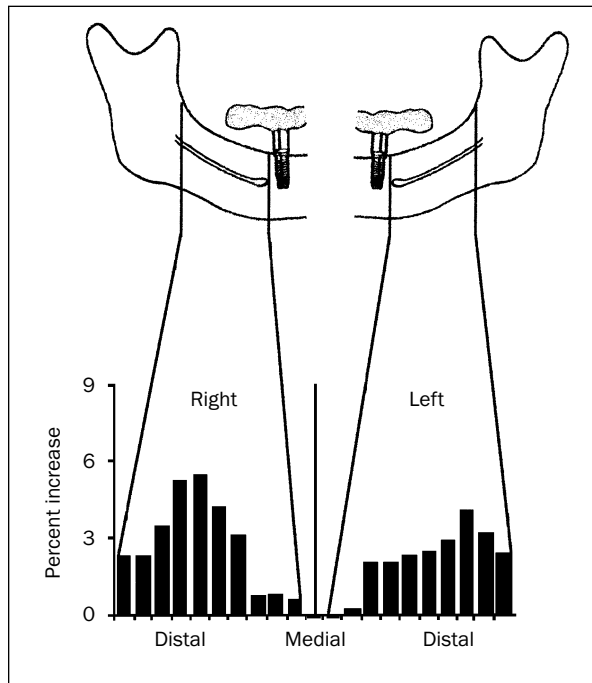
**Fig 3c** Image obtained 40 months after superstructure fabrication.



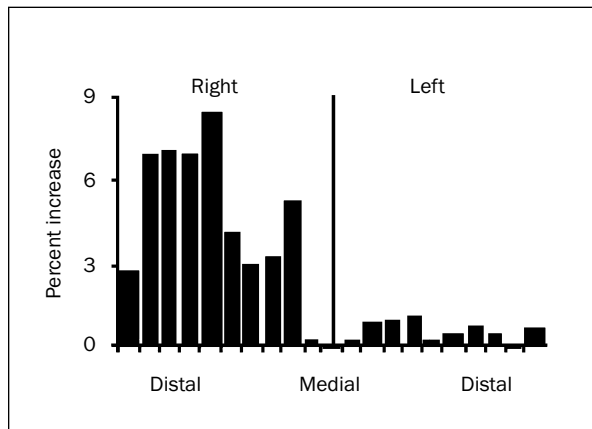
**Fig 3d** Photograph taken after retrieval of the superstructure, 40 months after superstructure fabrication. Evidence of hard contact between the superstructure and mucosa was observed (arrow).

**Figs 4a to 4e** Graphs showing the relationship between the increase in the bony height of the mandible and the points at which the bony height was measured in the 5 patients with a positive response.

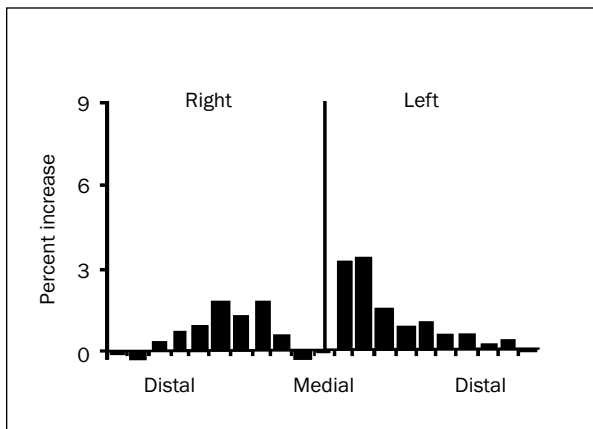
**Fig 4a** (Right) Patient 1



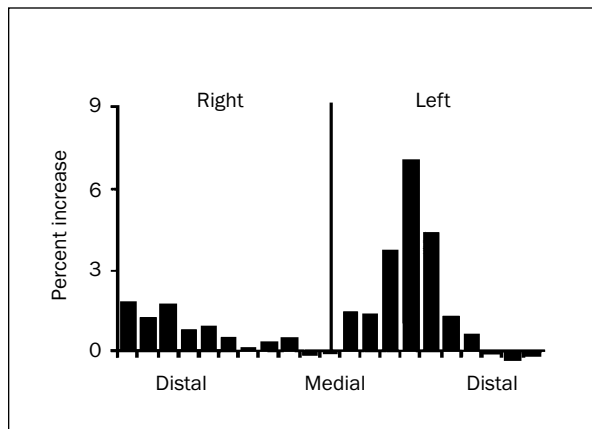
**Fig 4b** Patient 2



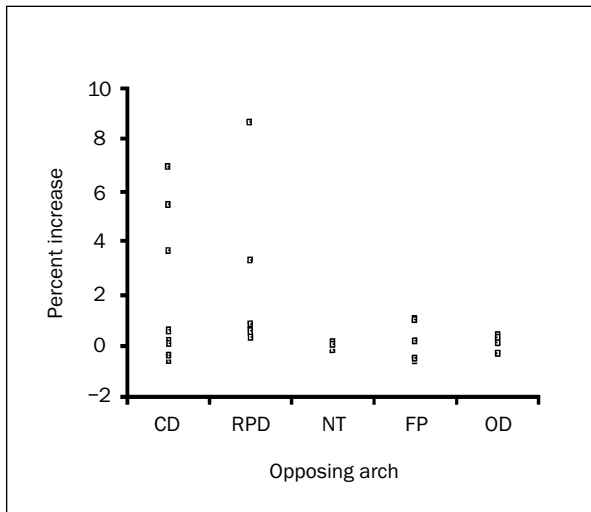
**Fig 4c** Patient 3



**Fig 4d** Patient 4



**Fig 4e** Patient 5



**Fig 5** The relationship between the ratio of the increase in bony height and the situation of the opposing arch. The 5 patients who showed an increase in bony height of more than 3% all had a conventional complete denture or removable partial denture in the opposing arch. CD = conventional complete denture; RPD = conventional removable partial denture; NT = natural teeth; FP = fixed prosthesis supported by osseointegrated implants; OD = implant-retained overdenture.

implant treatment. The presence of osseointegrated implants in the jaw allowed the patients to function at a level close to that of dentate persons.<sup>10</sup> Since the resorbed mandible must absorb the functional forces when forces are applied, there may be a minimum size and density of bone that is required to absorb the applied forces. This could explain the difference in the amount of osseous proliferation in each patient.

For any additional conclusions related to this phenomenon to be drawn, further investigation into the relationship between stress distribution in the mandible, bone size and density, and the amount and direction of functional force is required.

## REFERENCES

1. Albrektsson T. The response of bone to titanium implants. In: CRC Critical Reviews in Biocompatibility. Boca Raton: CRC Press Inc, 1985:53-54.
2. Adell R, Lekholm U, Rocker B, Brånemark P-I. A 15-year study of osseointegrated implants in the treatment of the edentulous jaw. *Int J Oral Surg* 1981;10:387-416.
3. Burkes E, Marbry D, Brooks R. Subpontic osseous proliferation. *J Prosthet Dent* 1985;53:780-785.
4. Morton TH, Natkin E. Hyperostosis and fixed partial denture pontics: Report of 16 patients and review of literature. *J Prosthet Dent* 1990;64:539-547.
5. Brånemark P-I, Bryonia U, Hansson BO, Adell R, Breine U, Lindstrom J, Olsson A. Intra-osseous anchorage of dental prosthesis. I. Experimental studies. *Scand J Plast Reconstr Surg* 1963;3:81-100.
6. Albrektsson T, Zarb GA, Worthington P, Eriksson RA. The long-term efficacy of currently used dental implants. A review and proposed criteria for success. *Int J Oral Maxillofac Implants* 1986;1:11-15.
7. Taylor TD. Osteogenesis of the mandible associated with implant reconstruction: A patient report. *Int J Oral Maxillofac Implants* 1989;4:227-231.
8. Ralph JP, Caputo AA. Analysis of stress patterns in the human mandible. *J Dent Res* 1975;54:814-821.
9. Mongini F, Calderale PM, Barberi G. Relationship between structure and stress pattern in the human mandible. *J Dent Res* 1979;58:2334-2337.
10. Carlsson G, Haraldson T. Functional response. In: Brånemark P-I, Zarb GA, Albrektsson T (eds). *Tissue-Integrated Prostheses*. Chicago: Quintessence, 1985:155-163.