

Safe Placement of Urethral Foley Catheter Using Guide Wire in Patient with False Passage

Young Soo Kim

*Department of Urology,
College of Medicine, Yeungnam University
Taegu, Korea*

Urethral catheterization with a Foley catheter is an essential procedure in most transurethral endoscopic manipulation. But sometime it can be difficult and injurious to introduce a Foley catheter through the urethral meatus with blind approach especially in patients with false passage.

Herein I describe a simple and safe method in placement of urethral Foley catheter using guide wire through the small hole at the tip of the catheter.

Material & Methods

From September 1986 to June 1988 inclusive 20 patients were hospitalized with urethral stricture that required internal urethrotomy and 71 patients were hospitalized with benign prostatic hypertrophy that required transurethral resection of the prostate.

Among patients with urethral stricture, previously established urethral false tracts were found in 3 and urethral false passage created inadvertently during internal urethrotomy procedures were found in 4 resulted in difficult Foley catheterization.

In three patients underwent transurethral resection of the prostate for benign prostatic hypertrophy, the Foley catheterizations were also difficult in ordinary way (Table 1).

Under vision using endoscopic instruments, a 0.035-inch or 0.038-inch floppy tip guide wire is passed into the bladder via instrumental channel or endoscope sheath.

After leaving a length of guide wire sufficiently within the bladder, endoscope and sheath are removed remaining the guide wire.

A small hole is then made by puncture with 17-gauge needle at the apex of the tip of Foley catheter and the stiff distal end of the guide wire is inserted through this punctured hole (Fig. 1).

19.5-gauge or 21-gauge Cut-Biopsy-Needle (E-Z-EM, Inc.) is better for making this small hole with its outer needle. Application of a small amount of lubricant over the guide wire may facilitate this penetration.

The Foley catheter is then introduced over the guide wire into the bladder. After inflating balloon the guide wire is withdrawn.

Results

We initially performed this guide wire technique of urethral Foley catheterization in 3 patients with urethral false tract established previously. In 4 patients with urethral false passage created during internal urethrotomy procedure and in 3 patients

Table 1. Etiologic classification of patients with difficult Foley catheterization

Diseases	Op. procedures	No. of Pts.
Urethral stricture	Internal urethrotomy	7
false tract, established previously		3
false tract, created during procedure		4
Benign prostatic hypertrophy	TURP	3
Total		10

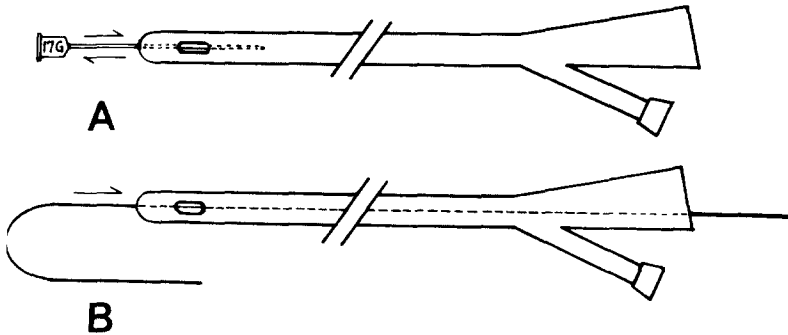


Fig. 1. (A) A puncture is made at the apex in the tip of Foley catheter using 17-gauge needle or 19.5-gauge or 21-gauge Cut-Biopsy-Needle(E-Z-EM, Inc.).
 (B) Stiff distal end of guide wire is inserted through punctured hole.

underwent transurethral resection of the prostate for benign prostatic hyperplasia, above technique for catheterization was performed following failure of ordinary way.

We could have safe and successful placement of urethral Foley catheter with this technique in all 10 cases without any difficulty or complication.

Discussion

During the course of treatment of a urethral stricture by the passage of instruments, one may well pass outside the lumen of the urethra, and as the surrounding tissue has little resistance to this trauma, a false passage may be created. Any instrument subsequently passed into the urethra may find its way into this tract, and this new tract may become epithelialized and persist.¹

in the presence of this false passage, it is preferable to use guide wire approach for safe placement of urethral Foley catheter and one may use Council tip Foley catheter or ordinary Foley catheter by making a end-hole with hole punch.²

But Council tip Foley catheter or hole punch may not be available at hand and also it is usually difficult to make an end-hole with hole punch especially for small-diameter Foley catheter.

Placement of Foley catheter through perineal urethrotomy using guide wire was previously described by Senoh.³ He had successfully placed a Foley catheter with the tip cut off obliquely through the perineal incision for temporary urinary drainage in hypospadias repair.

But in patient with false passage or injured urethra, maintaining of a round tip of the Foley catheter is preferable so as to pass smoothly

through the whole urethra for safe placement of a urethral Foley catheter. And there also is possibility of damaging the balloon or decreasing the stiffness of the tip of Foley catheter by cutting it off obliquely.

By using our method, the original shape of the tip of Foley catheter can be saved completely thus the Foley catheter can be introduced safely into the bladder through the urethral meatus.

We have used this method successfully in all 10 patients and it could be thought that this method may also be applicable for (1) placement of Foley catheter as a nephrostomy tube or as a suprapubic cystostomy tube, percutaneously with aid of dilators or through the established tract and (2) placement of urethral Foley catheter for irrigation after transurethral resection of the prostate, especially when it is desirable for less injury or when it is difficult to introduce.

Summary

A simple and safe method of urethral Foley

catheterization using guide wire was devised and applied to 7 patients with urethral false tract and 3 patients underwent transurethral resection of the prostate for benign prostatic hypertrophy with success in all without difficulties.

REFERENCES

1. Devine, C. J. Jr. : Surgery of the urethra, in Walsh, P. C., Gittes, R. F., Perlmutter, A. D. and Stamey, T. A.(Eds.): *Campbell's Urology*, 5th ed. W. B. Saunders Co., Philadelphia, vol. 3, 1986, p. 2863.
2. Lange, P. H. : Diagnostic and therapeutic urologic instrumentation, in Walsh, P. C., Gittes, R. F., Perlmutter, A. D. and Stamey, T. A.(Eds.): *Campbell's Urology*, 5th ed., W. B. Saunders Co., Philadelphia, vol. 1, 1986, p. 511.
3. Senoh, K. : Placement of Foley catheter for perineal urethrostomy by Seldinger technique, *Urology*, 25 : 78-79, 1985.

Urethral False Tract가 있는 환자에 있어서 Guide Wire를 이용한 안전한 Foley Catheter의 유치방법

영남대학교 의과대학 비뇨기과학교실

김 영 수

외요도구를 통한 Foley catheter의 유치는 거의 대부분의 경뇨도적 내시경 수술 후 필수적으로 행하는 술기이다. 그러나 가끔, 특히 심한 요도손상을 입힌 경우나 요도에 false tract가 생긴 때에는 동상의 방법으로 Foley catheter의 외요도구를 통한 방광내로의 유치가 곤란하며 또한 심한 손상을 초래할 위험이 많다.

저자는 guide wire를 이용한 새롭고 안전한 요도 catheter의 유치방법을 고안하여 1986년 9월부터 1988년 6월 까지 요도협착으로 입원하여 internal urethrotomy를 받은 후 Foley catheter의 유치가 곤란하였던 7명의 환자 및 경뇨도전립선절제술후 Foley catheter의 삽입이 곤란하였던 3명의 환자에게 각각 시행하여 전례에서 성공하였다.