

Protracted Benign Paroxysmal Positional Vertigo Following Osteotome Sinus Floor Elevation: A Case Report

George Nan-Chang Su, DDS, PhD¹/Pei-Wei Tai, DDS, MS²/Po-Tsang Su, MD³/Hua-Hong Chien, DDS, PhD⁴

Benign paroxysmal positional vertigo (BPPV) is a relatively rare condition characterized by onset of rotation dizziness triggered by head movements or change in posture. BPPV etiology includes head injury, infection, vascular disorders, surgical trauma, and idiopathic events. This report presents a case of protracted BPPV following osteotome sinus floor elevation and simultaneous implant placement. A 49-year-old female suffered intense vertigo and nausea immediately after implant placement using an osteotome sinus floor elevation procedure, especially when changing head position while sitting upright. Despite antivertigo medications, the condition did not improve. Following referral to a neurotologist, BPPV contralateral to the operation site was diagnosed 14 days after the osteotome sinus floor elevation procedure. The Epley's maneuver was then applied and, gradually, symptoms of BPPV disappeared 3 months after the implant surgery. No recurrence of BPPV was observed during further 3-month follow-up. Prevention and management of osteotome sinus floor elevation-related BPPV are reviewed in this report. INT J ORAL MAXILLOFAC IMPLANTS 2008;23:955-959

Key words: benign paroxysmal positional vertigo, canalith repositioning procedure, dental implantation, osteotome sinus floor elevation

Benign paroxysmal positional vertigo (BPPV) is considered the most common peripheral vestibular disorder and is characterized by onset of rotation dizziness triggered by head movements or change in posture.¹ The clinical syndrome of BPPV includes rotatory vertigo, postural imbalance, and nausea,

which are provoked by (1) sitting up from a supine position, (2) first lying down in bed, (3) turning over in bed from one side to the other, (4) extending the head to look up above, and (5) flexing the neck.² The manifestation of BPPV in post-traumatic cases was first described by Adler³ in 1897 and fully defined by Dix and Hallpike in 1952.⁴ The etiology of BPPV includes head injury, infection, vascular disorders, surgical trauma, and idiopathic events.⁵ The incidence of BPPV was reported to be 0.01% in Japan,⁶ 0.06% in the United States,⁷ and 0.6% in Germany.⁸ The most common age of onset was found to be at 60 to 70 years,⁹ and women are more frequently affected than men in the idiopathic group by a ratio greater than 2 to 1.¹⁰ The pathophysiologic mechanism of BPPV is commonly accepted; the endolymph system of posterior or lateral semicircular canals is disturbed by free-floating otoliths, which detach from the utricle or saccule and are dislocated into the semicircular canals.¹¹ The gravity-sensitive endolymph system is then altered by the otoliths

¹Assistant Professor, School of Dental Hygiene, China Medical University, Taichung, Taiwan.

²Lecturer, Department of Periodontics, China Medical University Hospital, Taichung, Taiwan.

³Private Practice, Tainan, Taiwan.

⁴Formerly Associate Professor, School of Dentistry, China Medical University, Taichung, Taiwan; presently Clinical Associate Professor, Section of Periodontology, College of Dentistry, The Ohio State University, Columbus, Ohio.

Correspondence to: Dr Hua Hong Chien, Section of Periodontology, College of Dentistry, The Ohio State University, 305 West 12th Avenue Room 4103, Columbus, OH 43210. Fax: +614 292 4612. E-mail: chien.60@osu.edu

and causes abnormal firing of the hairy cells. The vestibular function of the inner ear is generally evaluated via the examination of nystagmus, an involuntary, speedy, rhythmic movement of the eyeball.¹² Two types of tests are used: spontaneous and induced nystagmus. Spontaneous nystagmus is usually observed in patients with a central vestibular disorder. Induced nystagmus may include static and dynamic nystagmus, usually referred to as positional and positioning nystagmus, respectively.¹³ The method used to assess positioning nystagmus is also called the Dix-Hallpike test.⁴ The diagnosis of BPPV is easily made by the Dix-Hallpike test, which provokes vertigo and nystagmus after the patient is rapidly moved from a sitting to a head-hanging position. Furthermore, the Dix-Hallpike maneuver may help differentiate BPPV from other vertiginous disorders, with positive and negative predictive values of 83% and 52%, respectively.^{14,15} Treatment of BPPV by canalith repositioning procedure (CRP) has been shown to be the most effective and noninvasive way to manage the condition.¹⁶ The CRP, also known as particle repositioning procedure or Epley's maneuver, was first described by Epley in 1992.¹⁷ The goal of the maneuver is to move the free-floating debris out of the semicircular canals to avoid sending false signals to the brain about spatial movement. This procedure can be conducted in the doctor's office and consists of a series of guided head movements, without need for any instruments. It has been demonstrated in various randomized clinical trials to have a success rate of 50% to 90%,^{18–20} but recurrence may be about 15% during the first year, 20% at 20 months, and 37% at 60 months.²¹

Implant placement in the posterior maxilla poses a great challenge to the clinician due to limited bone height beneath the sinus floor. Currently, the lateral window approach, first published in 1980 by Boyne and James,²² is the most commonly used technique to assess the sinus floor. A less invasive procedure, namely the osteotome sinus floor elevation (OSFE) developed by Summers,²³ is generally used in less severely resorbed maxillae to graft the maxillary sinus in combination with immediate implant placement.

BPPV has been reported as a postoperative complication following OSFE.^{24–27} Unlike the high incidence of laceration of the schneiderian membrane, which varies from 10% to 33% depending on the height of the elevation,²⁸ the incidence of OSFE-related BPPV is less than 3% (4 in 146 patients²⁵). OSFE-related BPPV commonly resolves within a month without treatment.^{24–27} An unusual case of protracted BPPV in a middle-aged woman caused by head trauma during implant placement performed with the use of osteotomes is reported in this article.

CASE REPORT

A 49-year-old Chinese woman went to the periodontology clinic of the China Medical University Hospital for implant placement in the edentulous region of the maxillary right first molar. The patient was in good physical health with no history of sinus disease. Her noncontributory medical history included total abdominal hysterectomy and bilateral salpingo-oophorectomy 2 years prior, due to uterine myoma. She was taking no medications and denied any allergies. The maxillary right first molar had been extracted due to caries approximately 1 year prior to presentation. Panoramic, tomographic, and periapical radiographs (Fig 1) were taken for evaluation of the maxillary sinus area. Since radiographic evaluation revealed bone height between ridge crest and sinus floor greater than 6 mm, the bone-added OSFE procedure with simultaneous implant placement was chosen. The patient was draped and prepped in routine aseptic manner. Surgery was performed under local anesthesia (~6 mL of 2% mepivacaine with 1:100,000 epinephrine; Scandonest 2%, Septodont, Cedex, France). A linear crestal incision was made at the maxillary right first molar edentulous area, with intrasulcular incisions placed around the maxillary right second premolar and molar. Full-thickness flaps were raised buccally and palatally. The osteotomy was initiated with a round bur to penetrate the cortical bone, followed by a 2-mm twist drill drilling to 1 mm short of the sinus floor. The cortical plate of the sinus floor was fractured for the bone-added OSFE procedure using a mallet and increasingly wider offset osteotomes. Demineralized freeze-dried bone allograft (Dembone; Pacific Coast Tissue Bank, Los Angeles, CA) was intermittently added to the implant osteotomy site during the sinus lifting procedure. A 5 × 10-mm implant (Brånemark System; Mk III, TiU WP; Nobel Biocare, Göteborg, Sweden) was then placed in the osteotomy site. A 6 × 4-mm healing abutment (Brånemark System WP) was screwed onto the implant, and a periapical radiograph was obtained to verify the tight connection between the abutment and implant (Fig 2). The soft tissue was closed using a 4-0 expanded polytetrafluoroethylene (Gore-Tex) suture with an interrupted suturing technique. The surgery lasted 50 minutes. After the operation, the patient suffered intense vertigo and nausea when sitting upright and difficulty ambulating. She sat on the dental chair and rested for 30 minutes, but vertigo still affected her, especially when she changed her head position.

For treatment of the postoperative vertigo, the patient was referred to an otolaryngologist the next day, when a pure tone audiometry and tympanome-

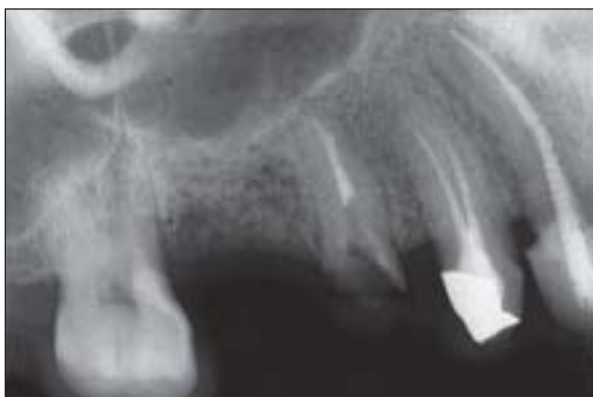

Fig 1 A preoperative periapical radiograph of the patient shows sufficient bone height for the OSFE procedure and immediate implant placement in the area of the maxillary right first molar.

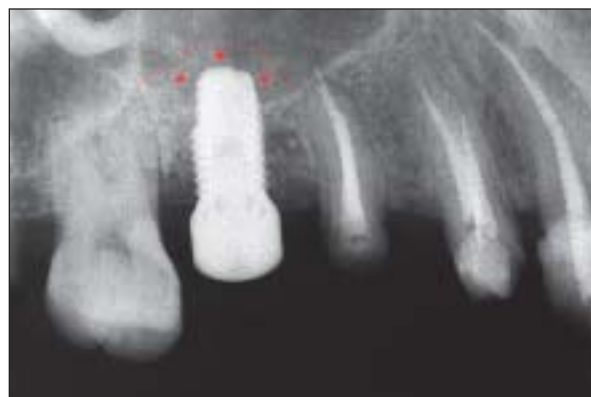

Fig 2 An immediate postoperative radiograph shows evidence of condensed bone around the implant and a light radiopacity indicative of the demineralized bone allograft (asterisks) placed at the apex of the implant. The dotted line indicates the displacement of the sinus floor.

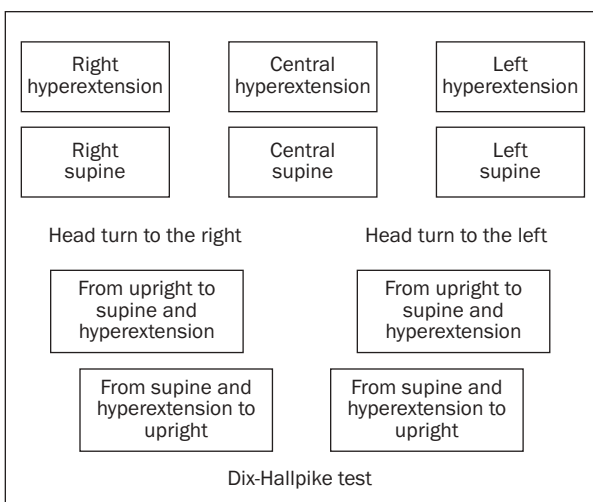


Fig 3 The examination maneuvers of induced nystagmus, including positional (upper half) and positioning (lower half) nystagmus.

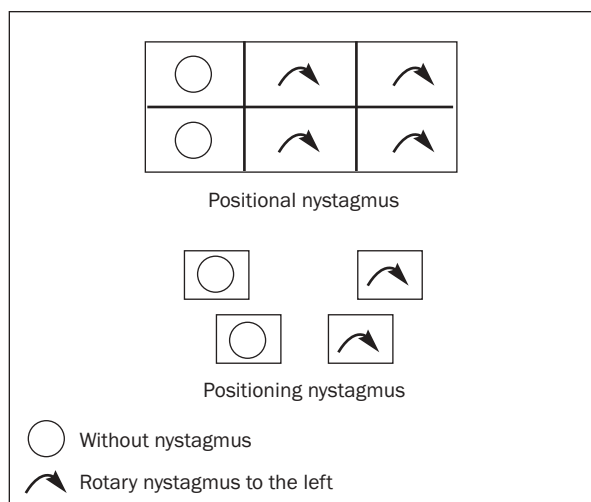


Fig 4 Nystagmogram of the left eye of the patient. The examination for induced nystagmus revealed rotatory nystagmus with a leftward fast component in her left eye.

try were performed without abnormal findings. Therefore, antivertigo drugs (diphenidol and flunarizine) were prescribed along with estazolam to help her sleep. Nonetheless, the vertigo continued and the patient sought the services of a neurologist. At that time, a carotid phonoangiography and transcranial Doppler sonography were carried out, and no pathological findings were found. She was then referred to a neurotologist for further examination. A vestibular function test was performed by examining the patient for spontaneous and induced nystagmus. Spontaneous nystagmus was not observed, whether the eyes gazed straight or moved in 4 directions (upward, downward, left, right). For examination of positional nystagmus, the patient is first lying down and with the head placed supine. The arising of nys-

tagmus is observed for 30 seconds. The head is then turned slowly to the left and the patient observed for nystagmus for another 30 seconds. All 6 head positions (Fig 3 upper half) are examined in the same manner. To assess for positioning nystagmus, the patient's head is first turned 45 degrees to the right and then brought into the supine position with the head hyperextended. After 30 seconds, the patient is returned to the upright position, with the head turned 45 degrees to the right. The same procedure is then repeated on the left side (Fig 3 lower half). The examination for induced nystagmus, either positional or positioning (Fig 4), revealed rotatory nystagmus with a leftward fast component in the patient's left eye. This indicates that BPPV originated from her left vestibular system. BPPV to the left inner ear was

then diagnosed, and Epley's maneuver (CRP) was applied to the left inner ear. Vertigo improved after CRP and completely disappeared 3 months after the implant surgery. Recurrence was not observed after further follow-up for 3 more months.

The patient had denied any head trauma history prior to the implant surgery, but upon further questioning after the procedure she related that she had suffered from vertigo 3 times within the last 10 years, with nausea and headache being her chief complaints. Vestibular function tests had also been conducted at the time, but did not show any obvious nystagmus.

DISCUSSION

The case of a 49-year-old woman, who following OSFE suffered protracted BPPV that originated from the side contralateral to the operation site, was presented in this report. BPPV may arise from blunt head trauma caused by the transmission of the percussive forces on the upper maxilla during the OSFE procedure. The percussive force may detach otoliths from the utricle or saccule of the vestibular system in the inner ear, while hyperextension of the patient's head may facilitate displacement of the detached otoliths into the posterior semicircular canal. The posteriorly displaced otoliths may then induce BPPV. However, cases of non-OSFE-related lateral or anterior semicircular canal BPPV² and a case of rhinoplasty-related BPPV without hyperextended head position²⁹ have also been reported. Whether both percussion and hyperextended head position are essential for the emergence of OSFE-related BPPV is unknown.

An extensive review of the patient's medical history was performed after the BPPV occurrence, and revealed multiple episodes of vertigo without induced nystagmus. Whether a patient with a past history of vertigo might be more susceptible to BPPV following OSFE procedure is unknown, and such an association had not until now been described. This may be due to the scarcity of OSFE-related BPPV cases. The presently reported case and previous reports²⁴⁻²⁷ indicate that BPPV, although rare, does occur following OSFE. Based on the limited information available, the following steps are suggested as means to prevent and manage OSFE-related BPPV. First, screening out patients with a past history of vertigo may diminish the possibility of OSFE-induced BPPV; in such cases, a lateral window approach should be considered instead of OSFE. Second, avoid prolonged hyperextended head positioning during OSFE procedures. Third, early diagnosis of BPPV and immediate application of Epley's maneuver may help avoid protracted BPPV.

ACKNOWLEDGMENTS

The authors thank Dr Dimitris Tatakis, Section of Periodontology, College of Dentistry, The Ohio State University Health Sciences Center, for his assistance in the preparation of this manuscript.

REFERENCES

1. Furman J, Cass SP. Benign paroxysmal positional vertigo. *N Engl J Med* 1999;341:1590-1596.
2. Brandt T. Benign paroxysmal positioning vertigo. In: Brandt T (ed). *Vertigo: Its Multisensory Syndromes*. London: Springer-Verlag, 1999:251-283.
3. Adler A. Ueber den "einseitigen Drehschwindel." *Dtsch Z Nervenheilk* 1897;11:358-375.
4. Dix R, Hallpike CS. The pathology, symptomatology and diagnosis of certain common disorders of the vestibular system. *Proc Roy Soc Med* 1952;45:341-354.
5. Baloh RW, Jacobson K, Honrubia V. Horizontal semicircular canal variant of benign positional vertigo. *Neurology* 1993; 43:2542-2549.
6. Mizukoshi K, Watanabe Y, Shojaku H, Okubo J, Watanabe I. Epidemiological studies on benign paroxysmal positional vertigo in Japan. *Acta Otolaryngol* 1988;447(suppl):67-72.
7. Froehling DA, Silverstein MD, Mohr DN, Beatty CW, Offord KP, Ballard DJ. Benign positional vertigo: Incidence and prognosis in a population-based study in Olmsted County, Minnesota. *Mayo Clin Proc* 1991;66:596-601.
8. von Brevern M, Radtke A, Lezius F, et al. Epidemiology of benign paroxysmal positional vertigo: A population based study. *J Neurol Neurosurg Psychiatry* 2007;78:710-715.
9. Hilton M, Pinder D. Benign paroxysmal positional vertigo. *BMJ* 2003;326:673.
10. Katsarkas A. Benign paroxysmal positional vertigo (BPPV): Idiopathic versus post-traumatic. *Acta Otolaryngol* 1999;119: 745-749.
11. Hall SF, Ruby RR, McClure JA. The mechanics of benign paroxysmal vertigo. *J Otolaryngol* 1979;8:151-158.
12. Vitte E, Semont A. Assessment of vestibular function by video-nystagmoscopy. *J Vestib Res* 1995;5:377-383.
13. Barber HO, Stockwell CW. *Manual of electronystagmography*. St Louis: C V Mosby, 1980:142-152.
14. Hanley K, O'Dowd T. Symptoms of vertigo in general practice: A prospective study of diagnosis. *Br J Gen Pract* 2002;52: 809-812.
15. Hoffman RM, Einstadter D, Kroenke K. Evaluating dizziness. *Am J Med* 1999;107:468-478.
16. Li JC, Li CJ, Epley J, Weinberg L. Cost-effective management of benign positional vertigo using canalith repositioning. *Otolaryngol Head Neck Surg* 2000;122:334-339.
17. Epley JM. The canalith repositioning procedure: For treatment of benign paroxysmal positional vertigo. *Otolaryngol Head Neck Surg* 1992;107:399-404.
18. Lynn S, Pool A, Rose D, Brey R, Suman V. Randomized trial of the canalith repositioning procedure. *Otolaryngol Head Neck Surg* 1995;113:712-720.
19. Froehling DA, Bowen JM, Mohr DN, et al. The canalith repositioning procedure for the treatment of benign paroxysmal positional vertigo: A randomized controlled trial. *Mayo Clin Proc* 2000;75:695-700.
20. Hilton M, Pinder D. The Epley (canalith repositioning) manoeuvre for benign paroxysmal positional vertigo. *Cochrane Database Syst Rev* 2004; 2:CD003162.

21. Swartz R, Longwell P. Treatment of vertigo. *Am Fam Physician* 2005;71:1115–1122.
22. Boyne PJ, James RA. Grafting of the maxillary sinus floor with autogenous marrow and bone. *J Oral Surg* 1980;38:613–616.
23. Summers RB. The osteotome technique: Part 3—Less invasive methods of elevating the sinus floor. *Compendium* 1994;15:698–704.
24. Peñarrocha M, Pérez H, García A, Guarinos J. Benign paroxysmal positional vertigo as a complication of osteotome expansion of the maxillary alveolar ridge. *J Oral Maxillofac Surg* 2001;59:106–107.
25. Di Girolamo M, Napolitano B, Arullani CA, Bruno E, Di Girolamo S. Paroxysmal positional vertigo as a complication of osteotome sinus floor elevation. *Eur Arch Otorhinolaryngol* 2005;262:631–633.
26. Saker M, Ogle O. Benign paroxysmal positional vertigo subsequent to sinus lift via closed technique. *J Oral Maxillofac Surg* 2005;63:1385–1387.
27. Kaplan DM, Attal U, Kraus M. Bilateral benign paroxysmal positional vertigo following a tooth implantation. *J Laryngol Otol* 2003;117:312–313.
28. Reiser GM, Rabinovitz Z, Bruno J, Damoulis PD, Griffin TJ. Evaluation of maxillary sinus membrane response following elevation with the crestal osteotome technique in human cadavers. *Int J Oral Maxillofac Implants* 2001;16:833–840.
29. Persichetti P, Di Lella F, Simone P, et al. Benign paroxysmal positional vertigo: An unusual complication of rhinoplasty. *Plast Reconstr Surg* 2004;114:277–278.