

# Piezoelectric and Conventional Osteotomy in Alveolar Distraction Osteogenesis in a Series of 17 Patients

Alberto González-García, DDS<sup>1</sup>/Márcio Diniz-Freitas, DDS, PhD<sup>1</sup>/  
Manuel Somoza-Martín, DDS, PhD<sup>1</sup>/Abel García-García, MD, PhD<sup>2</sup>

*Piezoelectric osteotomy is based on ultrasonic vibration of an osteotomic device that permits precise cutting of bone structures without cutting adjacent soft tissues. To date, however, there have been no studies of the outcome and complications of alveolar distraction for piezoelectric osteotomy versus conventional osteotomy. The present study evaluated piezoelectric versus conventional osteotomy in alveolar distraction. **Materials and Methods:** A retrospective study was performed on all patients of the authors who requested dental implants and who after preliminary evaluation were judged to require alveolar distraction osteogenesis for rehabilitation of edentulous mandibular regions. The distraction was performed using the same distraction system in all cases, but with the osteotomy performed either by conventional techniques using rotary instruments and chisels (conventional osteotomy group, n = 11), or by piezoelectric osteotomy using the Piezosurgery system (Mectron Medical Technology; Carasco, Genoa, Italy; n = 6). The 17 distractions were compared with respect to patient age, patient sex, intra- and postoperative complications, degree of surgical difficulty, postdistraction morphology of the alveolar ridge, and rehabilitation success rate. **Results:** Both surgical difficulty (as measured by the number of surgical instruments required) and the incidence of intraoperative complications were significantly lower in the piezoelectric osteotomy group than in the conventional osteotomy group. However, postdistraction morphology of the alveolar ridge (as determined at implant placement) was worse in the piezoelectric osteotomy group than in the conventional osteotomy group (P = .072). The overall rehabilitation success rate was 100% in the conventional osteotomy group versus only 66.7% (4 of 6 cases) in the piezoelectric osteotomy group. **Conclusions:** The use of piezoelectric osteotomy in alveolar distraction appears to simplify surgery and reduce the incidence of intraoperative complications. However, results also suggest that piezoelectric osteotomy increases the risk of postoperative and postdistraction complications and reduces the overall rehabilitation success rate. INT J ORAL MAXILLOFAC IMPLANTS 2008;23:891–896.*

**Key words:** bone surgery, distraction osteogenesis, piezoelectric surgery

**P**iezoelectric bone surgery is a family of ultrasonic bone surgery techniques that constitute an important alternative to conventional bone surgery

techniques, particularly in surgical contexts in which there is a risk of compromise of adjacent soft tissues. Piezoelectric osteotomy devices are based on modulated ultrasonic vibration of an active tip (called the insert) and are characterized by 3 essential features: (a) precise cutting due to vibration of the insert with an amplitude of only 60 to 200  $\mu\text{m}$  horizontally and 20 to 60  $\mu\text{m}$  vertically; (b) selective cutting, since the vibration frequency (22 to 30 kHz) cuts only mineralized tissue, not soft tissues; and (c) a relatively blood-free surgical field, due to the air-water cavitation effect of the device.<sup>1</sup> As a result of these characteristics, piezoelectric osteotomes appear to offer precise, safe, and clean cutting of bone structures, maintaining the integrity of adjacent soft tissues.<sup>2</sup>

<sup>1</sup>Assistant Professor, Oral Surgery and Oral Medicine Departments, School of Dentistry, University of Santiago de Compostela, Spain.

<sup>2</sup>Head of Section, Department of Maxillofacial Surgery, Clinical University Hospital, University of Santiago de Compostela, Spain.

**Correspondence to:** Dr Alberto González-García, Facultad de Medicina y Odontología, Calle Entrerriós S/N, 15782. Santiago de Compostela, Spain. Fax: +34 981 56 22 26. E-mail: gonzalezgarcia@gmail.com

Alveolar distraction osteogenesis is widely used to increase alveolar ridge height in patients requiring dental implants who have insufficient ridge height to ensure an adequate crown-to-implant length ratio.<sup>3,4</sup> Distraction osteogenesis is based on the gradual separation from the basal bone of a detached bone segment (the transport segment) that nevertheless remains fully vascularized via its periosteum; between the basal bone and the transport segment a distraction callus forms, which gradually converts to mature bone.<sup>5</sup> In a previous study, the present investigators described the application of piezoelectric osteotomy techniques for freeing the transport segment in alveolar distraction osteogenesis.<sup>2</sup> To date, however, there have been no studies comparing the complications and outcome of alveolar distraction osteogenesis using piezoelectric and conventional osteotomy techniques. In the present study, the outcomes of alveolar distraction osteogenesis performed using the 2 techniques were compared.

## MATERIALS AND METHODS

### Sample Selection

All patients of the authors who requested dental implants and who, after preliminary evaluation, were judged to require alveolar distraction osteogenesis for rehabilitation of edentulous mandibular regions were selected. Distraction was judged necessary when required crown height was greater than the ridge height available for implantation.<sup>4</sup> All cases included in the present study were vertical distractions in posterior mandibular regions using a semirigid intraosseous distractor (LEAD System; Leibinger, Kalamazoo, MI); distractions in the anteroinferior mandible or maxilla, horizontal distractions, and distractions with other types of distractors (notably rigid juxtaosseous distractors) were excluded. When alveolar distraction was performed bilaterally, only 1 side was included by random selection.

### Surgical Procedure

Patients underwent distraction osteogenesis by the procedure of Chin,<sup>6</sup> with modifications as described by García-García et al.<sup>4</sup> Surgery was performed under local anesthesia. A crestal incision was made along the length of the alveolar process, and a mucoperiosteal flap was raised. The connection of the lingual mucoperiosteum to the transport segment was maintained. The transport segment was cut as an inverted trapezium divergent crestally, so as not to compromise mobility during distraction.

Until 2002, conventional osteotomy techniques were used exclusively by the authors (ie, techniques

using burs, other rotary instruments, and chisels). In 2002, a piezoelectric osteotomy apparatus was introduced (Piezosurgery; Mectron Medical Technology, Carasco, Genoa, Italy).

For the present study, the distraction interventions were divided into 2 groups depending on the technique used for osteotomy: a conventional osteotomy (CO) group and a piezoelectric osteotomy (PO) group. Apart from the osteotomy technique, all other procedures were the same in the 2 groups.

The Piezosurgery system comprises a central unit with a control panel, a control pedal, and the piezoelectric handpiece bearing the insert, which vibrates at between 25 and 30 kHz as required. It incorporates a system for cooling by irrigation of up to 60 mL/min of sterile cooling solution. It is supplied with a range of inserts with different shapes and surface characteristics suitable for different types of surgery; for osteotomy, OT inserts are used. Insert OT6 of the Piezosurgery system was used in the present study. Basal power is 5 W, increasable to 16 W. Horizontal vibration amplitude ranges from 60 to 200  $\mu\text{m}$ .

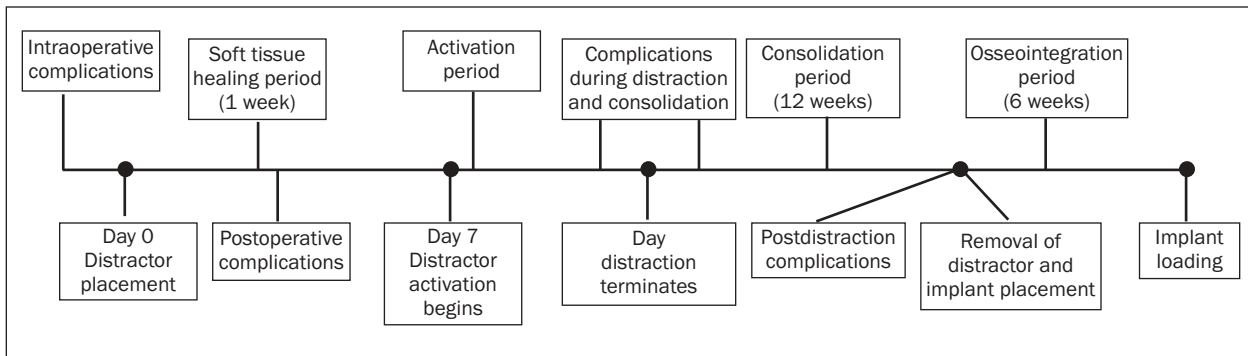
The distractor (base plate, transport plate, and distraction screw; LEAD System) was placed in accordance with the procedure described by Chin.<sup>6</sup> The transport segment was raised to a height of 5 mm to ensure adequate mobility in the required direction of distraction. It was then relocated to its starting position.

Distraction commenced 7 days after surgery and proceeded at 0.5 mm every 12 hours, until the required height had been achieved. Twelve weeks later the distractor was removed and the implants were placed. The implants were loaded 6 weeks after placement.

### Data Collection and Analysis

The following information was collected for each distraction:

1. Patient age, sex, and smoking status.
2. The type and number of distractor screws required for each rehabilitation.
3. Degree of surgical difficulty, evaluated on the basis of the number of the instruments used.
4. Intraoperative, postoperative, distraction/consolidation and postdistraction complications attributable to the difference in osteotomy technique (Fig 1). Intraoperative complications were fracture of the transport segment and difficulty in completion of the osteotomy. Postoperative complications included dysesthesia of the mental nerve. Distraction/consolidation complications were perforation of the mucosa by the transport segment and deviation of the direction of distraction. Postdistraction complications, recorded at implant



**Fig 1** Schematic representation of rehabilitation protocols involving alveolar distraction to increase crown-to-implant length ratio, showing the different types of complications that can arise.

placement, were dehiscence and fenestration defects and need for guided bone regeneration at this stage.

5. Morphology of the alveolar ridge at implant placement, as regards suitability for implant placement, following the classification of García-García et al.<sup>7</sup>
6. Overall rehabilitation success (ie, successful distraction, implant placement, and eventual rehabilitation).

### Statistical Analysis

Data were analyzed with the aid of the statistics package SPSS 10.0 for Windows (SPSS, Chicago, IL). Correlation between categorical variables was assessed by Fisher exact tests.  $P < .05$  indicated statistical significance. In the text, means are cited  $\pm$  standard deviations.

## RESULTS

The study included a total of 17 vertical alveolar distractions in the posterior mandibular (7 on the right side, 10 on the left). Of the 17 distractions, 11 were performed using conventional techniques for osteotomy (CO group), while the remaining 6 were performed using piezoelectric osteotomy (PO group).

Mean age for the entire sample was  $47.3 \pm 8.1$  years ( $n = 17$ ):  $45.4 \pm 7.6$  years in the CO group ( $n = 11$ ) versus  $52.2 \pm 7.9$  years in the PO group ( $n = 6$ ).

The entire sample was 31.8% men and 68.2% women, with 31.3% men and 68.8% women in the CO group and 33.3% men and 66.7% women in the PO group.

Only 2 women (2 distractions; 11.8%) reported smoking; both of these distractions were in the conventional osteotomy group.

The number of distractor screws used was 1 in 70.6% of distractions and 2 in the remaining 29.4% (because the segment was unusually long or because of a need for nonuniform distraction).<sup>8</sup> The number of screws required was similar in the 2 groups: only 1 screw was required in 72.7% of distractions in the CO group versus 66.7% in the PO group.

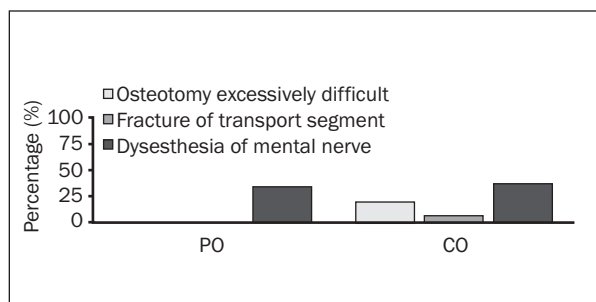
Five instruments were required to perform the osteotomy in the CO group, whereas in the PO group only the insert of the Piezosurgery system was used. By this criterion, then, the degree of surgical difficulty was higher for the conventional technique.

Intraoperative complications recorded were as shown in Fig 2. Excessive difficulty in performing osteotomy was experienced in 11.8% of cases, all in the CO group (18.2% of cases in this group;  $P = .404$ ). Fracture of the transport segment during surgery occurred in 5.9% of cases, again all in the CO group (9.1% of cases in this group;  $P = .647$ ).

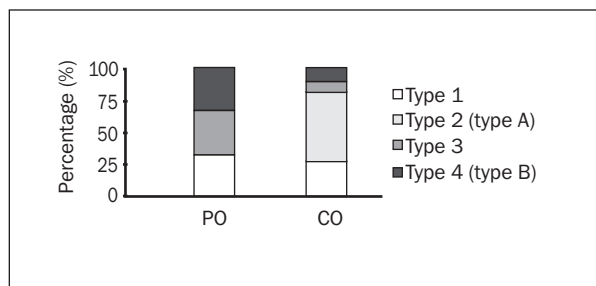
Postoperative complications recorded were as follows (Fig 2): dysesthesia of the mental nerve in 35.3% of cases (36.4% of cases in the conventional osteotomy group versus 33.3% of cases in the piezoelectric osteotomy group;  $P = 0.661$ ). In all cases, the dysesthesia was transitory, with gradual recovery in the first and second weeks postsurgery.

Complications recorded during distraction and consolidation were as shown in Fig 3. Exposure of the transport segment due to perforation of the mucosa was observed in 58.8% of cases (54.5% of cases in the CO group, 66.7% of cases in the PO group;  $P = 0.516$ ). Deviation of the direction of distraction was observed in 17.6% of cases (9.1% of cases in the CO group, 33.3% of cases in the PO group;  $P = 0.272$ ).

Postdistraction complications detected at implant placement were as follows (Fig 3): dehiscence or fenestration defects in 70.6% of cases (63.6% of cases in

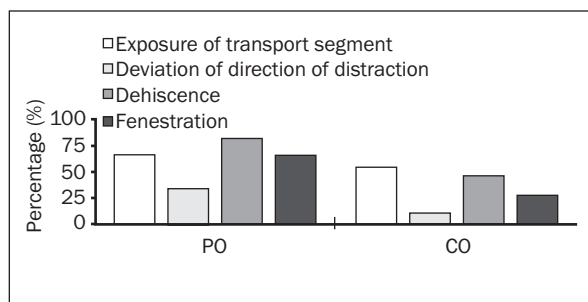


**Fig 2** Incidence of intraoperative and immediate postoperative complications in the CO and PO groups.



the CO group, 83.3% of cases in the PO group ( $P = .395$ ); specifically fenestration defects in 27.3% of cases in the CO group and 66.7% of cases in the PO group ( $P = 0.145$ ) and dehiscence defects in 45.5% of cases in CO and 83.3% of cases in PO ( $P = .160$ ). In all cases, fenestration and dehiscence defects were resolved by guided bone regeneration carried out at the same time as implant placement. Bio-Oss deproteinized bovine bone (Geistlich Pharma, Wolhusen, Switzerland) was used in 64.7% of these cases, and Bio-Gide resorbable membranes (Geistlich Pharma) in the remaining 41.2%.

Postdistraction morphology of the alveolar ridge, as recorded at implant placement, was type 1 in 29.4% of cases, type 2 in 35.3%, type 3 in 17.6%, and type 4 in 17.6% (classification of García-García et al<sup>7</sup>: where type 1 was the most favorable for implant placement and type 4 the least favorable. In the conventional osteotomy group, ridge morphology was type 1 in 27.3% of cases, type 2 in 54.5% of cases, type 3 in 9.1% of cases, and type 4 in 9.1% of cases. In the PO group, ridge morphology was type 1 in 33.3% of cases, type 2 in no cases, type 3 in 33.3% of cases, and type 4 in 33.3% of cases. There is thus a clear tendency for better-quality bone formation in the CO group (Fig 4): if we group the ridge morphology types into broader categories (A = types 1 and 2, ie good quality; B = types 3 and 4, ie poor quality), 81.8% of the ridges were type A and 18.2% type B in the CO group versus 33.3% and 66.7%, respectively, in the PO group ( $P = .072$ ).



**Fig 3** Incidence of complications during distraction, consolidation, and the postdistraction period in the CO and PO groups.

**Fig 4** Alveolar ridge quality as evaluated at implant placement, using the classification of García-García et al,<sup>7</sup> in the conventional osteotomy (CO) and piezoelectric osteotomy (PO) groups.

The overall success rate for distraction (implant placement and loading after distraction) was 88.2%, with only 2 failures (type 4), both in the PO group: thus, the overall success rate was 100% in the CO group versus only 66.7% in the PO group ( $P = .110$ ).

## DISCUSSION

Alveolar distraction is one of a number of techniques available for increasing the height of atrophic alveolar ridges prior to placement of dental implants, enabling the use of longer implants with shorter crowns, and thus improving both implant prognosis and esthetics.<sup>3</sup> The effectiveness of alveolar distraction for inverting crown-to-implant length ratio has been demonstrated in several studies.<sup>4,9,10</sup>

Alveolar distraction requires significant surgical skill and shows frequent but easily resolved minor complications.<sup>11</sup> The osteotomy is the difficult step: in order to maintain vascularization and thus prevent necrosis of the transport segment, it is essential to preserve the integrity of the periosteum when completing the osteotomy lingually.<sup>5</sup> Vertical alveolar distraction is typically used in sections of the mandible or maxilla that have been edentulous for a period of years, so that the dental nerve is typically close to the surface, thus increasing the risk of lesion. The osteotomy must thus be very precise, and this is the key attraction of piezoelectric osteotomy, which cuts only bone, not adjacent soft tissues. However, there

remains some risk of soft tissue lesion, either as a result of mechanical pressure exerted by the insert or as a result of heat generation, although the risk of heat lesion is lower than with rotary instruments,<sup>12</sup> and the risk of marginal osteonecrosis is marginal.<sup>13</sup>

The use of piezoelectric bone surgery devices can be learned rapidly,<sup>14</sup> and as a result many oral surgeons are now using this new technique in diverse types of intervention, often in the absence of objective confirmation of major efficacy.

In the present study, the 2 groups (conventional and piezoelectric osteotomy) showed similar age distributions and sex ratios. The same distraction procedure was used in both groups, and only cases using the same distraction device (the LEAD System) in the same mandibular region were selected, since these parameters may influence the appearance of complications. Only 2 cases, both in the CO group, were in patients who smoked.

For conventional osteotomy, a larger number of surgical instruments were used. By contrast, piezoelectric osteotomy is an easier technique requiring only a single tool (the handpiece with insert), and with only a low risk of soft tissue damage. Thus, piezoelectric osteotomy can be considered to have markedly lower surgical difficulty than conventional osteotomy.

Diverse types of complication can arise in alveolar distraction,<sup>11</sup> but in the present study the focus was on those that can be considered related to the osteotomy technique.

Intraoperative complications (fracture of the transport segment and excessive surgical difficulty) were recorded only in conventional osteotomy, not in piezoelectric osteotomy. These complications were mainly associated with the lingual completion of the osteotomy using chisels (Fig 2). Postoperative complications (dysesthesia of the mental nerve) showed a similar incidence in the 2 groups (31.3% in the conventional osteotomy group, 33.3% in the piezoelectric osteotomy group; Fig 2). In contrast, complications recorded during distraction and consolidation and postdistraction complications showed higher incidence in the PO group (overall incidence 61.1% versus only 39.5% in the CO group). These complications were exposure of the transport segment, deviation of the direction of distraction, and defects (dehiscences and fenestrations) detected at implant placement (Fig 3).

In a previous study,<sup>7</sup> the authors proposed a classification of the postdistraction morphology of the alveolar ridge as observed at implant placement. This classification groups morphology into 4 types, 1 to 4, from highest to lowest quality with regard to implant placement. In the CO group, only 12.6% of cases

showed poor quality (types 3 and 4), while in the PO group 66.7% of cases showed poor quality (Fig 4). This clear tendency did not reach statistical significance.

Overall rehabilitation success rate in previously reported series using alveolar distraction have ranged from 85% (Uckan et al<sup>10</sup>) to 100% (Chiapasco et al<sup>9</sup>). In the present study, a similar overall success rate (90.9%) was obtained; however, the success rate within the PO group was only 66.7% (4 of 6 cases).

Future studies with histologic evaluations may help to clarify the findings of the present study, which indicated that piezoelectric osteotomy is possibly not as effective as conventional osteotomy in alveolar distraction osteogenesis. However, these findings may in fact reflect macroscopic mechanical effects (related to the shape of the transport segment, or to an excessively wide gap between transport segment and basal bone) as opposed to direct damage to bone tissues by the ultrasonic vibration. It seems possible that piezoelectric osteotomy may indeed create a wider initial gap than conventional osteotomy, given that the osteotomy insert (OT6 = 0.65 mm) is thicker than the cutting end of a chisel. The OT7 (0.55 mm) seems less effective for osteotomy performance. It is possible that a wider gap, and the absence of a clean fracture as obtained with chisels, may favor the appearance of a granulation tissue without good osteogenic potential.

Although ultrasonic techniques have rapidly become widely used in oral surgery, there have been few well-designed studies with large patient series aimed at evaluating the efficacy and safety of these techniques; the majority of favorable reports have been based on single-case descriptions.<sup>14-21</sup> The present investigators believe that there is a need for caution in assessing these techniques.

## CONCLUSIONS

The results of the present study suggest that the use of piezoelectric osteotomy in distraction osteogenesis to increase alveolar ridge height prior to dental implant placement is easier for the surgeon and less prone to intraoperative complications than the use of conventional osteotomy procedures. However, results also suggest that piezoelectric osteotomy increases the risk of postoperative and postdistraction complications and reduces the overall rehabilitation success rate.



## REFERENCES

1. Vercellotti T. Technological characteristics and clinical indications of piezoelectric bone surgery. *Minerva Stomatol* 2004; 53:207–214.
2. González-García A, Diniz-Freitas M, Somoza-Martín M, García-García A. Piezoelectric bone surgery applied in alveolar distraction osteogenesis: A technical note. *Int J Oral Maxillofac Implants* 2007;22:1012–1016.
3. Friberg B, Jemt T, Lekholm U. Early failures in 4,641 consecutively placed Brånemark dental implants: A study from stage 1 surgery to the connection of completed prostheses. *Int J Oral Maxillofac Implants* 1991;6:142–146.
4. García-García A, Somoza-Martín M, Gándara-Vila P, Saulacic N, Gándara-Rey JM. Alveolar distraction before insertion of dental implants in the posterior mandible. *Br J Oral Maxillofac Surg* 2003;41:376–379.
5. Aronson J. Principles of Distraction Osteogenesis. Distraction of the Craniofacial Skeleton. New York: Springer-Verlag, 1999: 51–64.
6. Chin M. Distraction osteogenesis for dental implants. *Atlas Oral Maxillofac Clin North Am* 1999;7:41–63.
7. García-García A, Somoza-Martín M, Gándara-Vila P, Gándara-Rey JM. A preliminary morphologic classification of the alveolar ridge after distraction osteogenesis. *J Oral Maxillofac Surg* 2004;62:563–566.
8. García-García A, Somoza-Martín M, Gándara-Vila P, López-Maceiras J. Alveolar ridge osteogenesis using 2 intraosseous distractors: Uniform and nonuniform distraction. *J Oral Maxillofac Surg* 2002;60:1510–1512.
9. Chiapasco M, Romeo E, Vogel G. Vertical distraction osteogenesis of edentulous ridges for improvement of oral implant positioning: A clinical report of preliminary results. *Int J Oral Maxillofac Implants*. 2001;16:43–51.
10. Uckan S, Haydar SG, Dolanmaz D. Alveolar distraction: Analysis of 10 cases. *Oral Surg Oral Med Oral Pathol Oral Radiol Endod* 2002;94:561–565.
11. García-García A, Somoza-Martín M, Gándara-Vila P, López-Maceiras J. Minor complications arising in alveolar distraction osteogenesis. *J Oral Maxillofac Surg* 2002;60:496–501.
12. Horton JE, Tarpley TM Jr, Wood LD. The healing of surgical defects in alveolar bone produced with ultrasonic instrumentation, chisel, and rotary bur. *Oral Surg Oral Med Oral Pathol* 1975;39:536–546.
13. Vercellotti T, Nevins ML, Kim DM, Nevins M, Wada K, Schenk RK, Fiorellini JP. Osseous response following resective therapy with piezosurgery. *Int J Periodontics Restorative Dent* 2005; 25:543–549.
14. Robiony M, Polini F, Costa F, Vercellotti T, Politi M. Piezoelectric bone cutting in multipiece maxillary osteotomies. *J Oral Maxillofac Surg* 2004;62:759–761.
15. Torrella F, Pitarch J, Cabanes G, Anitua E. Ultrasonic Osteotomy for the surgical approach of the maxillary sinus: A technical note. *Int J Oral Maxillofac Implants* 1998;13:697–700.
16. Vercellotti T. Piezoelectric surgery in implantology: A case report—A new piezoelectric ridge expansion technique. *Int J Periodontics Restorative Dent* 2000;20:358–365.
17. Vercellotti T, de Paoli S, Nevins M. The piezoelectric bony window osteotomy and sinus membrane elevation: Introduction of a new technique for simplification of the sinus augmentation procedure. *J Periodontics Restor Dent* 2001;21:561–567.
18. Eggers G, Klein J, Blank J, Hassfeld S. Piezosurgery: An ultrasound device for cutting bone and its use and limitations in maxillofacial surgery. *Br J Oral Maxillofac Surg* 2004;42: 451–453.
19. Grenga V, Bovi M. Piezoelectric surgery for exposure of palatally impacted canines. *J Clin Orthod* 2004;38:446–448.
20. Chiriac G, Herten M, Schwarz F, Rothamel D, Becker J. Autogenous bone chips: Influence of a new piezoelectric device (Piezosurgery) on chip morphology, cell viability and differentiation. *J Clin Periodontol* 2005;32:994–999.
21. Stübinger S, Kuttenger J, Filippi A, Sader R, Zeilhofer HF. Intraoral Piezosurgery: Preliminary results of a new technique. *J Oral Maxillofac Surg* 2005;63:1283–1287.