

# Immediate Nonfunctional Loading of Single-Tooth Implants in the Anterior Maxilla Following Augmentation with Freeze-Dried Cancellous Block Allograft: A Case Series

Joseph Nissan, DMD<sup>1</sup>/George E. Romanos, DDS Dr Med Dent, PhD<sup>2,3</sup>/  
Ofar Mardinger, DMD<sup>4</sup>/Gavriel Chaushu, DMD, MSc<sup>5</sup>

**Purpose:** To assess the clinical effectiveness of immediate nonfunctional loading for single-tooth implants placed in the anterior maxilla following augmentation with cancellous freeze-dried block graft. **Materials and Methods:** The clinical outcomes of immediately nonfunctionally loaded implants up to 18 months after placement in the anterior maxilla were evaluated in 11 consecutive patients. Implants were immediately restored with unsplinted acrylic resin provisional crowns. Follow-up was monthly, and intraoral radiographs were obtained immediately after implant placement and at 6, 12, and 18 months. Survival rate and radiographic marginal bone loss were evaluated at 0, 6, 12, and 18 months. In the anterior maxilla, 12 implants were placed. **Results:** Marginal bone loss did not extend beyond the first thread up to 18 months follow-up, and the survival rate was 100%. **Conclusion:** Within the limits of the present study, immediate nonfunctional loading for single-tooth implants placed in the anterior maxilla following augmentation with cancellous freeze-dried block graft seems a promising treatment alternative. (Case Series) INT J ORAL MAXILLOFAC IMPLANTS 2008;23:709–716

**Key words:** block autograft, immediate loading, single-tooth implant

The traditional implant protocol<sup>1–3</sup> has several disadvantages. Among them are extensive treatment time, multiple surgeries, and the need to wear a removable restoration. Thus, several aspects of this

protocol have been re-evaluated, and new techniques have been pioneered.<sup>4</sup> These attempts were undertaken in the most favorable biological and biomechanical conditions (edentulous mandibles with good bone quality restored with a fixed superstructure or bar-retained overdentures with splinting).<sup>5–9</sup> Osseointegration and clinical stability of the implants can be maintained despite bone remodeling, as long as the micromovement is no more than 100 µm during the healing phase.<sup>10–12</sup>

Furthermore, the success of implant dentistry has also created a demand for implant placement in compromised sites. Currently, the gold standard for bone reconstruction is the use of autogenous bone. However, major drawbacks are donor site morbidity, the need for general anesthesia, immediate postoperative pain and edema, neurological disturbances, vascular complications, infection, scars, and organ deformity. Other drawbacks are insufficient initial bone density of the restored area and inability to sustain functional load, which results in graft resorption over the long term.<sup>13</sup> Preliminary case reports<sup>14–17</sup> suggested that a block allograft in con-

<sup>1</sup>Senior Lecturer and Director, Implant Prosthodontics, Department of Oral Rehabilitation, The Maurice and Gabriela Goldschleger School of Dental Medicine, Tel Aviv University, Tel Aviv, Israel.

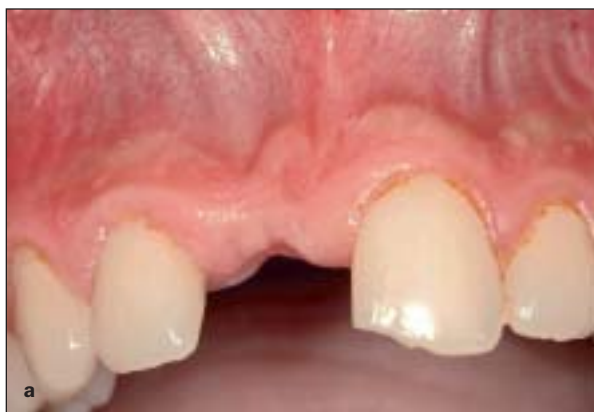<sup>2</sup>Professor of Clinical Dentistry, Department of Periodontology, Eastman Dental Center, University of Rochester, Rochester, New York.

<sup>3</sup>Lecturer, Department of Oral Surgery and Implant Dentistry, Dental School Frankfurt (Carolinum), University of Frankfurt, Frankfurt, Germany.

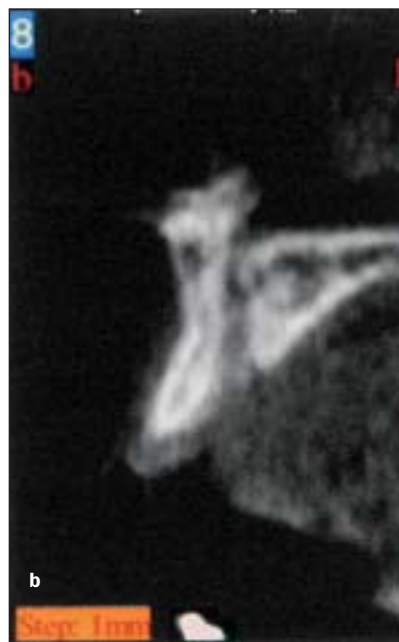
<sup>4</sup>Lecturer, Department of Oral and Maxillofacial Surgery, The Maurice and Gabriela Goldschleger School of Dental Medicine, Tel Aviv University, Tel Aviv, Israel.

<sup>5</sup>Senior Lecturer, Department of Oral and Maxillofacial Surgery, The Maurice and Gabriela Goldschleger School of Dental Medicine, Tel Aviv University, Tel Aviv, Israel.

**Correspondence to:** Dr Joseph Nissan, Department of Oral Rehabilitation, School of Dental Medicine, Tel Aviv University, Tel Aviv, Israel. E-mail: nissandr@post.tau.ac.il



**Fig 1** Pretreatment intraoral images: (a) frontal view and (b) CT paraxial reconstruction.



junction with a resorbable membrane may be an acceptable alternative to the autogenous block graft in the treatment of compromised alveolar ridges.

There is still insufficient data regarding the short- and long-term outcome of implants placed in augmented sites. However, a recent systematic review<sup>18</sup> concluded that implant survival varies from 79% to 100% and indicated that more than 90% survive after at least 1 year of loading. These results seem comparable to nonaugmented implant sites.

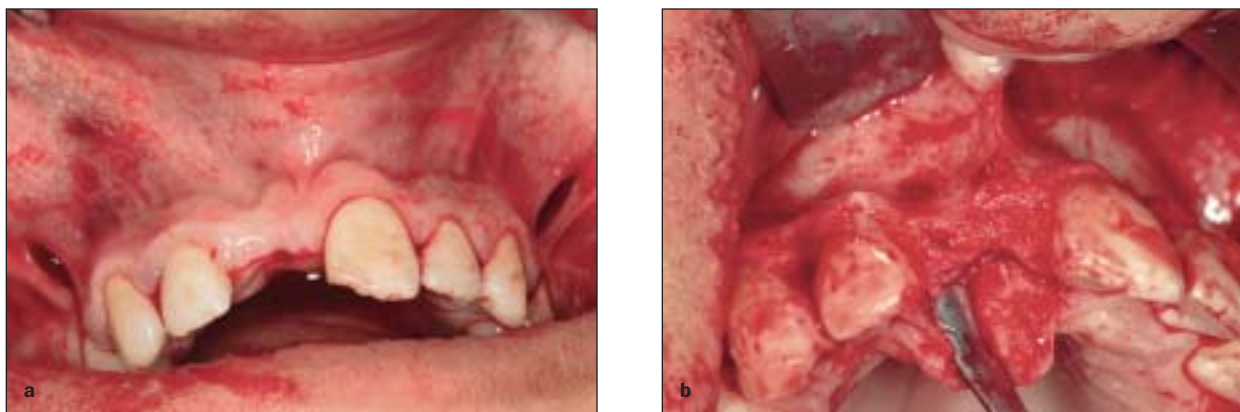Today, immediate restoration of single-tooth implants in the esthetic zone of the anterior maxilla is supported by experimental<sup>19,20</sup> and clinical<sup>21-27</sup> studies. Reports regarding immediate temporization of single-tooth implants placed in augmented compromised sites are scarce.<sup>28,29</sup> In these cases, the alveolar deficiency did not require the use of a block graft.

The hypothesis of the present clinical study was that the clinical outcome of immediate nonfunctional loading of unsplinted implants in the maxillary incisal region following augmentation with freeze-dried cancellous block allograft could be a predictable treatment approach clinically comparably successful to submerged maxillary anterior single-tooth implants placed according to a standard protocol. The outcome measures were based on clinical stability (absence of clinical implant mobility, implant fracture, and clinical signs of peri-implant infection) and on changes of radiographic crestal bone level from implant placement to an average of 12 months after insertion.

## MATERIALS AND METHODS

Criteria for inclusion in the study were good health with no positive history of bruxism, smoking, diabetes (type 1 or type 2), or osteoporosis. At least 3 mm bone deficiency in the horizontal, vertical, or both aspects of the maxillary anterior alveolar ridge was required as an inclusion criterion. A comprehensive evaluation was carried out to assess patients' systemic health and the status of all remaining teeth. Based on probing depths, attachment levels, percentage of sites with bleeding on probing, and mobility, all remaining teeth were considered to be in good periodontal health. The clinical evaluation and medical history review suggested no contraindications to implant therapy.

Oral examination focused on the smile line, intra-arch relationship, buccolingual width, and maxillo-mandibular relationship. Panoramic and periapical radiographs were evaluated for mesiodistal width (inter-radicular distance), residual bone beyond the apex, socket width, and root angulation. No periodontal disease and no periapical inflammatory involvement were diagnosed. Computerized tomography (CT) revealed that the implant sites demonstrated a bony deficiency of at least 3 mm horizontally and up to 4 mm vertically, resulting in compromised available bone (Fig 1). Pending successful augmentation, these sites were to receive single-tooth implant-supported restorations.



**Fig 2** Intraoperative intraoral views of (a) flap design and (b) bony defect.

The clinical and radiologic findings were thoroughly discussed with the patients, and all available treatment options were presented. Implant treatment alternatives were also explained. The possibilities of 1-stage surgery and loading versus 2-stage surgery or 1-stage surgery and a 3-month waiting period were emphasized. After careful consideration, patients who chose to avoid an intraoral or extraoral autograft and opted for placement of an allograft followed by nonfunctional immediate loading were included in the study. A staged approach was planned to reduce potential complications (wound dehiscence, block graft fracture, implant loss), which have been associated with simultaneous grafting and implant placement.<sup>14</sup> Prior to surgery, all patients gave their written informed consent.

One hour before surgery, 1,000 mg of amoxicillin and analgesics were administered orally. As a presurgical disinfectant, patients rinsed with 30 mL of a 0.12% chlorhexidine digluconate solution for 30 to 60 seconds.

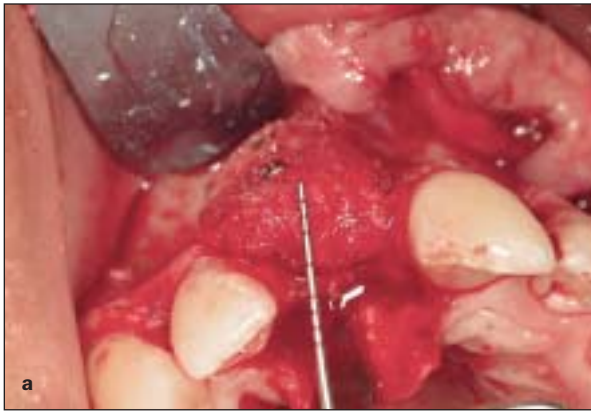Under local anesthesia (block and infiltration using 2% lidocaine with 1:100,000 epinephrine), a midcrestal incision was made. Buccal divergent releasing incisions beyond the intercanine area were used to avoid surgical scars within the esthetic zone. The wide flap allowed maximum exposure of the surgical site, enabling controlled placement and removal of the fixation screws and assisting with predictable wound closure. A full-thickness mucoperiosteal flap was elevated buccally (Fig 2a).

After exposure of the augmentation site (Fig 2b), the recipient bone was contoured to allow the graft to be placed into position for maximum bony contact and graft stability. Multiple perforations were made through the cortical plate with a half-millimeter round bur to ensure the broadest communication

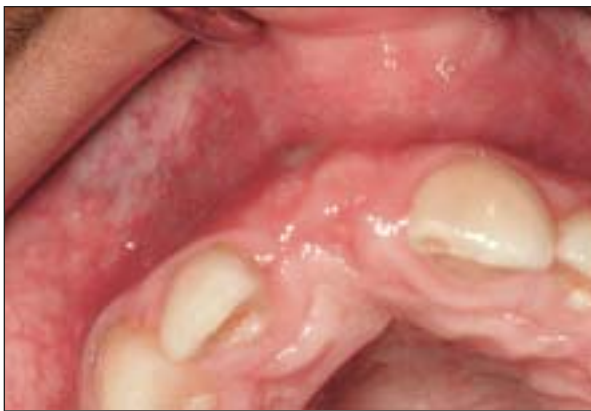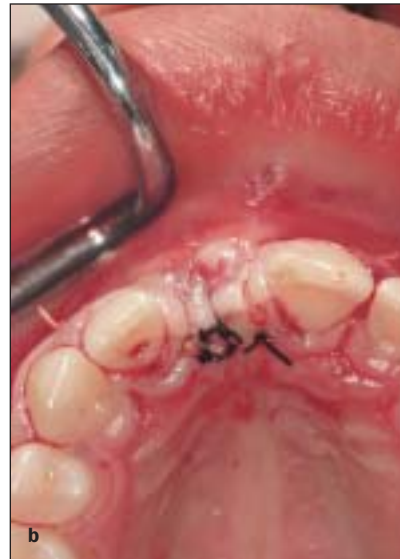possible between the grafted bone and bone marrow cavity and to induce revascularization and the influx of growth factors and platelets to enhance bone neogenesis.

The bony defects were grafted with cancellous allogeneic bone block graft. The prepared allograft was rehydrated with a sterile saline solution for at least 45 minutes before use. The size and curved shape of the edentulous area did not allow the use of the entire block. A 3 × 1.5 × 1.5-cm cube of freeze-dried cancellous block graft (ReadiGraft; Canblock 1.5, LifeNet, Virginia Beach, VA) was shaped with a fissure bur in a high-speed handpiece with copious irrigation. The result was a block graft that closely approximated the recipient bed and provided adequate width and height to accomplish the restorative treatment plan (Fig 3a). The graft was thoroughly rinsed with sterile saline to remove residual bone particles, and both the block graft and recipient bed were predrilled to accommodate a 1.2 mm × 10-mm bone screw (OsteoMed Corporation, Addison, TX). A high-speed, water-cooled, large round fluted bur was used to round the sharp cortical edges and shape it to completely conform to the defect site. The grafted area was covered with a resorbable membrane (Ossix; Biomet/3i, Palm Beach Gardens, FL) in 10 patients.

The buccal flap was undermined, and releasing incisions of the periosteum were made to permit primary closure over the bone graft. Special attention was given to ensure tension-free closure. The flap was closed with multiple interrupted mattress sutures (Fig 3b). Amoxicillin (Moxypen Forte, Teva Pharmaceutical Industries, Petach Tikva, Israel) 500 mg tid and 600 mg etodolac bid (Etopan, Taro Pharmaceutical Industries LTD, Haifa Bay, Israel) were administered orally for 5 days postoperatively. Chlorhexidine digluconate 0.2% rinses (Tarodent, Taro Pharmaceutical Industries, Haifa



**Fig 3** Intraoperative intraoral view of (a) block fixation and (b) soft tissue closure.



**Fig 4** Intraoral photograph 5 months postoperatively.

Bay, Israel) were also prescribed 2 times daily for 2 weeks. The patients were advised to use a soft diet for the first 2 to 4 weeks.

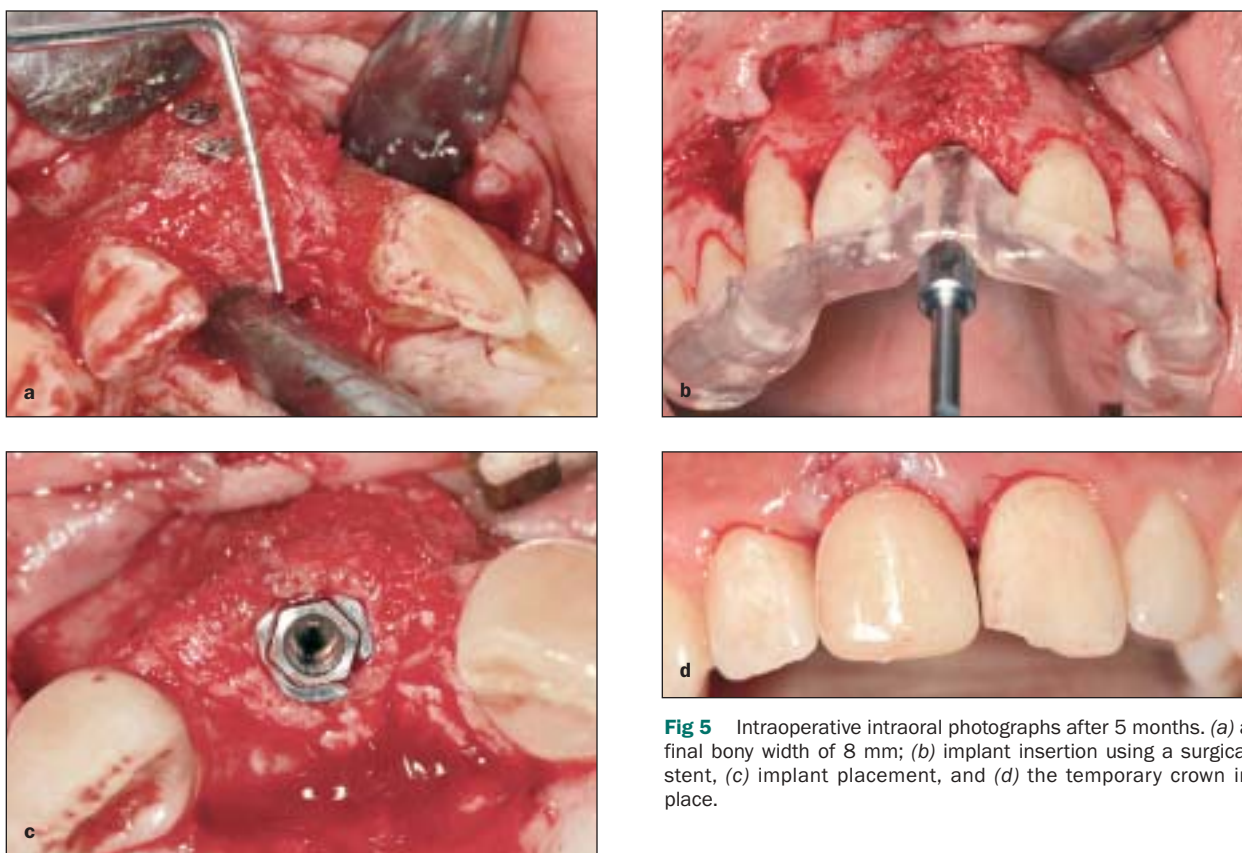
Provisional removable prostheses used during the entire healing period were adapted so as not to impinge on the block graft and result in wound dehiscence and bone resorption. Patients were seen weekly during the first month postsurgery and monthly thereafter until second-stage surgery. The status of the soft tissue was evaluated for complications. The re-entry surgical procedure to expose the graft was performed after 4 to 6 months (Fig 4). Under local anesthesia, a crestal incision was made, and a mucoperiosteal flap was elevated. A similar flap design was used to prevent vertical scars and to allow easy removal of the fixation screws. Clinical evaluation of the grafted area was carried out

to examine bone regeneration. Surgical exposure of the augmentation sites revealed well-integrated block grafts incorporated into the surrounding cortical bone (Fig 5a). Minimal resorption was noted around the fixation screws, which were then removed. A UNC periodontal probe (Hu-Friedy, Chicago, IL) was used to measure bone gain. An osteotomy was prepared according to a surgical stent (Fig 5b). A standard drilling technique was used to insert 9 implants 13 mm long and 4 mm in diameter (3i/Implant Innovations, Palm Beach Gardens, FL) and 3 implants 13 mm long and 3.7 mm in diameter (Zimmer Dental, Carlsbad, CA). Implants were threaded manually without tapping into position and without any need for additional bone augmentation (Fig 5c) using insertion torque of 32 N/cm<sup>2</sup>. Bone in the region of the implant preparation was stable throughout implant placement, and there was no evidence of graft separation or fracture. A temporary custom abutment was placed, and the soft tissue was reapproximated and stabilized with sutures. No implant movement during abutment tightening was seen.

The provisional acrylic resin crowns were prefabricated in the laboratory prior to surgery to avoid trauma to the implant during surgery. Maxillary and mandibular alginate impressions were made and master casts fabricated. An acrylic resin provisional crown was created. The occlusion was adjusted and finalized on a semi-adjustable articulator without contacts in lateral, intercuspal, or protrusive excursions.

The temporary crown was placed over the temporary custom abutment at the end of the surgery (Fig 5d). The prepared temporary acrylic crown was relined with minimum acrylate and placed over the abutment with a minimum of temporary cement.





**Fig 5** Intraoperative intraoral photographs after 5 months. (a) a final bony width of 8 mm; (b) implant insertion using a surgical stent, (c) implant placement, and (d) the temporary crown in place.

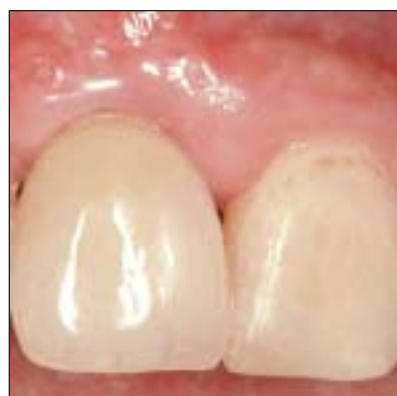Attention was paid to verify the elimination of contact with the temporary crown during lateral, intercuspal, and protrusive movements.

Patients were seen once a month for 3 months. Healing was uneventful, minimal swelling was observed, and the patients required minimal analgesics.

At 3 to 6 months after implant placement, radiographs of the implant sites were obtained, and the implant was restored with a single-tooth ceramic restoration (Fig 6). The clinical view at this stage demonstrated good symmetry and esthetics.

## RESULTS

From 2004 to 2006, consecutive patients ( $n = 11$ , 2 men, 9 women) aged 18 to 45 years (mean,  $24 \pm 8$  years) who required placement of single-tooth implants in the anterior maxillary area and extensive bone augmentation, were selected. Reasons for tooth loss included trauma (4), congenitally missing teeth (3), implant failure (2), and endodontic failure (2). The surgical bony augmentation, subsequent implant placement, and immediate loading proceeded smoothly. Bone gain horizontally (4 to 6 mm, mean  $5 \pm 0.5$  mm) or both dimensions is shown in Table 1.

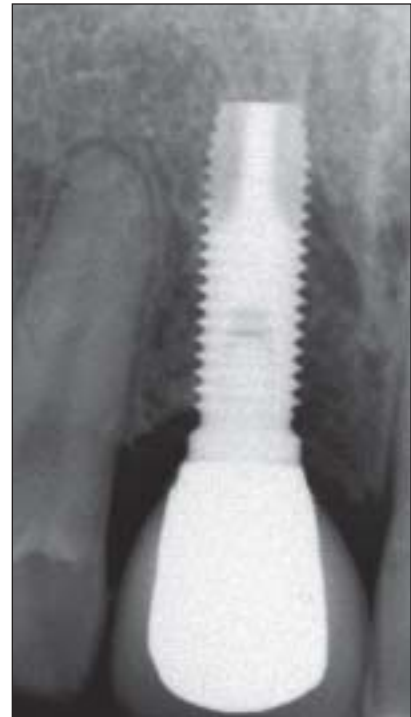


**Fig 6** The definitive crown in place, demonstrating good symmetry and esthetics.

Postsurgical healing was uneventful for all patients. Minimal pain and swelling were the most frequently mentioned signs and symptoms. Soft tissue closure over the grafted bone was achieved in all sites. Minimal soft tissue dehiscence was observed in only 1 patient, which resolved spontaneously after 3 weeks. No residual bone defects were observed after implant sites were probed at 3 to 6 months postplacement (prior to placement of the definitive restoration). All implants were asymptomatic and immobile. Three

**Table 1** Characteristics of Augmented Bone

Patient	Horizontal bone measurement (mm)		Vertical bone missing (mm)	
	Preoperative	Postoperative	Preoperative	Postoperative
1	3	9	—	—
2	3	8	—	—
3	3	8	—	—
4	3	8	—	—
5	3	9	—	—
6	3	8	3	0
7	3	8	—	—
8	3	8	—	—
9	3	8	—	—
10	3	8	—	—
11	2	6	4	0

**Fig 7** Periapical radiograph at the 1-year follow-up. Marginal bone loss stopped at the first thread.

implants were restored with ceramometal restorations, and the remaining 9 were restored with all-ceramic restorations.

All implants were successful after definitive restoration, with no signs of mobility, pain, suppuration, or peri-implant radiolucency. Radiographic measurements showed no bone loss beyond the first thread (Fig 7). The prosthetic rehabilitations were in function and in good condition up to 15 months follow-up.

## DISCUSSION

In the present study, promising data were shown for immediately nonfunctionally loaded single-tooth implants in the anterior maxilla following augmentation with freeze-dried cancellous block graft. Immediate loading is a confrontation between the occurrence of a biological process (ie, osseointegration) and mechanical loading. Optimal primary stability is mandatory in these cases to support the biology and maximize the possibility of osseointegration.<sup>21</sup> Insertion torque is a relative risk factor for the survival of immediately loaded single-tooth implants. A minimum insertion torque of 32 Ncm has been proposed for early loading.<sup>30</sup> In the present study, all the implants were inserted according to these criteria. It may be suggested that good insertion torque contributed to the survival of the implants.

Adequate occlusion is the best way to minimize and control the mechanical loading (ie, minimal centric and eccentric contacts). Furthermore, the occlusal forces exerted by the patient can be reduced by limiting the diet to soft foods for approximately 2 to 4 weeks after implant insertion.<sup>31</sup>

The provisional restorations should not be manipulated during the healing period. Tarnow et al<sup>8</sup> suspected that early failures were the result of such manipulation. Strict inclusion criteria (ie, nonsmokers, nonbruxers, stable occlusion, high primary stability) are another prerequisite. In contrast, Romanos<sup>32</sup> suggested the removal of the temporarization with a needle holder to control the soft tissue around the implants and plaque accumulation and to evaluate the implant stability.

In the radiographs, marginal bone loss did not extend beyond the first thread. Consequently, the excellent papilla formation in these patients can be related to the bone maintenance observed.<sup>25</sup> Salama et al<sup>33</sup> suggest that the macro- and microstructure of the implant is an important factor contributing to success or failure. In the present study, 3i and Zimmer Dental screw-type implants, 13 mm long and 3.7 to 4 mm in diameter, were used to allow improved mechanical stability. The implant was inserted without tapping to provide additional initial stabilization. Using optimum implant thread geometry, it was possible to load functionally implants also in areas with simultaneous augmentations.<sup>32</sup>

A key issue for future studies will be to define minimum parameters, such as primary stability, length, diameter, bone quality, implant surface, for immediate loading of unsplinted implants placed in augmented bone. Another important objective will be to determine the most advantageous components for manufacturing temporary crowns.

Advantages of the described technique include lack of need for a donor site, thus minimizing post-operative morbidity; elimination of second-stage implant placement surgery, resulting in reduced surgical trauma; minimal use of a provisional removable restoration, and the ability to satisfy esthetic demands in the shortest possible time. All of these advantages allowed implementation of an implant-supported fixed prosthesis in cases that would have been impossible to perform previously due to patient unwillingness.

Although the technique seems simple, it is highly technique-sensitive and is recommended only for experienced implantologists. Until there are more published data, the surgeon, the prosthodontist, and the patient must be aware of potential complications. Treatment alternatives should be thoroughly emphasized to the patient. Further clinical and histologic studies are necessary to promote routine clinical application of this technique.

## CONCLUSION

Within the limits of the present study, the preliminary data indicate that immediate nonfunctional loading of single-tooth implants in the anterior maxilla following augmentation with freeze-dried cancellous block grafts and healing can result in successful implant integration and stable peri-implant conditions up to 18 months.

## REFERENCES

- Adell R, Lekholm U, Rockler B, Brånemark P-I. A 15-year study of osseointegrated implants in the treatment of the edentulous jaw. *Int J Oral Surg* 1981;10:387-416.
- Albrektsson T, Brånemark P-I, Hansson HA, Lindström J. Osseointegrated titanium implants: Requirements for ensuring a long lasting, direct bone to implant anchorage in man. *Acta Orthop Scand* 1981;52:155-170.
- Brånemark P-I. Osseointegration and its experimental background. *J Prosthet Dent* 1983;50:399-410.
- Szmukler-Moncler S, Piattelli A, Favero GA, Dubruille J-H. Considerations preliminary to the application of early and immediate loading protocols in dental implantology. *Clin Oral Implants Res* 2000;11:12-25.
- Babbush CA, Kent J, Misiek D. Titanium plasma sprayed (TPS) screw implants for the reconstruction of the edentulous mandible. *Int J Oral Maxillofac Surg* 1986;44:274-282.
- Chiapasco M, Gatti C, Rossi E, Haefliger W, Markwalder TH. Implant-retained mandibular overdentures with immediate loading. A retrospective multicenter study on 226 consecutive cases. *Clin Oral Implants Res* 1997;8:48-57.
- Schnitman PA, Wöhrle PS, Rubenstein JE, Da Silva JD, Wang N-H. Ten-year results for Brånemark implants loaded with fixed prostheses at fixture placement. *Int J Oral Maxillofac Implants* 1997;12:495-503.
- Tarnow DP, Emtiaz S, Classi A. Immediate loading of threaded implants at stage 1 surgery in edentulous arches: Ten consecutive case reports with 1- to 5-year data. *Int J Oral Maxillofac Implants* 1997;12:319-324.
- Randow K, Ericsson I, Nilner K, Petersson A, Glantz P-O. Immediate functional loading of Brånemark dental implants. An 18-month clinical follow-up study. *Clin Oral Implants Res* 1999;10:8-15.
- Pilliar RM, Lee JM, Maniopoulos C. Observations on the effect of movement on bone in-growth into porous-surfaced implants. *Clin Orthop* 1986;208:108-113.
- Brunski JB. Forces on dental implants and interfacial stress transfer. In: Laney WR, Tolman DE (eds). *Tissue Integration in Oral, Orthopaedic and Maxillofacial Reconstruction*. Chicago: Quintessence, 1992:108-124.
- Brunski JB. Avoid pitfalls of overloading and micromotion of intraosseous implants [interview]. *Dent Implantol Update* 1993;4:77-81.
- Boyne PJ. Bone grafts: Materials. In: *Osseous Reconstruction of the Maxilla and the Mandible: Surgical Techniques Using Titanium Mesh and Bone Mineral*. Chicago: Quintessence, 1997: 3-11.
- Leonetti JA, Koup R. Localized maxillary ridge augmentation with a block allograft for dental implant placement: Case reports. *Implant Dent* 2003;12:217-226.
- Lyford RH, Mills MP, Knapp CI, Scheyer ET, Mellonig JT. Clinical evaluation of freeze-dried block allografts for alveolar ridge augmentation: A case series. *Int J Periodontics Restorative Dent* 2003;23:417-425.
- Keith JD Jr. Localized ridge augmentation with a block allograft followed by secondary implant placement: A case report. *Int J Periodontics Restorative Dent* 2004;24:11-17.
- Petrungaro PS, Amar S. Localized ridge augmentation with allogeneic block grafts prior to implant placement: Case reports and histologic evaluations. *Implant Dent* 2005;14: 139-148.
- Hämmerle CH, Jung RE, Feloutzis A. A systematic review of the survival of implants in bone sites augmented with barrier membranes (guided bone regeneration) in partially edentulous patients. *J Clin Periodontol* 2002;29(suppl 3):226-331.
- Piattelli A, Corigliano M, Scarano A, Costigliola G, Paolantonio M. Immediate loading of titanium plasma-sprayed implants: An histologic analysis in monkeys. *J Periodontol* 1998;69: 321-327.
- Corso M, Sirota C, Fiorellini JP, Rasool F, Szmukler-Moncler S, Weber HP. Clinical and radiographic evaluation of early loaded free-standing dental implants with various coatings in beagle dogs. *J Prosthet Dent* 1999;82:428-435.
- Wöhrle PS. Single-tooth replacement in the aesthetic zone with immediate provisionalization: Fourteen consecutive case reports. *Pract Periodontics Aesthet Dent* 1998;10:1107-1114.
- Ericsson I, Nilson H, Lindh T, Nilner K, Randow K. Immediate functional loading of Brånemark single-tooth implants: An 18 months' clinical pilot follow-up study. *Clin Oral Implants Res* 2000;11:26-33.
- Garber DA, Salama MA, Salama H. Immediate total root replacement in the external root resorption case. *World Dentistry* 2000;1:1-5.

24. Chaushu G, Chaushu S, Tzohar A, Dayan D. Immediate loading of single-tooth implants: Immediate vs. non-immediate implantation. A clinical report. *Int J Oral Maxillofac Implants* 2001;16:267–272.
25. Cooper L, Felton DA, Kugelberg CF, et al. A multicenter 12-month evaluation of single-tooth implants restored 3 weeks after 1-stage surgery. *Int J Oral Maxillofac Implants* 2001;16:182–192.
26. Dhanrajani PJ, Al-Rafee MA. Single-tooth implant restorations: A retrospective study. *Implant Dent* 2005;14:125–130.
27. Salvi GE, Gallini G, Lang NP. Early loading (2 or 6 weeks) of sandblasted and acid-etched (SLA) ITI implants in the posterior mandible. A 1-year randomized controlled clinical trial. *Clin Oral Implants Res* 2004;15:142–149.
28. Fugazzotto PA. Guided bone regeneration at immediate implant insertion and loading. A case report. *Implant Dent* 2004;13:223–227.
29. Park YS, Yi KY, Moon SC, Jung YC. Immediate loading of an implant following implant site development using forced eruption: A case report. *Int J Oral Maxillofac Implants* 2005;20:621–626.
30. Ottoni JM, Oliveira ZF, Mansini R, Cabral AM. Correlation between placement torque and survival of single-tooth implants. *Int J Oral Maxillofac Implants* 2005;20:769–776.
31. Romanos GE. Immediate loading of endosseous implants in the posterior area of the mandible. *Animal and clinical studies*. Berlin: Quintessence, 2005.
32. Romanos GE. Surgical and prosthetic concepts for predictable immediate loading of oral implants. *J Can Dent Assoc* 2004;32:991–1001.
33. Salama H, Rose LE, Salama M, Betts N. Immediate loading of bilaterally splinted titanium root form implants in fixed prosthodontics—A technique reexamined: Two case reports. *Int J Periodontics Restorative Dent* 1995;15:345–361.