

Immediate Loading Using Cross-Arch Fixed Restorations in Heavy Smokers: Nine Consecutive Case Reports for Edentulous Arches

George E. Romanos, DDS, Dr Med Dent, PhD^{1,2}/Georg-Hubertus Nentwig, DMD, Dr Med Dent, PhD¹

Purpose: Immediate loading of oral implants has been extensively documented in different clinical indications, but no studies on heavy smokers have been reported. The aim of this study was to evaluate the long-term success and the peri-implant soft and hard tissue conditions around immediately occlusal loaded implants in edentulous jaws of heavy smokers. **Materials and Methods:** Implants (progressive thread design and platform switching) were connected with their abutments and splinted immediately after surgery using cross-arch fixed temporary restorations. Provisional fixed prostheses had centric occlusal contacts and group function in the lateral movements of the mandible (immediate occlusal loading). Patients were advised to adhere to a soft diet for the first 6 to 8 weeks of healing to reduce excessive loading in the bone-implant interface. The definitive restorations were delivered 4 to 8 weeks after surgery and cemented temporarily to evaluate the peri-implant soft tissue condition after removal of the restoration. Clinical and radiographic indices were evaluated at the start of loading and at 3-month intervals after loading. **Results:** After a mean loading period of 33.7 ± 19.0 months (range, 6 to 66 months), 1 implant was mobile. All clinical indices had values in normal ranges. The Periotest values decreased with time, indicating increased security of implants in bone. Crestal bone level was stable, with only 2 sites presenting minimal vertical bone loss and 6 presenting minimal horizontal bone loss. In all other sites no bone loss was observed. Results of this study demonstrated a long-term success (98.6%) of immediately loaded implants placed in occlusal function in smokers restored with fixed cross-arch implant-supported restorations. **Conclusions:** This study showed that immediate loading of oral implants may be successful in heavy smokers under some circumstances. INT J ORAL MAXILLOFAC IMPLANTS 2008;23:513–519

Key words: implant, immediate loading, smoking

Rehabilitation with dental implants is associated with a higher failure rate in smokers in comparison with nonsmokers.¹ In addition, smoking has been associated with high implant failure rates and with multiple failures in the same patient.^{2–6} In a 10-

year study, Lindquist et al⁷ found greater bone loss around mandibular implants placed in smokers compared with those placed in nonsmokers. They noticed a relationship between the amount of cigarette consumption and the amount of peri-implant marginal bone loss.

In contrast, in a study by Kan et al,⁸ the implant failures in smokers were not correlated with daily nicotine consumption. This was documented in patients who received implants with different designs and geometries in grafted sinuses and were followed for a mean of 41.6 months. However, more implant failures and healing complications have been demonstrated in patients who smoke. Specifically, implant success in cases where maxillary antral-nasal inlay bone grafts were placed in combination with the implants was lower in smokers,⁹ as was the

¹Department of Oral Surgery and Implantology, Dental School (Carolinum), Frankfurt, Germany.

²Department of Periodontology, Eastman Dental Center, Rochester, New York.

Correspondence to: Dr George E. Romanos, Department of Periodontology, Eastman Dental Center, University of Rochester, 625 Elmwood Avenue, Rochester, NY 14620.

success rate of implants placed in grafted maxillary sinuses (65.3% in smokers versus 82.7% in nonsmokers).⁸ In general, the incidence of healing complications after intraoral bone grafting and implant placement seems to be higher in smokers compared to nonsmokers.¹⁰ Furthermore, smoking has been connected to reduced bone mineral density.¹¹

Moreover, a load-free period around endosseous oral implants was once believed to be a prerequisite to achieve osseointegration. However, immediate loading has been established as a successful treatment concept in the edentulous mandible, when primary stability can be achieved and the implants are immobilized by either a bar¹²⁻¹⁴ or a fixed restoration.¹⁵⁻²¹ Heavy smokers have been excluded from studies of immediate loading concepts.^{14,18,20,21} Thus, there are no data of immediately loaded implants placed in heavy smokers. The purpose of this study was to evaluate the success rate of immediately loaded implants placed in heavy smokers in edentulous arches using cross-arch restorations.

MATERIALS AND METHODS

Nine patients (5 male and 4 female) with a mean age of 52.4 ± 8.3 years who smoked more than 2 packs a day for more than 10 years (heavy smokers) were included in this prospective clinical study.

Seventy-two implants (6 implants in each jaw; 6 maxillae and 6 mandibles) made from commercially pure titanium (grade II) with a progressive thread design and a sandblasted surface (Ankylos; Friadent, Mannheim, Germany) were used. These implants were placed using a surgical guide splint after clinical and radiologic presurgical diagnostic examination by a single surgeon (GR) according to the protocol of the manufacturer. The implants had a 2.0-mm machined collar, a diameter of 3.5, 4.5, or 5.5 mm, and a length of 9.5 mm, 11.0 mm, or 14.0 mm.

Patients were included in the study if they met the following criteria: (1) complete edentulism in the maxilla and/or the mandible; (2) rehabilitation with endosseous dental implants planned (ie, considered the ideal treatment); (3) written informed consent for continuous smoking during the entire study period; (4) physical and mental ability to tolerate conventional surgical and restorative procedures; and (5) smoking history of 2 packs per day for more than 10 years. The informed consent included information on the medical and dental benefits of smoking cessation. Exclusion criteria were (1) active infection in the sites selected for implant placement, (2) systemic diseases such as uncontrolled diabetes, (3) pregnancy, and (4) severe bruxism.

Patients had various combinations of teeth and/or implants in the opposing arch. Three patients had implant-supported restorations, 1 patient had tooth- and implant-supported fixed partial dentures, and 4 patients had healthy teeth. One patient was edentulous and had a full denture. All patients had to sign a special informed consent form in accordance with the Declaration of Helsinki (no. 91/99; sub-study C). If a patient decided to reduce or stop smoking during the study period, he or she was excluded from the study.

The implants were placed using a surgical template and connected to abutments (angulated or straight) immediately after their insertion using a final torque of 15 or 25 Ncm, respectively. Temporary healing caps were placed, and the flaps were sutured using interrupted sutures (4-0 silk suture material; Resorba, Nuremberg, Germany). All implants were splinted using a fixed temporary restoration immediately after surgery. Temporary partial prostheses were made chairside with Protemp acrylic resin (Espe, Seefeld, Germany) using a template over the temporary caps placed on the abutments. No distal cantilevers were used in the provisional prostheses. The provisional prostheses were cemented temporarily on the same day as the surgical procedure, using Temp Bond cement (Kerr, Karlsruhe, Germany). The temporary restorations had symmetric occlusal contacts in maximal intercuspation and group functional contacts in lateral movement of the mandible, which kept the vertical dimension at the correct height (immediate occlusal, functional loading).

The patients were advised to confine their diets to soft foods or fluids for the first 6 to 8 weeks of healing to reduce excessive loading at the bone-implant interface. Postoperative antibiotic administration was not given any patient at any time during the treatment period (Figs 1 to 3).

Immediately after surgery, implant stability was evaluated using the Periotest device (Gulden, Bensheim, Germany). Sutures were removed 1 week after surgery. Two weeks after surgery, all clinical peri-implant indices (ie, Plaque Index [PI], Sulcus Bleeding Index [SBI], mesial and buccal probing pocket depth, width of the keratinized mucosa) were evaluated (baseline). Bone loss was measured from the implant to the marginal crestal bone compared to the baseline and classified as horizontal or vertical.^{22,23} Clinical indices were evaluated at the time of the placement of the final restoration, as well as at 3-month follow-up visits. Panoramic radiographs (10 \times magnification) were recorded to evaluate the peri-implant crestal bone levels at the same time intervals.

Three to 4 weeks after surgery the temporary restorations were removed so that impressions for the definitive prostheses could be made. No compli-

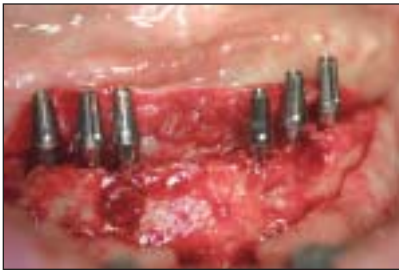
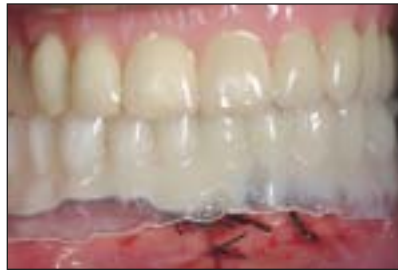
Fig 1 Implant placement and abutment connection for immediate loading.



Figs 2 and 3 A provisional prosthesis fabricated chairside for immediate occlusal loading.

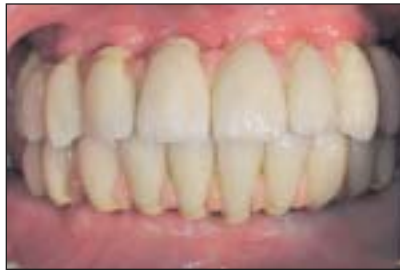
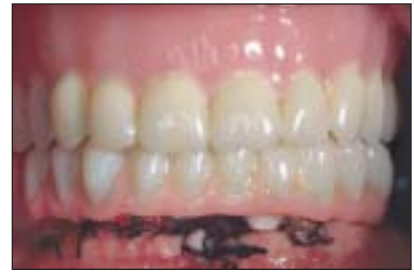
Fig 4 A definitive restoration in occlusion.

Table 1 Implant Characteristics

Length	Diameter (mm)			Total
	3.5	4.5	5.5	
9.5	0	6	0	6
11.0	18	14	1	33
14.0	28	5	0	33
Total	46	25	1	72

cations or failures were observed at that time.²³ The surgeon was also the restorative dentist (GR) for all patients. Definitive restorations were fabricated in the dental laboratory by a team of dental technicians and included only full-arch (1-piece) restorations. Occlusal registration and measurement of the vertical dimension were carried out. A custom-made framework was fabricated for a metaloceramic fixed restoration. The definitive prostheses were delivered 4 to 8 weeks after surgery and cemented temporarily so that the peri-implant soft tissue condition could be evaluated periodically after removal of the restorations. No screw-retained restorations were used. The patients were checked for sufficient occlusal contacts, and excessive contacts in the lateral movements of the mandible were eliminated (Fig 4). Patients were evaluated once every 3 months for the first year of loading and once a year thereafter.

The criteria for success were (1) no clinically detectable mobility; (2) no peri-implant radiolucency; (3) no complaint of pain at the implant site; (4) no recurrent or persistent peri-implant infection; (5) no neuropathy or paresthesia; (6) less than 1.6 mm of marginal bone loss in the first year of functional loading and less than 0.2 mm per year in the follow-up visits.²⁴

RESULTS

Thirty-six implants were placed in 6 mandibles, and 36 were placed in 6 maxillae. All implants but 1 had a diameter of 3.5 or 4.5 mm (Table 1). The only 5.5-mm-diameter implant used was placed in an area with poor bone quality (very soft bone after condensation). The implant lengths used are shown in Table 1.

Primary stability was achieved for all implants. Sixteen implants had an inadequate amount of bone at the desired site (mesially, buccally, and distally); exposed threads were covered with autogenous bone graft harvested from adjacent donor sites. The augmented areas were covered by a Bio-Gide collagen membrane (Geistlich, Wolhusen, Switzerland), which was fixed in place with Frios titanium pins (Friadent, Mannheim, Germany). One implant was placed in combination with an internal sinus lift (osteotome technique). In 1 case with extreme atrophy of the mandible, a customized milled bar restoration was fabricated to replace the missing soft and hard tissues with a hybrid-type, fixed detachable restoration.

After a mean loading period of 33.7 ± 19.0 months (range, 6 to 66 months), 1 implant had a relative high Periotest value (+9) in the last evaluation.

Table 2 Peri-implant Clinical Examination Results

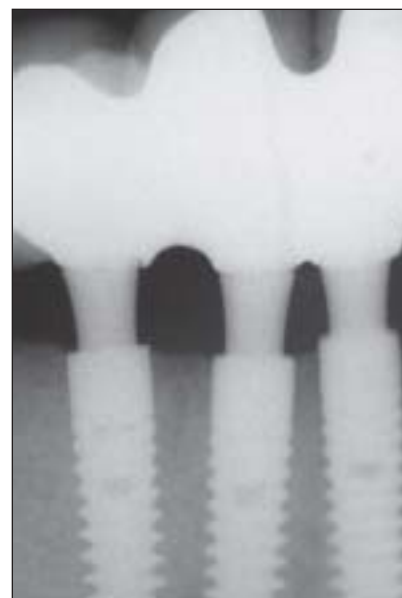
	T ₀		T ₁		T ₂	
	Mean	SD	Mean	SD	Mean	SD
PV	0.9	2.6	-0.4	3.2	-1.3	2.5
PI	1.0	1.2	1.2	1.1	1.3	1.1
SBI	0.3	0.6	0.5	0.7	0.7	0.1
PPD (mm)	1.7	0.7	1.7	0.7	2.7	0.9
KM (mm)	4.6	1.1	4.3	1.4	3.3	1.7

T₀ = baseline; T₁ = placement of the definitive restoration; T₂ = final follow-up. PV = Periostest value; PPD = periodontal probing depth; KM = keratinized mucosa. Baseline was measured immediately after surgery for Periostest value and 2 weeks after surgery for all other variables.

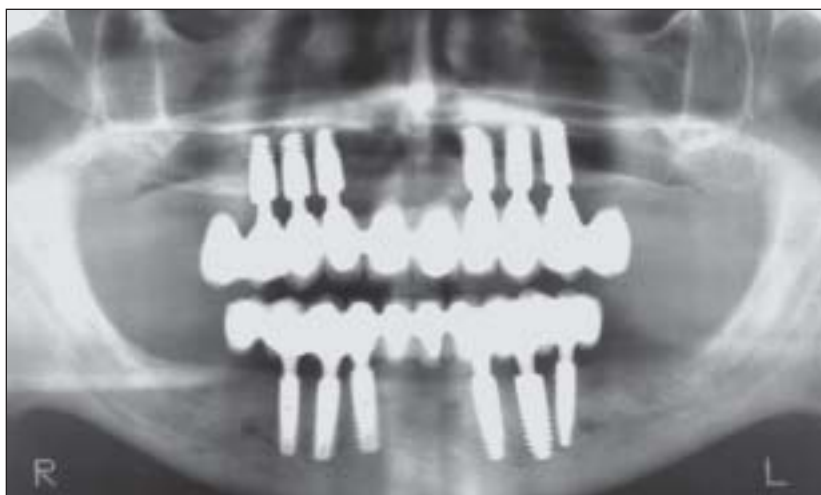

Fig 5 (Above) Radiologic evaluation of immediately loaded implants 3 years after loading.

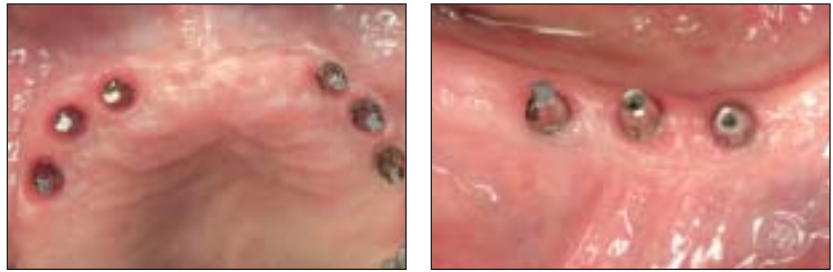
Figs 6 and 7 (Right) Bone levels 3 years after immediate loading. No bone loss was observed. Original implant placement was supracrestal.



Because this patient died due to a heart attack a couple of months after his last follow-up visit, it was decided to classify this implant as a “failure.” This implant was placed in the maxilla and was connected with a distal cantilever, but there was no radiolucency, and the probing depth was acceptable. Therefore, the overall success rate of this study was 71/72. The peri-implant clinical values were evaluated by an independent examiner who was calibrated for the periodontal measurements presented in Table 2. The Periostest values decreased over time,

with a statistically significant difference (Wilcoxon test; $P < .001$) between baseline (T₀) and the last follow-up visit (T₂). All other clinical indices were within normal ranges, which is in accordance with the healthy appearance of the peri-implant soft tissue observed. The bone loss represented by the radiographs (10× magnification) showed vertical bone loss less than 2 mm (in 2 sites) and horizontal bone loss less than 2 mm (in 8 sites). In all other sites no bone loss was observed (Figs 5 to 8).

Fig 8 Healthy peri-implant soft tissues in the (a) maxilla or (b) mandible 3 years after immediate loading.



DISCUSSION

The present study demonstrated preliminary data for immediately loaded implants placed in the edentulous arches of heavy smokers. There is no doubt that a larger patient sample is necessary in order to call this preliminary study an “evidenced-based study.”

In the present treatment protocol, the final abutments were not removed from the implants at any time during the loading period. Animal studies have shown peri-implant crestal bone stability with a variety of loading protocols.²⁵ In addition, bone stability seems to be independent of the shape of the implant platform.²² In the present study, the success of the immediately loaded implants was not related to bone quality, diameter, length, and position of the implant or simultaneous augmentation.

However, we have to accept that smoking is a significant factor in the development and progression of periodontal diseases and that gingival bleeding is diminished in smokers.²⁶ Bone loss is greater in such patients.²⁷ Implant failures can be 2.5 times greater in smokers, whereas the genotype status does not appear to be a significant factor for implant loss.²⁸ Haas et al²⁹ showed greater gingival bleeding index scores, peri-implant probing depth, and inflammation with a greater marginal bone loss around implants for smokers than for nonsmokers.

Three groups have been studied with respect to the use of fixed restorations with immediate loading: nonsmokers,¹⁸ occasional smokers (smoking less than 1 pack/day),^{15,19–21,30} and heavy smokers.³¹ However, in other immediate-loading studies there is no reference to the smoking and nicotine use as an inclusion or exclusion criterion.^{16,17,19,32}

In a multicenter study (4 centers), Testori et al²¹ presented data from 325 immediately loaded Osseotite implants placed in the edentulous mandibles of 62 patients. No heavy smokers or areas with augmentation were included. The provisional prosthesis was delivered in the first 48 hours postop-

eratively, and the definitive restoration was placed 6 months after surgery. The cumulative success rate using that immediate loading protocol was 99.4%, with a mean loading period of 29 months (range, 12 to 60 months). In comparison, the concept of immediate loading used in the present study was similar. Thus, the high success rate achieved in the present study was similar to results achieved in nonsmokers. These data are also in accordance with observations in other nonsmokers or occasional smokers.^{16–20}

The present paper showed that only 6 implants with a high primary stability and a progressive thread design are adequate for the restoration of edentulous arches in heavy smokers. The implants were loaded immediately after surgery using fixed restorations with symmetric occlusal contacts the day of surgery (ie, immediate functional/occlusal loading). Excellent splinting of the immediately loaded implants is necessary to avoid excessive movement at the bone-implant interface.

Because of the high stability of this implant system, only 6 implants were necessary per arch, compared with the use of 10 to 12 implants with different surfaces and designs in other studies.^{15,20} In the present study sample, most dimensions were a length of 14 mm with a diameter of 3.5 mm. A previous clinical retrospective study demonstrated a high success rate for single-tooth implants with implants of this design and these dimensions.³³

The literature conclusively demonstrates that the immediate loading protocol has promising results, if some requirements are considered. A soft diet was advised in the present study for the first 6 to 8 weeks of loading, especially in cases where the bone quality was very poor or augmentative procedures were performed simultaneously. The soft-diet protocol has also been recommended elsewhere.^{15,17,22,23} Rigid immobilization of the immediately loaded implants using a cross-arch restoration to control micromotion, which may jeopardize the osseointegration, is also important. Some authors recommend the use of

screw-retained restorations with immediate loading concepts for easy removal without extensive pull-out forces.¹⁶

Tarnow et al¹⁶ placed 69 implants with different screw designs in 10 consecutive patients and loaded them immediately. Only 2 failures were reported in areas with poor bone quality, specifically in the posterior part of the mandible, representing an overall success rate of 97.10%, which is higher than the success rate achieved by Balshi and Wolfinger¹⁵ (80%) in a similar study in the mandible. In a previous study, the present authors used different thread geometries with a randomized split-mouth protocol in 12 consecutive patients and achieved a 100% success rate after 2 years of loading in the posterior part of the mandible.²³

Furthermore, the soft tissue around immediately loaded implants (with a progressive thread design and platform switching) was examined in monkeys, and the quality of the soft tissue observed was comparable to that observed with delayed loaded implants.³⁴ The design of the abutment may influence positively the peri-implant soft tissue stability,³⁵ allowing a horizontal instead of vertical component (biological width). The shape of the abutment collar compared to the implant top is probably important for the integrity of the supracrestal gingival fibers and their adherence to the abutment surface. This was also observed in the present clinical study, which showed clinical values for the peri-implant indices representing healthy soft tissue conditions. There is no doubt that plaque control is of importance to achieve healthy peri-implant soft tissue conditions. Furthermore, the abutments, which are placed in their final position during surgery, may be responsible for connective tissue stability and not the apical migration of the epithelium, which takes place with the disconnection of the abutment.³⁶

CONCLUSIONS

Based on the limitations of these consecutive case reports, immediate loading in edentulous arches of heavy smokers seems to be successful when the implant primary stability is high, full-arch splinting is secure, and initial forces are minimized using a soft diet. It also may be concluded that the risk of microbial penetration and peri-implant inflammatory reaction may be reduced if the abutments are not removed for the entire loading period and there is a precise implant-abutment connection.

REFERENCES

1. Widmark G, Andersson B, Carlsson GE, Lindvall AM, Ivanoff CJ. Rehabilitation of patients with severely resorbed maxillae by means of implants with or without bone grafts: A 3- to 5-year follow-up clinical report. *Int J Oral Maxillofac Implants* 2001;16:73–79.
2. Bain CA, Moy PK. The association between failure of dental implants and cigarette smoking. *Int J Oral Maxillofac Implants* 1993;8:609–615.
3. Bain CA, Moy PK. The influence of smoking on bone quality and implant failure. Presented at the 9th Annual Meeting of the Academy of Osseointegration, March 3–5, 1994, Orlando, FL.
4. De Bruyn H, Collaert B. The effects of smoking on early implant failure. *Clin Oral Implants Res* 1994;5:260–264.
5. Lemons JE, Laskin DM, Roberts WE, Tarnow DP. Changes in patient screening for a clinical study of dental implants after increased awareness of tobacco use as a risk factor. *J Oral Maxillofac Surg* 1997;55(suppl 5):72–75.
6. Wallace RH. The relationship between cigarette smoking and dental implant failure. *Eur J Prosthet Restorative Dent* 2000;8:103–106.
7. Lindquist LW, Carlsson GE, Jemt J. Association between marginal bone loss around osseointegrated mandibular implants and smoking habits: A 10-year follow-up study. *J Dent Res* 1997;76:1167–1674.
8. Kan JYK, Rungcharassaeng K, Lozada JL, Goodacre CJ. Effects of smoking on implant success in grafted maxillary sinuses. *J Prosthet Dent* 1999;82:307–311.
9. Keller EE, Tolman DE, Eckert SE. Maxillary antral-nasal inlay autogenous bone graft reconstruction of compromised maxilla: A 12-year retrospective study. *Int J Oral Maxillofac Implants* 1999;14:707–721.
10. Jones JK, Triplett RG. The relationship of cigarette smoking to impaired intraoral wound healing: A review of evidence and implications for patient care. *J Oral Maxillofac Surg* 1992;50:237–239.
11. Larcos G. Predicting clinical discordance of bone mineral density. *Mayo Clin Proc* 1998;73:824–828.
12. Babbush CA, Kent JN, Misiek DJ. Titanium plasma-sprayed (TPS) screw implants for the reconstruction of the edentulous mandible. *J Oral Maxillofac Surg* 1986;44:274–282.
13. Ledermann PD. Über 20jährige Erfahrung mit der sofortigen funktionellen Belastung von Implantatstegen in der Regio interforaminalis. *Z Zahnärztl Implantol* 1996;12:123–136.
14. Chiapasco M, Gatti C, Rossi E, Haefliger W, Markwalder TH. Implant-retained mandibular overdentures with immediate loading. A retrospective multicenter study on 226 consecutive cases. *Clin Oral Implants Res* 1997;8:48–57.
15. Balshi TJ, Wolfinger GJ. Immediate loading of Brånemark implants in edentulous mandibles: A preliminary report. *Implant Dent* 1997;6:83–88.
16. Tarnow DP, Emtiaz S, Classi A. Immediate loading of threaded implants at stage 1 surgery in edentulous arches: Ten consecutive case reports with 1- to 5-year data. *Int J Oral Maxillofac Implants* 1997;12:319–324.
17. Horiuchi K, Uchida H, Yamamoto K, Sugimura M. Immediate loading of Brånemark system implants following placement in edentulous patients: A clinical report. *Int J Oral Maxillofac Implants* 2000;15:824–830.
18. Randow K, Ericsson I, Nilner K, Petersson A, Glantz P-O. Immediate functional loading of Brånemark dental implants. An 18-month clinical follow-up study. *Clin Oral Implants Res* 1999;10:8–15.

19. Ganeles J, Rosenberg MM, Holt RL, Reichman LH. Immediate loading of implants with fixed restorations in the completely edentulous mandible: Report of 27 patients from a private practice. *Int J Oral Maxillofac Implants* 2001;16:418–426.
20. Degidi M, Piattelli A. Immediate functional and non-functional loading of dental implants: A 2- to 60-month follow-up study of 646 titanium implants. *J Periodontol* 2003;74:225–241.
21. Testori T, Meltzer A, Del Fabbro M, et al. Immediate occlusal loading of Osseotite implants in the lower edentulous jaw. A multicenter prospective study. *Clin Oral Implants Res* 2004;15:278–284.
22. Romanos GE. *Immediate Loading in the Posterior Mandible. Animal and Clinical Studies*. Berlin: Quintessenz, 2005.
23. Romanos GE, Nentwig GH. Immediate vs. delayed loading of implants in the posterior mandible. A 2-year prospective clinical study of 12 consecutive cases. *Int J Periodontics Restorative Dent* 2006;26:459–269.
24. Albrektsson T, Zarb G, Worthington P, Eriksson AR. The long-term efficacy of currently used dental implants: A review and proposed criteria for success. *Int J Oral Maxillofac Implants* 1986;1:11–25.
25. Romanos GE, Toh CG, Siar CH, Swaminathan D, Ong AH. Histological and histomorphometrical implant bone subjected to immediate loading. An experimental study with *Macaca fascicularis*. *Int J Oral Maxillofac Implants* 2002;17:44–51.
26. Rivera-Hidalgo F. Smoking and periodontal disease. *Periodontology* 2000 2003;32:50–58.
27. Bergström J, Eliasson S, Dock J. A 10-year prospective study of tobacco smoking and periodontal health. *J Periodontol* 2000;71:1338–1347.
28. Wilson TG, Nunn M. The relationship between the interleukin-1 periodontal genotype and implant loss. Initial data. *J Periodontol* 1999;70:724–729.
29. Haas R, Haimbock W, Mailath G, Watzek G. The relationship of smoking on peri-implant tissue: A retrospective study. *J Prosthet Dent* 1996;76:592–596.
30. Chow J, Hui E, Liu J. The Hong Kong bridge protocol. Immediate loading of mandibular Brånemark fixtures using a fixed provisional prosthesis: preliminary results. *Clin Implant Dent Relat Res* 2001;3:166–174.
31. Schnitman PA, Wohrle PS, Rubenstein JE, Da Silva JD, Wang NH. Ten-year results for Brånemark implants immediately loaded with fixed prostheses at implant placement. *Int J Oral Maxillofac Implants* 1997;12:495–503.
32. Jaffin RA, Kumar A, Berman CL. Immediate loading of implants in partially and fully edentulous jaws: A series of 27 case reports. *J Periodontol* 2000;71:833–838.
33. Romanos GE, Nentwig GH. Single molar replacement with a progressive thread designed implant System. A retrospective clinical report. *Int J Oral Maxillofac Implants* 2000;15:831–836.
34. Siar CH, Toh CH, Romanos GE, et al. Periimplant soft tissue integration of immediately loaded implants in the posterior macaque mandible: A histomorphometric study. *J Periodontol* 2003;74:571–578.
35. Tenenbaum H, Schhaf J-F, Cuisinier JG. Histological analysis of the Ankylos peri-implant soft tissues in a dog model. *Implant Dent* 2003;12:259–265.
36. Abrahamsson I, Berglundh T, Lindhe J. The mucosal barrier following abutment dis/reconnection. An experimental study in dogs. *J Clin Periodontol* 1997;24:568–572.