

# Morbidity of Mandibular Bone Harvesting: A Comparative Study

Gerry M. Raghoobar, DMD, MD, PhD<sup>1</sup>/Leo Meijndert, DMD<sup>2</sup>/Wouter W. I. Kalk, DMD, MD, PhD<sup>3</sup>/  
Arjan Vissink DMD, MD, PhD<sup>4</sup>

**Purpose:** To assess the objective and subjective morbidity of mandibular bone harvesting. **Materials and Methods:** Forty-five patients who had been subjected to mandibular bone harvesting from the chin region (group 1, n = 15), the retromolar region (group 2, n = 15), or the retromolar region after removal of the third molar (group 3, n = 15) participated in this study. Complications, postoperative morbidity, and patient acceptance of the procedure were evaluated by assessing the medical records and performing standardized routine clinical and radiographic examinations up to 12 months after the augmentation procedure. In addition, the patients were asked to complete a questionnaire on the subjective complaints related to the procedure. **Results:** Analysis of the questionnaire revealed that there was no significant difference between patients of groups 1 and 2 regarding acceptance of the procedure (scores of  $8.6 \pm 1.1$  and  $8.5 \pm 0.9$  on a 10-point scale, respectively). Acceptance of the procedure was scored significantly higher by the patients of group 3 ( $9.3 \pm 0.7$ ; Student t test,  $P < .05$ ). Six patients of group 1 and 2 patients of groups 2 and 3 reported subjective sensory disturbances related to the donor site. With the exception of 2 patients in group 1, these subjective complaints disappeared within 2 months after surgery. In the 2 patients (group 1) who reported a persistent discrete sensibility disorder in the symphyseal region after 12 months, this disturbance could not be confirmed objectively. **Conclusion:** Mandibular bone harvesting for reconstructing local alveolar defects is a well-accepted procedure with low objective and subjective morbidity. Amongst the procedures evaluated, harvesting bone from the retromolar region combined with removal of the third molar was best accepted by the patients. INT J ORAL MAXILLOFAC IMPLANTS 2007;22:359–365

**Key words:** autologous bone grafts, bone augmentation, endosseous implants, mandible, morbidity

In some patients implant treatment would not be possible without bone augmentation because of

insufficient bone volume at the planned implant site. A variety of materials and surgical techniques have been proposed to create sufficient bone volume at the implantation site. These techniques include the use of alloplastic materials such as tricalcium phosphate, allografts such as demineralized freeze-dried bone, autologous bone grafts, and/or membrane techniques.<sup>1</sup> Although the usefulness of alloplastic and allogeneic materials in the reconstruction of alveolar defects has been demonstrated, autologous bone grafts still provide the most rapid and predictable results in terms of resultant bone quality and quantity.<sup>1</sup> Therefore, autologous bone grafts are still considered the gold standard for augmentation of deficient alveolar ridges and are still subject of many clinical investigations.<sup>2</sup> The biologic compatibility of autologous bone grafts is a clear advantage of the material. These grafts provide a scaffold into which new bone may grow.

Various donor sites for autologous grafts are available to the surgeon, including the anterior and pos-

<sup>1</sup>Professor, Department of Oral and Maxillofacial Surgery, University Medical Center Groningen, University of Groningen, The Netherlands.

<sup>2</sup>Assistant Professor, Department of Oral and Maxillofacial Surgery, University Medical Center Groningen, University of Groningen, The Netherlands.

<sup>3</sup>Assistant Professor, Department of Oral and Maxillofacial Surgery, University Medical Center Groningen, University of Groningen, The Netherlands.

<sup>4</sup>Professor, Department of Oral and Maxillofacial Surgery, University Medical Center Groningen, University of Groningen, The Netherlands.

**Correspondence to:** Dr G. M. Raghoobar, Department of Oral and Maxillofacial Surgery, University Medical Center Groningen, University of Groningen, P.O. Box 30.001, 9700 RB Groningen, The Netherlands. Fax: +31 50 3611161. E-mail: g.m.raghoobar@kchir.umcg.nl

terior iliac crest, calvaria, tibia, ribs, and intraoral sites (maxilla, mandible, zygoma).<sup>3</sup> The choice of the donor site is based on the type and quantity of bone required, the access to the donor site, difficulty of access, time required with regard to harvesting procedure, and cost.<sup>2,4,5</sup> The mandibular symphysis is a favorable donor site because it is generally assumed that it has an excellent risk-benefit ratio.<sup>3</sup> Access is excellent, the type and quantity of bone obtainable is in most cases sufficient for augmentation of up to 3 tooth alveolar segments, the operating time is short, and the bone can be harvested on an outpatient basis using local anesthetics with or without sedation. The successful use of chin bone grafts has been reported in the literature.<sup>6-8</sup> These arguments seem to point to chin bone as the graft of choice.

All of these harvesting techniques require surgery at 2 sites, the donor site and the acceptor site; therefore, the morbidity of the various donor sites must be considered. Of the many possible sites, each has its own merits and disadvantages. Despite the common use of chin bone grafts, surprisingly little data on the morbidity at this donor site are available.<sup>5,9-12</sup> Clavero and Lundgren compared the morbidity and complications of autologous bone harvesting from the mandibular symphysis and the mandibular ramus.<sup>11</sup> Their results favored the use of the ascending mandibular ramus as an intraoral donor site. Moreover, harvesting of retromolar bone can occasionally be combined with removal of the third molar, which may affect acceptance of the procedure by patients.<sup>13</sup> Therefore, the aim of this study was to assess objectively and subjectively donor site morbidity following harvesting of chin bone grafts and retromolar bone with and without removal of the third molar. The bone grafts were used to augment localized defects of the anterior maxilla in adult patients.

## MATERIALS AND METHODS

Forty-five consecutive patients who had at least 1 remaining mandibular third molar and needed preimplant placement augmentation of a local bone defect of the anterior maxilla with an intraoral bone graft were asked to participate in this study. None of the patients suffered from complaints related to presence of a third molar. All patients were willing to participate. Informed consent was obtained from all patients.

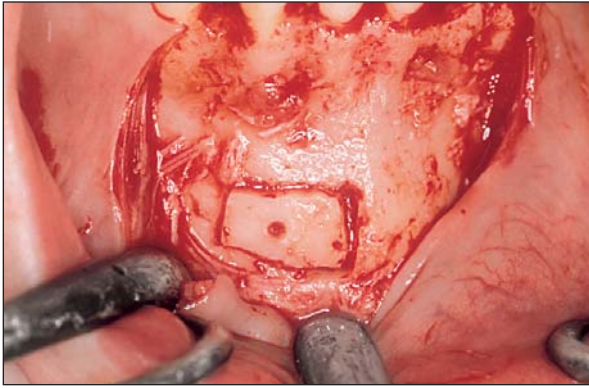
All patients were treated at the Department of Oral and Maxillofacial Surgery of the University Medical Center Groningen between January 2001 and June 2004. The bone was harvested from the chin

region (group 1,  $n = 15$ ), the retromolar region (group 2,  $n = 15$ ), or the retromolar bone in combination with removal of the third molar (group 3,  $n = 15$ ). As none of the patients suffered from complaints related to presence of a third molar, patients were included in the various groups by chance, although patients with 2 third molars were ineligible for group 2, and patients with functional third molars were ineligible for group 3. If such an exclusion criterion applied, the patients were included by chance in 1 of the other 2 groups. The same surgeon (GMR) performed all of the operations. Orthopantomograms and periapical radiographs were used to map the course of the inferior alveolar canal and to assess the donor and recipient sites.

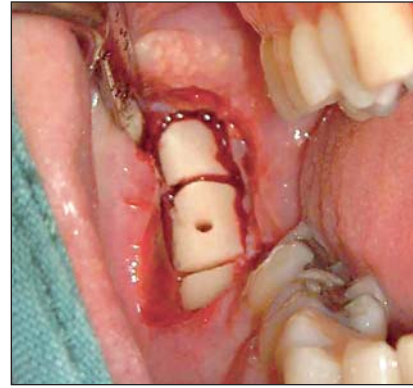
All 45 patients were treated under local anesthesia. The recipient site for the graft was exposed prior to graft harvesting in all cases. In this manner, the dimensions and morphology of the bony defect could be assessed, and minimal time elapsed between graft harvest and placement. The recipient site was exposed by placing incisions slightly distant from the residual ridge crest on the palatal side and in the sulcus of the neighboring teeth. Divergent releasing incisions remote from the defect were used to facilitate closure and maintain blood supply. The recipient site was perforated with a small round bur and recontoured if necessary to improve bone-to-graft contact. The periosteum at the base of the flap was carefully incised to allow stretching of the mucosa and tension-free adaptation of the wound margins. Subsequently, the harvesting procedure selected for that patient was applied.

### Symphysis Graft Harvesting

The chin area was exposed by a crevicular incision around the necks of the teeth and a vertical releasing incision in the canine region. In both cases a full-thickness mucosal flap was raised. Subsequently, the dimension of the graft was determined considering the size of the bone defect at the implantation site. A 5-mm safety margin was allowed inferior to the apices and superior to the lower border of the mandible. An osteotomy was performed using a small fissure bur in a surgical handpiece under copious irrigation with saline. A hole was made in the graft for fixation with a screw at the receptor site (Fig 1). In all cases the procedure could be limited to monocortical bone grafts, leaving the lingual cortex intact. After removal of the corticocancellous bone block with a bone chisel, additional bone was harvested with curettes from the caudal site. The harvested bone was preserved in a cold saline solution (4°C). Bone volumes of 1 to 3 cm<sup>3</sup> were harvested. In all cases the volume of the bone grafts was sufficient



**Fig 1** Harvesting of a mandibular chin bone graft. The block graft was outlined with a fissure bur, and a gliding hole was prepared to fix the graft in the receptor area.

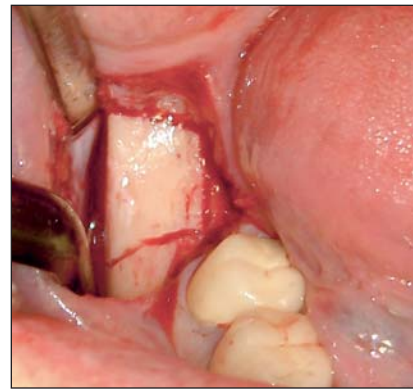


**Fig 2** Harvesting of autologous bone in the retromolar region.

to augment the local bone defect in the anterior maxilla. Prior to soft tissue closure of the mandibular donor site, the area was copiously irrigated and inspected. Sharp osseous edges and irregularities were reduced to minimize postoperative discomfort. A gelatin sponge was applied in the donor area as a hemostatic dressing. The wound was closed with Vicryl (Ethicon/Johnson & Johnson, Somerville, NJ). An extraoral pressure dressing (elastic tape) was applied to the chin and maintained for 4 days to minimize postoperative swelling and formation of a hematoma.

### Ramus Graft Harvesting

The concavity formed by the border between the ascending ramus and the external oblique ridge was identified and used as a starting point for mucosal incision. The incision was made medial to the external oblique ridge in an anterior direction and terminated in the first molar area to avoid interference with the mental nerve branches. A mucoperiosteal flap was raised, and the exposed bone area was evaluated in terms of the amount of bone needed at the implant site. The margins of the bone block to be harvested were outlined by holes drilled through the cortex with a small round bur. A safety margin of 4 mm superior to inferior alveolar nerve was respected. A microreciprocating saw was used to make the osteotomies. After completing all osteotomies (Fig 2), the mandibular bone was fractured off with the aid of chisels. The bone block was carefully lifted to ensure that the inferior alveolar nerve was not trapped within the graft. Prior to soft tissue closure of the mandibular donor site, the area was cleansed with a copious amount of saline and carefully inspected. Sharp osseous edges and irregularities were trimmed with chisels or by using a large bur. The flap was repositioned and closed with Vicryl.



**Fig 3** Harvesting of a mandibular bone graft in combination with removal of an impacted third molar.

### Ramus Graft Harvesting in Combination with Removal of a Mandibular Third Molar

In the case of third molar removal during the same procedure as ramus graft harvesting, a second-molar sulcus incision flap with buccal extension was made (4 third molars were partially erupted, 11 third molars were completely covered with bone). The margins of the blocks of the bone to be harvested were outlined by holes drilled through the cortex with a small round bur (Fig 3). The microreciprocating saw was used to make the osteotomies. At the level of the third molar, the osteotomies extended into the socket. After completing all osteotomies, the mandibular bone was fractured off with the aid of chisels, and the bone block was removed. Subsequently, the third molar was removed, in most cases without tooth sectioning ( $n = 11$ ). In 4 patients, because of the horizontal and distoangulation position, the third molar was sectioned before removal. Prior to soft tissue closure of the mandibular donor site, the area was cleansed with a copious amount of

saline and carefully inspected. Sharp osseous edges and irregularities were trimmed with chisels or by using a large bur. The flap was repositioned and closed with Vicryl.

After harvesting, the autologous block grafts were fixed with titanium screws (diameter 1.5 mm, Martin Medizin Technik, Tuttlingen, Germany) to the alveolar bone at the planned implant site. Particulated bone was placed around the fixed block graft. The bone grafts were covered by a Bio-Gide GBR membrane (Geistlich, Wolhusen, Switzerland). The membrane was shaped with a 3-mm extension over the bone margins of the defect, and the wound was sutured with Vicryl. Removable soft tissue-supported prostheses were generously adjusted and relined with tissue conditioner. Patients were instructed to use their prostheses for cosmetic appearance rather than for function. All patients received broad-spectrum antibiotics (amoxicillin) for 48 hours and chlorhexidine 0.2% mouth rinse for 2 weeks. The grafted sites were allowed to heal for at least 3 months (mean,  $3.3 \pm 0.3$  months; range, 3 to 4 months).

Routine clinical examinations were performed at 2 weeks, 6 weeks, and 3, 9, and 12 months after surgery. At these examinations, patients were asked about preoperative and postoperative complications and pain at the donor site. In addition, the long-term morbidity of the donor site was assessed by completing a questionnaire and a thorough, standardized clinical examination 12 months after surgery.

The questionnaire consisted of multiple-choice questions about the duration and severity of postoperative pain at the donor site, meteorotropism (weather-dependent discomfort), sensory loss, duration of rehabilitation, postoperative symptoms at the donor and recipient sites, and the patient's acceptance of the procedure. Pain severity was graded on a 10-cm visual analog scale (VAS; 0 representing no pain, 10 representing severe pain). To estimate the subjective acceptability of the bone harvesting, the patients were requested to judge the procedure using a number between 0 and 10, with 0 indicating "a very bad experience" and 10 "no problems at all."

The clinical examination was restricted to the donor site area and included the contour of the chin and sensibility of the chin and lower lip. Tactile sensibility was tested by lightly brushing the skin with a wisp of cotton (the subject should be able to count the number of contacts with the eyes closed). Superficial pain was tested with a needle (the subject should be able to tell whether contact with the skin was made with a sharp or dull instrument with the eyes closed). Patients were asked whether they experienced altered sensation in the mucosa and skin region innervated by the mental nerve. Patient

reporting of a diminished sensation without discomfort was recorded as hypoesthesia. Patient reporting of an altered quality of sensation that included discomfort was recorded as dysesthesia. Reporting of the complete absence of sensation was recorded as anesthesia. In addition, the response of the anterior teeth to cold sensation was tested using a spherical dental cotton on which an ethyl chloride vapor was sprayed.

Radiographic examination 12 months after surgery comprised intraoral radiographs of the chin region and orthopantomograms. The presence of periapical pathology, pulp canal obliteration, and root resorption were recorded. The criteria for the diagnosis of pulp necrosis were a combination of loss of pulp sensibility, measured thermally, and periapical radiolucency. The ingrowth of bone into the donor defect was evaluated on orthopantomograms.

### Statistical Analysis

Data were submitted for statistical analysis using Statistical Package for Social Sciences (SPSS, Chicago, IL) version 9.0 for the statistical procedures. These procedures included independent sample *t* tests and a linear regression analysis. Statistical testing was considered significant when  $P < .05$ .

## RESULTS

### Clinical Examination

The group of patients included in this study comprised 17 men and 28 women (mean age,  $29 \pm 7$  years, range, 18 to 51 years). No complications were observed during the surgical procedure. No extensive bleeding after removal of the bone graft and third molar was encountered. Exposure of the inferior alveolar nerve did not occur. There was no infection or bone graft exposure in any group. In 1 patient, in whom a third molar was removed, delayed socket healing was noted. The alveolus was thoroughly irrigated with saline, and healing was uneventful after 1 week.

Prolonged postoperative pain (> 1 week) at the donor site was experienced by 11 patients (5 in group 1, 3 in group 2, 3 in group 3). In all 11 patients the pain lasted less than a month. Transient hypoesthesia of the labial gingiva was observed in 1 patient (group 1) during the first 4 weeks postsurgery. Two patients (group 1) described an altered sensation in the incisors postoperatively, although the teeth showed vital pulp response to cold. All complaints spontaneously resolved within 6 months. Examination of the periodontal status revealed neither gingival retraction nor periodontal pockets.

In all cases there was enough bone for reliable placement of the implants. In 4 cases (3 in group 1 and 1 in group 2) additional bone grafting was needed after placement of the implants because of dehiscence of the implant. The bone to cover the dehiscence was collected during preparation of the osteotomy for implant placement as well as from the adjacent alveolar process. After the osseointegration period 1 implant was lost (group 2). After 3 months this implant was replaced without any complications. No other implant was lost during the follow-up period.

The soft tissue profile of the chin remained unchanged, and function of the lower lip was completely restored.

### Sensibility of the Donor Region

Objectively, no disturbed sensibility of the oral mucosa and skin innervated by the mental nerve was observed in any patient at 12 months after surgery. Also, the results of the vitality test of the mandibular incisors did not differ from results obtained prior to surgery. The crevicular incision resulted in an almost invisible scar.

### Questionnaire

Thirty-two patients (7 from group 1, 12 from group 2, and 13 from group 3) stated that the postoperative course was in accordance with their expectations, 5 patients (4 from group 1, 1 from group 3) stated that the postoperative course was better than expected, and 8 patients (4 from group 1, 3 from group 2, 1 from group 3) suffered more than expected. No significant differences were observed between the 3 groups with regard to the severity of postoperative pain (VAS; between 4.8 and 5.0) (Student *t* test,  $P > .05$ ). With regard to the origin of the pain, 19 patients (7 from group 1, 6 from group 2, 6 from group 3) experienced more pain at the receptor site, 11 patients (4 from group 1, 4 from group 2, 3 from group 3) experienced more pain at the donor site, while 15 patients (4 from group 1, 5 from group 2, 6 from group 3) experienced the pain as comparable at both regions.

Overall the subjective acceptability of the procedure was rated as very satisfactory in all groups. Acceptance was rated equally in groups 1 and 2 ( $8.6 \pm 1.1$  and  $8.5 \pm 0.9$  on a 10-point scale, respectively) and significantly higher by the patients of group 3 ( $9.3 \pm 0.7$ ; Student *t* test,  $P < .05$ ). All patients stated that they would be willing to repeat the procedure when necessary. The patient's age and pain level both had a significant negative influence on the patient's judgment of the bone harvesting procedure (linear regression analysis,  $\beta$  of  $-.6$  and  $-6.2$  for

age and pain, respectively;  $R = 0.62$ ). There was no significant negative relation between the patient's judgment of the procedure and gender, chronic pain, the time needed for full recovery as experienced by the patients, or the occurrence of postoperative complications.

Six patients (group 1, 40%) reported paresthesia in the chin region postsurgery, which could not be confirmed objectively by the tests applied. In 4 patients this symptom had disappeared after 2 months, but in 2 patients the complaints were still present at the final examination 1 year postsurgery. One of these 2 patients reported also meteorotropism in the chin region. The patients who still experienced a reduced sensibility of the chin all stated that the changed sensibility did not cause noteworthy complaints or discomfort. It was merely a phenomenon that was remembered and reported by the patients because they were asked about it. None of the patients felt that the contour of the mandible was changed. Two patients reported paresthesia after harvesting of retromolar bone (1 in group 2 and 1 in group 3). These symptoms had disappeared after 2 months.

### Radiographic Examination

No bony defects were observed radiographically at the donor site 1 year after surgery, the radiographic image of the bone at the donor site resembled that of the surrounding native bone in all cases. No periapical pathology of the incisors or second molars had developed in the donor region. The bone in the ramus region appeared to have healed.

## DISCUSSION

The present study was an investigation of the donor site morbidity and complication rate of onlay grafting with 3 different bone harvesting procedures. The morbidity and complication rate were low for all procedures. When compared to chin bone harvesting, harvesting from the retromolar region resulted in significantly lower acceptance when the third molar was removed as part of the procedure. The low (subjective) morbidity may be related to the patient's anticipation of pain and discomfort associated with third molar removal.

Mandibular bone grafts have been used for alveolar repair to allow implant placement, with highly favorable results. The obvious advantage of symphyseal bone grafts is their convenient surgical access. This proximity of donor and recipient sites reduces the time needed for anesthesia and surgical treatment. Although the procedure generally is consid-

ered well-accepted, with relatively low morbidity, patient satisfaction has never been investigated. As shown in this study, the average judgment of the procedure was moderate. Surprisingly, 40% of the patients experienced a slight postsurgical paresthesia in the chin region. This paresthesia could not be confirmed with objective tests and disappeared within 2 months in most cases. This paresthesia, as experienced by the patients, probably resulted from neuropraxia of the incisive nerve or the end branches of the mental nerve, which spontaneously recovers in most patients. These data are in agreement with the observations of other authors, who had previously reported that disturbed sensibility of the lip and chin following bone harvesting can occur.<sup>4,5,14</sup> Such disturbances usually recover spontaneously<sup>7</sup> but may persist in up to a third of patients.<sup>9,10</sup> Moreover, an altered sensation of the mandibular teeth is even a common temporary postoperative symptom.<sup>8</sup> Based on these and other reports, Nkenke et al strongly advised that patients be informed extensively about the possibility of disturbance of the inferior alveolar function.<sup>10</sup>

Conversely, paresthesia resulting from bone harvesting from the retromolar region had resolved within 2 months after surgery in all cases. When compared to chin bone grafts, the major disadvantage of retromolar grafts is that only a confined amount of bone can be harvested from the donor site.<sup>15</sup> The volume is about half of what can be obtained from the chin region<sup>5</sup>; furthermore, bone from the ramus is more cortical.<sup>5</sup> The limits of the ramus bone are dictated by clinical access. The amount of bone that can be harvested from the retromolar area can be increased by including the mandibular body as a donor site, although with a risk of temporary sensory disturbance.<sup>16</sup> The dense structure of the cortical portion of the graft offers the benefit of improved implant stability during placement and healing and may even improve interfacial stress transmission on implant loading.<sup>8</sup>

Although the morbidity resulting from mandibular bone harvesting was low, the patients experienced the procedure as severe. The average postoperative pain severity was 4.7 (out of a maximum of 10); in comparison, a study using similar instruments for evaluation of morbidity from iliac crest bone harvesting yielded a significantly lower postoperative pain severity of 2.2.<sup>17</sup> The reason for this remarkable difference could be that harvesting of iliac crest bone took place under general anesthesia, followed by postoperative hospitalization and professional administration of adequate pain medication. Patients treated under general anesthesia do not experience the procedure itself and probably expect

less severe complaints or accept postoperative pain as a normal response more easily. In contrast, the patients treated under local anesthesia experience much of the procedure and are self-supporting for their pain medication. This phenomenon is all the more striking because operating exclusively intraorally is generally considered by patients as less extensive surgery when compared to additional iliac crest bone harvesting.<sup>18</sup> A second reason that greater pain was reported for chin bone harvesting is that following chin bone harvesting pain and swelling occur in the same region (oral cavity) where the grafting procedure was performed. The aforementioned differences between the procedures may also explain the better subjective acceptability of harvesting retromolar bone and removal of the third molar, which, amongst others, might be related to the patient's ability to cope with surgical interventions and the pain and discomfort expected following such surgery. For example, most patients are well aware that removal of the third molar is associated with postoperative complaints and thus expect a certain level of discomfort.

As reported in other studies, no postoperative alteration in chin contour was noted, although patients are often concerned about esthetic consequences of bone removal in this area.<sup>2,8,14,19</sup> No postoperative alteration in chin contour was observed in the present study either clinically or radiographically. Radiographic evidence of incomplete bony regeneration has been reported in elderly patients.<sup>7</sup> However, the reported incomplete bone fill of the donor region did not result in any discernible profile changes. Ptosis of the chin did not occur and can be prevented by avoiding complete degloving of the mandible.<sup>20</sup> In this study the surgeon tried to avoid complete degloving of the mentalis muscle to prevent chin ptosis and labial mental fold irregularities. Radiographically, complete healing of the donor site usually occurs within 6 months.<sup>19</sup>

## CONCLUSION

Advantages of the retromolar donor site over the chin include minimal patient concern for altered facial contour and decreased complaints of discomfort (fewer problems during eating and with speech). Given the better acceptance by patients and the moderate level of subjective complaints, bone harvesting from the retromolar region is the best option for reconstruction of local bone defects, especially when combined with removal of the third molar. However, this conclusion was mainly based on the outcome of a 12-month postsurgery questionnaire.

Thus, additional studies are needed to assess whether earlier assessment of the subjective experiences of patients will yield similar results. In addition, if the chin is used as a donor region, the patients must be informed about the risk of (subjective) sensory disturbance in the donor region. Currently, autologous bone is still superior to bone substitutes in regard to biocompatibility and osteoconductivity. In the future, improvements in the application of allogeneic bone grafts, bone substitutes with or without morphogenetic proteins, and/or cultured bone grafts, may alter this situation and reduce the morbidity resulting from harvesting of intraoral bone grafts.

## REFERENCES

- Garg AK. Grafting materials in repair and restoration. In: Lynch SE, Genco RJ, Marx EX (eds). *Tissue Engineering. Applications in Maxillofacial Surgery and Periodontics*. Chicago: Quintessence, 1999:83–101.
- Raghoobar GM, Batenburg RHK, Vissink A, Reintsema H. Augmentation of localized defects of the anterior maxillary ridge with autogenous bone before insertion of implants. *J Oral Maxillofac Surg* 1996;54:1180–1185.
- Triplett RG, Sihow SR. Osseous regeneration with bone harvested from the anterior mandible. In: Nevins M, Mellonig JT (eds). *Implant Therapy. Clinical Approaches and Evidence of Success*. Chicago: Quintessence, 1998:209–217.
- Misch CM, Misch CE, Resnik RR, Ismail YH. Reconstruction of maxillary alveolar defects with mandibular symphysis grafts for dental implants: A preliminary procedural report. *Int J Oral Maxillofac Implants* 1992;7:360–366.
- Misch CM. Comparison of intraoral donor sites for onlay grafting prior to implant placement. *Int J Oral Maxillofac Implants* 1997;12:767–776.
- Koole R, Bosker H, Noorman van der Dussen MF. Late secondary autogenous bone grafting in cleft patients comparing mandibular (ectomesenchymal) and iliac crest (mesenchymal) grafts. *J Oral Maxillofac Surg* 1989;17:28–30.
- Jensen J, Sindet-Pedersen S. Autogenous mandibular bone grafts and osseointegrated implants for reconstruction of the severely atrophied maxilla: A preliminary report. *J Oral Maxillofac Surg* 1991;48:1277–1287.
- Misch CM, Misch CE. The repair of localized severe ridge defects for implant placement using mandibular bone grafts. *Implant Dent* 1995;4:261–267.
- Raghoobar GM, Louwse C, Kalk WWI, Vissink A. Morbidity of chin bone harvesting. *Clin Oral Implants Res* 2001;12:503–507.
- Nkenke E, Schultze-Mosgau S, Radespiel-Tröger M, Kloss F, Neukam FW. Morbidity of harvesting chin grafts: A prospective study. *Clin Oral Implants Res* 2001;12:495–502.
- Clavero J, Lundgren S. Ramus or chin grafts for maxillary sinus inlay and local onlay augmentation: Comparison of donor site morbidity and complications. *Clin Implant Dent Relat Res* 2003;5: 154–160.
- Joshi A. An investigation of post-operative morbidity following chin surgery. *Br Dent J* 2004;28:215–218.
- Misch CM. Harvesting of ramus bone in conjunction with third molar removal for onlay grafting before placement of dental implants. *J Oral Maxillofac Surg* 1999;57:1376–1379.
- Hoppenreijts TJM, Nijdam ES, Freihofer HPM. The chin as a donor site in early secondary osteoplasty: A retrospective clinical and radiographical evaluation. *J Craniomaxillofac Surg* 1992;20:119–124.
- Nkenke E, Radespiel-Tröger M, Wiltfang J, Schultze-Mosgau S, Winkler G, Neukam FW. Morbidity of harvesting retromolar bone grafts: A prospective study. *Clin Oral Implants Res* 2002;13:514–521.
- Vincente J, Stoelinga PJW. Toepassing van bottransplantaten uit het corpus mandibulae voor preimplantologische chirurgie. *Ned Tijdschr Tandheelkd* 2005;112:211–215.
- Kalk WWI, Raghoobar GM, Jansma J, Boering G. Morbidity from iliac crest bone harvesting. *J Oral Maxillofac Surg* 1996;54:1424–1429.
- Sindet-Pedersen S, Enemark H. Reconstruction of alveolar clefts with mandibular bone grafts or iliac crest bone grafts: A comparative study. *J Oral Maxillofac Surg* 1990;48:554–558.
- Sindet-Pedersen S, Enemark H. Mandibular bone grafts for reconstruction of alveolar clefts. *J Oral Maxillofac Surg* 1988;46:533–537.
- Rubens BC, West RA. Ptosis of chin and lip incompetence: Consequences of lost mentalis muscle support. *J Oral Maxillofac Surg* 1989;47:359–366.