

# Clinical Outcome of 802 Immediately Loaded 2-stage Submerged Implants with a New Grit-Blasted and Acid-Etched Surface: 12-month Follow-up

Marco Degidi, MD, DDS<sup>1</sup>/Adriano Piattelli, MD, DDS<sup>2</sup>/  
Peter Gehrke, DDS<sup>3</sup>/Francesco Carinci, MD, DDS<sup>4</sup>

**Purpose:** The aim of this study was to evaluate the clinical outcome of delayed or immediately loaded implants of 3 different implant macrodesigns. The hypothesis was that no significant differences in implant success would be observed between immediately and delayed loaded implants. **Materials and Methods:** Between July 2003 and December 2003, 321 patients were consecutively enrolled for this study. Immediate loading was performed in cases where the implant stability quotient (ISQ) values were > 60 (as determined by resonance frequency analysis) and implant insertion torque was > 25 Ncm. In the case of delayed loading, a submerged technique (2-stage) or a single-stage procedure was used. The following variables were statistically analyzed with logistic regression: implant length, implant diameter, implant type, implant site, insertion torque, ISQ, and type of loading (immediate or delayed). **Results:** Eight hundred two implants were placed. Immediate loading was chosen for 423 implants and delayed loading for 379 implants. All implants were followed up for a minimum of 12 months after prosthetic loading. Only 3 implants were lost, with an overall success rate of 99.6%. No statistically significant differences were found for any variables between the failures in the 2 groups (immediate loading protocol versus delayed loading). Implants with a crestal bone loss greater than 0.2 mm during the first year of observation (69 cases) were evaluated as a group; within this subset, only ISQ value ( $P < .004$ ), implant length ( $P < .002$ ), and implant type ( $P < .049$ ) had a statistically significant effect on crestal bone resorption. **Conclusions:** Based upon this study of 802 implants, no significant differences in implant success were observed between the 2 groups. (Comparative Cohort Study) *INT J ORAL MAXILLOFAC IMPLANTS* 2006;21:763–768

**Key words:** crestal bone loss, immediate loading, implant failures, implant surfaces

A number of factors related to the patient, surgical procedure, and implants may influence osseointegration, including such variables as implant macro- and microdesign.<sup>1</sup> Data from several in vivo animal studies<sup>2–7</sup> suggest that implants with surfaces roughened by grit-blasting and/or acid etching produce a more rapid bone response and/or more bone-to-implant contact than implants with smooth or turned

surfaces.<sup>8,9</sup> It is less clear how implant surface properties influence long-term survival of implants in humans. A study by Lemmerman and Lemmerman<sup>10</sup> of 1,003 (348 machined and 655 roughened) titanium implants placed between August 1987 and January 2002 showed no significant difference in implant survival relative to implant surface.

Enhanced bone adhesion to rougher implant surfaces in pull-out tests has been explained by the increase of surface area available for cell attachment.<sup>11,12</sup> Furthermore, several authors have investigated the possible effects of surface properties such as microroughness, chemistry, wettability, and surface topography in relation to osteoblast behavior, fibrin formation, and clot retention.<sup>11–18</sup>

Immediate loading of dental implants has been reported to be a predictable treatment option, with reduced treatment time and a reduced number of surgical interventions; the presence of mineralized tissues has been reported at the interface of immediately loaded implants.<sup>1,4</sup>

<sup>1</sup>Private Practice, Bologna, Italy; Visiting Professor, Dental School, University of Chieti-Pescara, Italy; Visiting Professor, Dental School, University of Bologna, Italy.

<sup>2</sup>Full Professor of Oral Pathology and Medicine, Dental School, University of Chieti-Pescara, Chieti, Italy.

<sup>3</sup>Private Practice, Ludwigshafen, Germany.

<sup>4</sup>Associate Professor of Maxillofacial Surgery, University of Ferrara, Italy.

**Correspondence to:** Prof Adriano Piattelli, Via F. Sciucchi 63, 66100 Chieti, Italy. Fax: +39 0871 3554076. E-mail: [apiattelli@unich.it](mailto:apiattelli@unich.it)

The aim of the present study was to evaluate the clinical outcomes of delayed and immediately loaded implants of 3 different implant macrodesigns with a new microstructured implant surface. The hypothesis was that no significant differences in implant success would be observed between immediately loaded implants and those subjected to a delayed loading protocol.

## MATERIALS AND METHODS

A retrospective study was performed by analyzing a series of patients consecutively treated between July 2003 and December 2003. Three hundred twenty-one patients were enrolled in this study. The study protocol was approved by the Ethics Committee of the University of Chieti-Pescara, and informed written consent was obtained from patients to use their data for research purposes. All the patients were treated in the private practice of one of the authors (MD).

Inclusion criteria were controlled oral hygiene, the absence of any lesions in the oral cavity, and sufficient residual bone volume to receive implants at least 3 mm in diameter and 8 mm in length. Immediate loading of the implants was performed when resonance frequency analysis (RFA) demonstrated an implant stability quotient (ISQ) of  $> 60$  and implant insertion torque was  $> 25$  Ncm.

Exclusion criteria were insufficient bone volume, a high degree of bruxism, smoking more than 20 cigarettes/d, excessive consumption of alcohol, localized radiation therapy of the oral cavity, antitumor chemotherapy, liver disease, kidney disease, blood disease, immunosuppression, corticosteroid treatment, pregnancy, inflammatory and autoimmune diseases of the oral cavity, and poor oral hygiene.

### Data Collection

Prior to surgery, each patient was evaluated by periapical radiographs, orthopantomographs, and computerized axial tomographic scans (CAT scans). Periapical radiographs were used during follow-up.

For each patient, peri-implant crestal bone levels were evaluated by calibrated examination of periapical radiographs. Measurements were recorded immediately after surgery and again at 6 and 12 months. These measurements were performed on the mesial and distal surfaces of each implant. The distance between the platform of the implant and the most coronal point of contact between the bone and the implant was calculated. A Peak scale loupe (GWJ, Hacienda Heights, CA) with a 7-fold magnifying factor and an 0.1 mm graded scale was used. All measurements were made by the same examiner (MD).

Implant success criteria were established as (1) absence of persisting pain or dysesthesia; (2) absence of peri-implant infection with suppuration; (3) absence of mobility; and (4) absence of peri-implant bone resorption greater than 1.5 mm during the first year of loading.<sup>19</sup>

### Surgical and Prosthetic Techniques

All patients underwent the same surgical protocol. Antimicrobial prophylaxis was obtained with 500 mg amoxicillin twice a day for 5 days, starting 1 hour before surgery. Local anesthesia was induced by infiltration with articaine/epinephrine.

After the crestal incision a mucoperiosteal flap was elevated. Implants were placed according to the specific implant procedures recommended. According to the manufacturer's recommendation, a crestal drill was used for crestal bone preparation in order to decrease the stress at the coronal part of the implant during placement. Occlusal contact was avoided in centric and lateral excursions whenever possible.

After placement of the provisional restoration, a periapical radiograph was taken by means of a customized Rinn holder device (Dentsply Rinn, York, PA). This device was necessary to maintain the x-ray cone perpendicular to a film placed parallel to the long axis of the implant. Postsurgical analgesic treatment was instituted for 3 days. Patients were restricted to a soft diet for 4 weeks, and oral hygiene instructions were provided. Sutures were removed 14 days after surgery.

The provisional restoration was removed 18 weeks after implant placement, and a final impression of the abutment was recorded using a polyvinyl siloxane impression material. The final restoration was cemented and delivered approximately 24 weeks after implant placement. All patients were included in a strict hygiene recall.

### Statistical Analysis

Logistic regression was used as a statistical tool to evaluate the independent contributors of the variables studied with regard to the outcome—lost implants plus implants with bone loss  $> 1.5$  mm during the first year (ie, 7 cases) in the first analysis, and bone loss  $> 0.2$  mm in a second evaluation (ie, 69 cases).<sup>20</sup> *P* was considered significant when  $< .05$ .

## RESULTS

Three hundred twenty-one patients (128 men and 193 women between the ages of 18 and 88) were enrolled in the study. A total of 802 implants were placed: 255 (31.8%) in men and 547 (68.2%) in

women. Of these, 583 were XiVE Plus implants (72.7%), 164 were Frialit Plus implants (20.4%), and 55 were XiVE Transgingival (TG) Plus implants (6.9%) (all Dentsply Friadent, Mannheim, Germany). Mean patient age was 49.5 years ([SD] 12.2). The distribution of implant diameters and lengths is reported in Table 1. Also the teeth that have been replaced were reported in Table 1. Four hundred twenty-three (52.7%) implants were immediately loaded, and 379 (47.3%) underwent a period of undisturbed healing. In the latter implants either a submerged (2-stage) or a single-stage technique was used (Figs 1 to 6). Torque was lower than 30 Ncm in 355 cases (44.3%), and ISQ was higher than 60 in 542 cases (of the 676 cases in which RFA was recorded). In cases of immediate loading, a temporary restoration was relined with acrylic resin, trimmed, polished, and cemented or screw-retained 1 to 2 hours after implant placement (same-day loading).

After 12 months of loading, only 3 of the 802 implants had failed, for an overall implant success rate of 99.6%. The mean crestal bone loss was 0.15 mm. Four implants had crestal peri-implant bone resorption greater than 1.5 mm during the first year.

Because the number of failures (3 lost implants plus 4 implants with more than 1.5 mm of bone resorption) was so small, there were no statistically significant differences between any of the evaluated factors with respect to implant failure.

Among the investigated variables, only ISQ value ( $P < .004$ ), implant length ( $P < .002$ ), and implant type ( $P < .046$ ) had a statistically significant effect on crestal bone resorption in the group of 69 implants with a mean crestal bone loss greater than 0.2 mm after 1 year of follow-up (Table 2). Among the different implant types, the XiVE TG Plus implants demonstrated the best results, with a mean crestal bone loss (MCBL) of 0.02 mm. Both XiVE Plus and Frialit Plus implants had an MCBL of 0.16 mm (Tables 3, 4, and 5).

## DISCUSSION

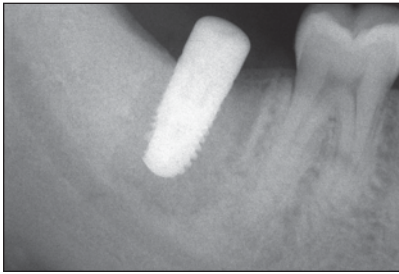
High implant survival and success rates have been reported for immediately loaded implants.<sup>22–35</sup> The presence of a high percentage of mineralized tissues at the bone-implant interface with immediately loaded implants in humans has been reported in the literature.<sup>36–43</sup> In this retrospective study, 802 implants with the same surface but different designs were evaluated. Three implants were lost, and 4 other implants showed a crestal bone loss greater than 1.5 mm during the first year of observation; no statistically significant differences were noted between the 2 groups when evaluating these 7 implants. It is likely that the

**Table 1 Implant Distribution According to Size and Location**

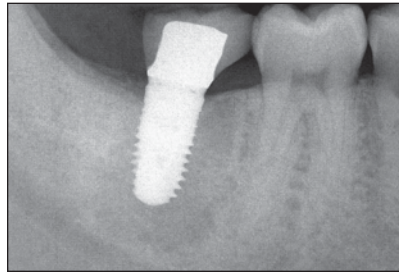
	Implants	
	n	%
Implant diameter (mm)		
3.0	124	15.5
3.4	122	15.2
3.8	258	32.2
4.5	197	24.6
5.5	99	12.3
6.5	2	0.2
Implant length (mm)		
8.0	40	5.0
9.5	37	4.6
10	34	4.2
11	210	26.2
13	189	23.6
15	288	35.9
18	4	0.5
Location		
Incisal site	140	17.5
Canine site	79	9.9
Premolar and molar sites	583	72.7

lack of statistically significant differences reflects the small number of failures rather than an absolute lack of difference in clinical performance. The MCBL in this series of implants was 0.15 mm (range, +0.9 to -2.0). Of the 69 implants with a bone loss greater than 0.2 mm, only the type of implant ( $P < .046$ ), ISQ value, ( $P < .004$ ) and implant length ( $P < .002$ ) showed statistically significant difference. Among the different implant types, the transgingival XiVE TG Plus implants demonstrated the best results. This difference could, however, be meaningless from a clinical point of view. It can be hypothesized that these results could be related to the macrodesign and to the level of the microgap with respect to the bone crest. In addition, there are different clinical indications for the 3 implant types used in this study. TG implants are mainly used for the rehabilitation of edentulous jaws with overdentures or when the patient's esthetic demands are low. XiVE Plus implants are the first choice in all clinical cases and especially in immediate loading procedures due to their high primary stability at the coronal end. Frialit Plus implants are primarily indicated in postextractive rehabilitations with immediate implant placement because of their tapered root-analog design.

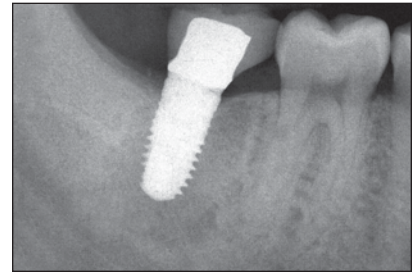
Implants with RFA values above 60 ISQ usually presented a higher stability (independent of the type of loading), probably because of higher bone quality and quantity. Glauser and colleagues<sup>44</sup> showed that failing implants presented decreasing stability until



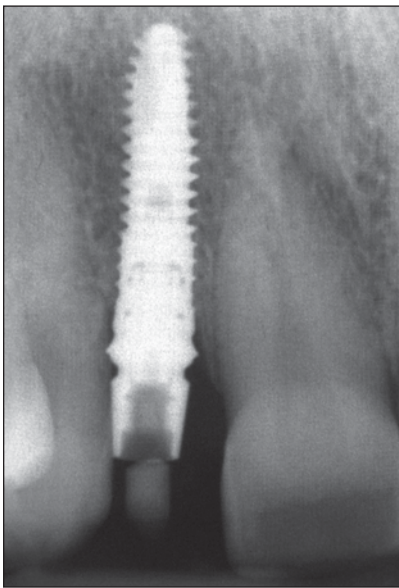
**Fig 1** Postoperative periapical radiograph showing an XiVE implant placed in the mandible (second molar region) with a 1-stage surgical procedure (control).



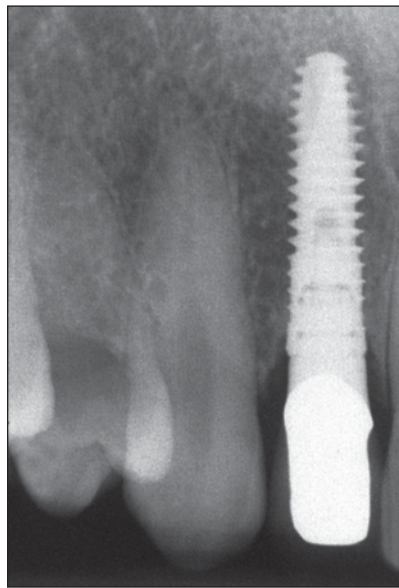
**Fig 2** Six-month follow-up.



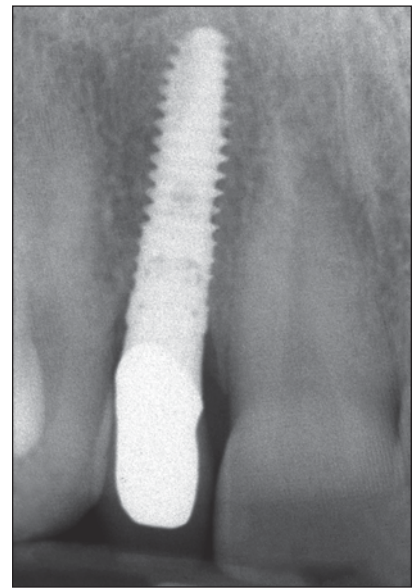
**Fig 3** One-year follow-up.



**Fig 4** Postoperative periapical radiograph showing an XiVE implant placed in a maxillary lateral incisal position and immediately restored (test).



**Fig 5** Six-month follow-up.



**Fig 6** One-year follow-up.

<b>Table 2 Variables with a Significant Affect on Crestal Bone Resorption</b>							
	<b>B</b>	<b>SE</b>	<b>Wald</b>	<b>df</b>	<b>P</b>	<b>Exp (B)</b>	<b>95% CI for EXP (B)</b>
ISQ	-.659	.227	8.406	1	.004	.517	.331 to .808
Length	-.678	.222	9.355	1	.002	.507	.328 to .784
Implant type	-.464	.232	3.986	1	.046	.629	.399 to .992

<b>Table 3 Distribution According to Macrodesign of the 69 Implants with MCBL &gt; 0.2 mm</b>			
	<b>Frialit Plus (n = 164)</b>	<b>XiVE Plus (n = 583)</b>	<b>Total</b>
Implants with bone loss > 0.2 mm	16	53	69
Immediate loading	6	27	33
Delayed loading	10	26	36

	<b>MCBL</b>				<b>Total no. of implants</b>
	<b>&lt; 0.2 mm</b>		<b>≥ 0.2 mm</b>		
	<b>MCBL</b>	<b>n</b>	<b>MCBL</b>	<b>n</b>	
2-stage implants	0.13	343	0.38	36	379
Immediately loaded implants	0.11	390	0.49	33	423
Maxilla	0.13	375	0.53	36	411
Mandible	0.12	358	0.32	33	391

**Table 5** MCBL of Implants with Bone Loss > 0.2 mm Under Various Conditions

Condition	MCBL (mm)	n
Type of recipient site		
Postextraction	0.59	21
Healed bone	0.36	48
RFA*		
< 60 ISQ	0.3	15
> 60 ISQ	0.47	41
Insertion torque		
< 30 Ncm	0.43	28
> 30 Ncm	0.43	41
Bone quality†		
1 to 2	0.3	3
3 to 4	0.44	66
Use of crestal drill		
Yes	0.33	23
No	0.48	46

\*Data were missing for 13 patients.

†Bone density classification of Misch and Judy.<sup>21</sup>

their final loss. In the present study, failing implants showed a mean ISQ value of 43, while successfully osseointegrated implants had values around 60 ISQ. Longer implants exhibited greater peri-implant crestal bone loss, most probably caused by overheating of the implant site. Deep bone preparation for placing longer implants, combined with a decreased efficacy of cooling systems, may induce critical temperatures leading to irreversible bone damage.

## CONCLUSIONS

In this study of 802 implants, 423 of which were immediately loaded and 379 of which underwent a period of undisturbed healing, no significant differences in implant success were observed between the 2 groups. No statistically significant differences were found between the immediately loaded and delayed loaded control implants when a subset of 69 implants with MCBL > 0.2 mm was evaluated.

Among the implants with a crestal bone loss greater than 0.2 mm, only ISQ value, implant length, and implant type had a statistically significant effect on crestal bone resorption. Lower bone resorption values were found in implants with higher RFA values, in shorter implants, and in TG implants.

## ACKNOWLEDGMENTS

This work was partially supported by the National Research Council (CNR), Rome, Italy; by the Ministry of Education, University, Research (MIUR), Rome, Italy; and by the Research Association for Dentistry and Dermatology (AROD), Chieti, Italy. The help of Dr Rachel Sammons, University of Birmingham, UK; of Dr Ana Emilia Farias Pontes, PhD student, State University of San Paolo (UNESP), Brazil; and of Mrs Lolita Reder is gratefully acknowledged.

## REFERENCES

- Misch CE, Wang HL, Misch CM, Sharawy M, Lemons J, Judy KWM. Rationale for the application of immediate load in implant dentistry: Part II. *Implant Dent* 2004;13:310–321.
- Weng D, Hoffmeyer M, Hurzeler MB, Richter EJ. Osseotite vs machined surface in poor bone quality. A study in dogs. *Clin Oral Implants Res* 2003;14:703–708.
- Lazzara RJ, Testori T, Trisi P, Porter SS, Weinstein RL. A human histologic analysis of osseotite and machined surfaces using implants with 2 opposing surfaces. *Int J Periodontics Restorative Dent* 1999;19:117–129.
- Rocci A, Martignoni M, Miranda Burgos P, Gottlow J, Sennerby L. Histology of retrieved immediately and early loaded oxidized implants: Light microscopic observations after 5 to 9 months of loading in the posterior mandible. *Clin Implant Dent Relat Res* 2003;5(suppl 1):88–98.
- Piattelli A, Manzon L, Scarano A, Paolantonio M, Piattelli M. Histologic and histomorphometric analysis of the bone response to machined and sand-blasted titanium implants: An experimental study in rabbits. *Int J Oral Maxillofac Implants* 1998;13:805–810.
- Wennerberg A, Albrektsson T, Andersson B, Krol J. A histomorphometric study of screw-shaped titanium implants with three different topographies. *Clin Oral Implants Res* 1995;6:24–30.
- Wennerberg A, Albrektsson T, Andersson B. An animal study of c.p. titanium screws with three different surface topographies. *J Mater Sci Mater Med* 1995;6:302–309.
- Wennerberg A, Albrektsson T. Suggested guidelines for the topographic evaluation of implant surfaces. *Int J Oral Maxillofac Implants* 2000;15:331–344.
- Albrektsson T, Wennerberg A. Oral Implant Surfaces: Part I—Review focusing on topographic and chemical properties of different surfaces and in vivo responses to them. *Int J Prosthodont* 2004;17:536–543.
- Lemmerman KJ, Lemmerman NE. Osseointegrated dental implants in private practice: A long-term case series study. *J Periodontol* 2005;76:310–319.
- Dalby MJ, Childs S, Riehle MO, Johnstone HJH, Affrossman S, Curtis ASG. Fibroblast reaction to island topography: Changes in cytoskeleton and morphology with time. *Biomaterials* 2003;24:927–935.
- Zhu X, Chen J, Scheideler L, Reichl R, Geis-Gerstorf J. Effects of topography and composition of titanium surface oxides on osteoblast responses. *Biomaterials* 2004;25:4087–4103.
- Zinger O, Anselme K, Denzer A, et al. Time-dependent morphology and adhesion of osteoblastic cells on titanium model surfaces featuring scale-resolved topography. *Biomaterials* 2004;25:2695–2711.
- Rupp F, Scheideler L, Rehbein D, Axmann D, Geis-Gerstorf J. Roughness induced dynamic changes of wettability of acid etched titanium implant modifications. *Biomaterials* 2004;25:1429–1438.

15. Papalexiou V, Novaes AB, Grisi MFM, Souza SLS, Taba M, Kajiwara JK. Influence of implant microstructure on the dynamics of bone healing around immediate implants placed into periodontally infected sites: A confocal laser scanning microscopic study. *Clin Oral Implants Res* 2004;15:44–53.
16. Degidi M, Scarano A, Iezzi G, Piattelli A. Histologic analysis of an immediately loaded implant retrieved after 2 months. *J Oral Implantol* 2005;31:247–254.
17. Iezzi G, Degidi M, Scarano A, Perrotti V, Piattelli A. Bone response around submerged, unloaded implants inserted in poor bone sites: A retrospective histological and histomorphometrical study of 8 titanium implants retrieved from man. *J Oral Implantol* 2005;31:225–233.
18. Di Iorio D, Traini T, Degidi M, Caputi S, Neugebauer J, Piattelli A. Quantitative evaluation of the fibrin clot extension on different implant surfaces: An in vitro study. *J Biomed Mater Res B Appl Biomater* 2005;74:636–642.
19. Albrektsson T, Zarb GA. Determinants of correct clinical reporting. *Int J Prosthodont* 1998;11:517–521.
20. Dawson-Saunders B, Trapp R. *Basic and Clinical Biostatistics*. Norwalk, CT: Lange Medical Books, 1993:221–223.
21. Misch CE, Judy KW. Classification of partially edentulous arches for implant dentistry. *Int J Oral Implantol* 1987;4:7–13.
22. Chiapasco M, Gatti C, Rossi E, Haefliger W, Markwalder TH. Implant-retained mandibular overdentures with immediate loading. A retrospective multicenter study on 226 consecutive cases. *Clin Oral Implants Res* 1997;8:48–57.
23. Tarnow DP, Emtiaz S, Classi A. Immediate loading of threaded implants at stage 1 surgery in edentulous arches: Ten consecutive case reports with 1- to 5-year data. *Int J Oral Maxillofac Implants* 1997;12:319–324.
24. Schnitman PA, Wöhrle PS, Rubenstein JE, DaSilva JD, Wang NH. Ten-year results for Branemark implants immediately loaded with fixed prostheses at implant placement. *Int J Oral Maxillofac Implants* 1997;12:495–503.
25. Horiuchi K, Uchida H, Yamamoto K, Sugimura M. Immediate loading of Branemark system implants following placement in edentulous patients: A clinical report. *Int J Oral Maxillofac Implants* 2000;15:824–830.
26. Lazzara RJ, Porter SS, Testori T, Galante J, Zetterquist L. A prospective multicenter study evaluating loading of Osseotite implants two months after placement: One-year results. *J Esthet Dent* 1998;10:280–289.
27. Jaffin RA, Kumar A, Berman CL. Immediate loading of implants in partially and fully edentulous jaws: A series of 27 case reports. *J Periodontol* 2000;71:833–838.
28. Ganeles SJ, Rosenberg MM, Holt RL, Reichman LH. Immediate loading of implants with fixed restorations in the completely edentulous mandible: Report of 27 patients from a private practice. *Int J Oral Maxillofac Implants* 2001;16:418–426.
29. Testori T, Meltzer A, Sel Fabbro M, et al. Immediate occlusal loading of Osseotite implants in the lower edentulous jaw. A multicenter prospective study. *Clin Oral Implants Res* 2004;15:278–284.
30. Degidi M, Piattelli A. Immediate functional and non functional loading of dental implants: A 2 to 60 months follow-up study of 646 titanium implants. *J Periodontol* 2003;74:225–241.
31. Chiapasco M, Gatti C. Implant-retained mandibular overdentures with immediate loading: A 3- to 8-year prospective study on 328 implants. *Clin Implant Dent Relat Res* 2003;5:29–38.
32. Misch CE, Degidi M. Five-year prospective study of immediate/early loading of fixed prostheses in completely edentulous jaws with a bone quality based implant system. *Clin Implant Dent Relat Res* 2003;5:17–28.
33. Malò P, Friberg B, Polizzi G, Gualini F, Vighagen T, Rangert B. Immediate and early function of Branemark System implants placed in the esthetic zone: A 1-year prospective clinical multicenter study. *Clin Implant Dent Relat Res* 2003;5(suppl 1):37–46.
34. Glauser R, Lundgren AK, Gottlow J, et al. Immediate occlusal loading of Branemark TiUnite implants placed predominantly in soft bone: 1-year results of a prospective clinical study. *Clin Implant Dent Relat Res* 2003;5(suppl 1):47–56.
35. Cooper LF, Rahman A, Moriarty J, Chaffee N, Sacco D. Immediate mandibular rehabilitation with endosseous implants: Simultaneous extraction, implant placement and loading. *Int J Oral Maxillofac Implants* 2002;17:517–525.
36. Ledermann PD, Schenk RK, Buser D. Long-lasting osseointegration of immediately loaded bar-connected TPS screws after 12 years of function: A histologic case report of a 95-year-old patient. *Int J Periodontics Restorative Dent* 1998;18:558–563.
37. Testori T, Szmukler-Moncler S, Francetti L, et al. Immediate loading of Osseotite implants. A case report and histologic analysis after 4 months of occlusal loading. *Int J Periodontics Restorative Dent* 2001;21:451–459.
38. Testori T, Szmukler-Moncler S, Francetti L, Del Fabbro M, Trisi P, Weinstein RL. Healing of Osseotite implants under submerged and immediate loading conditions in a single patient: A case report and interface analysis after 2 months. *Int J Periodontics Restorative Dent* 2002;22:345–353.
39. Degidi M, Petrone G, Iezzi G, Piattelli A. Histologic evaluation of a human immediately loaded titanium implant with a porous anodized surface. *Clin Implant Dent Relat Res* 2002;4:110–114.
40. Degidi M, Petrone G, Iezzi G, Piattelli A. Histologic evaluation of 2 human immediately loaded and 1 submerged titanium implants inserted in the posterior mandible and retrieved after 6 months. *J Oral Implantol* 2003;29:223–229.
41. Degidi M, Scarano A, Petrone G, Piattelli A. Histological analysis of clinically retrieved immediately loaded implants: A report of 11 cases. *Clin Implant Dent Relat Res* 2003;5:89–94.
42. Degidi M, Scarano A, Iezzi G, Piattelli A. Peri-implant bone in immediately loaded titanium implants: A histologic and histomorphometric evaluation in man. A report of 2 cases. *Clin Implant Dent Relat Res* 2003;5:170–175.
43. Romanos GE. Present status of immediate loading of oral implants. *J Oral Implantol* 2004;30:189–197.
44. Glauser R, Sennerby L, Meredith N, et al. Resonance frequency analysis of implants subjected to immediate or early occlusal loading. Successful vs failing implants. *Clin Oral Implant Res* 2004;15:428–434.