

# Outcomes of Fixed Protheses Supported by Immediately Loaded Endosseous Implants

Pedro Tortamano, DDS, MSD, PhD<sup>1</sup>/Tadashi Carlos Orii, DDS, MSD<sup>2</sup>/Julio Yamanochi<sup>3</sup>/  
Atlas Edson Moleros Nakamae, DDS, MSD, PhD<sup>4</sup>/Tatiana de Carvalho Guarnieri, DDS<sup>5</sup>

**Purpose:** The aim of this article was to evaluate the survival and success of Straumann implants after immediate loading. A new method for fabricating effective definitive protheses to immediately load implants in edentulous patients was presented. **Materials and Methods:** Nine patients received 4 implants each, and resin-metal protheses were installed less than 48 hours after implant placement. Mobility was evaluated immediately after the surgical procedures and 3 months subsequently using the Periotest. Clinical evaluation of soft peri-implant tissues was conducted monthly after the sutures were removed, and radiographs were obtained 6, 12, and 24 months after the surgery. **Results:** The Periotest revealed statistical values that were stable, with no mobility. No signs of inflammation and/or bleeding were observed. The radiographs did not reveal any continuous areas of radiolucency beyond the first thread of the 36 implants after 24 months. None of them failed, and the success rate was 100%. **Discussion:** It is possible to submit implants to immediate load without jeopardizing osseointegration if parameters are met, such as suitable bone quality and quantity, lack of unfavorable systemic and psychologic factors, lack of parafunctional habits, strict maintenance of prosthetic requirements, minimization of micromotion, and use of an appropriate surgical protocol. **Conclusion:** Under immediate load, osseointegration of implants is possible, and the method presented for the fabrication of resin-metal protheses has been reliable and predictable. INT J ORAL MAXILLOFAC IMPLANTS 2006;21:63–70

**Key words:** dental implants, immediate loading of implants, implant-supported protheses

The osseointegrated implant technique originally proposed by Brånemark and associates<sup>1,2</sup> included a waiting period of 3 to 6 months before the application of functional load and required a second surgical procedure to expose the implant. This

waiting period, which can bring discomfort and inconvenience to the patient, and the need for a second surgery, prompted the need for research on immediate loading of implants. Numerous works have been carried out involving immediately loaded implants in animal subjects.<sup>3–7</sup> These resulted in successful osseointegration, with outcomes similar to those obtained by using the conventional loading technique. In 1979, Ledermann<sup>8</sup> applied immediate loads to endosseous human implants. In the following decades, numerous scientific works have been published attesting to the viability of the immediate loading of implants in the interforamina area, with survival rates similar to those for implants placed using the delayed loading procedure.<sup>9–11</sup> In the majority of these studies, fabrication of a temporary prosthesis supported by the implants is indicated. The fabrication of a definitive prosthesis occurs after the osseointegration process is complete (approximately 4 months postplacement).

<sup>1</sup>Professor of the Fixed Partial Prosthesis Discipline, Faculdade de Odontologia da Universidade de São Paulo, Brazil.

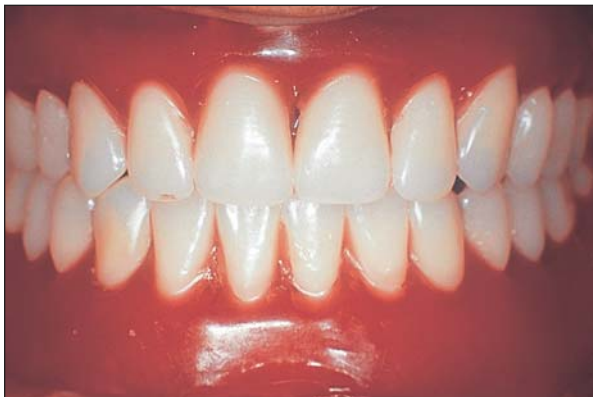<sup>2</sup>Postgraduate Program Researcher of the Fixed Partial Prosthesis Discipline, Faculdade de Odontologia da Universidade de São Paulo, Brazil.

<sup>3</sup>Dental Technician, Private Laboratory, São Paulo, Brazil.

<sup>4</sup>Professor of the Complete Denture Discipline, Faculdade de Odontologia da Universidade de São Paulo, Brazil.

<sup>5</sup>Postgraduate Program Researcher of the Complete Denture Discipline, Faculdade de Odontologia da Universidade de São Paulo, Brazil.

**Correspondence to:** Dr Pedro Tortamano, Rua Jerônimo da Veiga 428, conjunto 51, CEP 04536–001, São Paulo, Brazil. Fax: +55 11 3168 8388. E-mail: tortamano@giro.com.br



**Fig 1** Maxillary and mandibular trial dentures positioned in the mouth.

In 1999 Brånemark and associates<sup>12</sup> proposed a new implant and prosthetic component system that allowed the application of immediate loading to 3 implants in the interforamina region. The new system was called "Brånemark Novum." This technique uses previously manufactured prosthetic components that make the fabrication of a definitive prosthesis easy but can limit its usage because of the anatomic variation found in the patient and possible prosthetic recording difficulties.

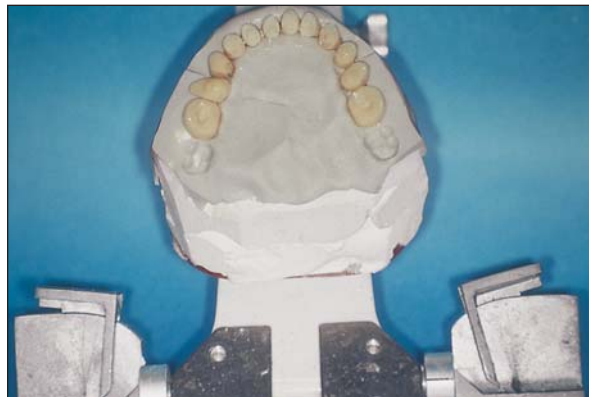In this work, a method for fabricating a definitive prosthesis is proposed. All procedures carried out in sessions prior to the surgery itself are transferred to this prosthesis, making the whole process predictable and reliable.

## MATERIALS AND METHODS

The purpose of the present study was to assess the outcomes of fixed prostheses supported by immediately loaded dental implants in the edentulous mandible.

Nine patients with edentulous mandibles were selected for treatment. The patients ranged from 32 to 70 years old. They were all healthy and presented no local or systemic contraindications. All patients were nonsmokers, with no signs or symptoms of bruxism. The opposing arch included either natural teeth (1 patient), a complete prosthesis (7 patients), or a partial fixed prosthesis (1 patient).

For each patient, through clinical examinations and panoramic radiographs, the viability of the placement of 4 Straumann implants (Straumann, Waldenburg, Switzerland) 4.1 mm in diameter and 10 mm long was analyzed. Prior to the surgical procedure, a Trilux (Vipi, Pirassununga, Brazil) arrangement of artificial teeth set on a polypropylene base (Bio Art, São Carlos, Brazil) was fabricated using a semi-

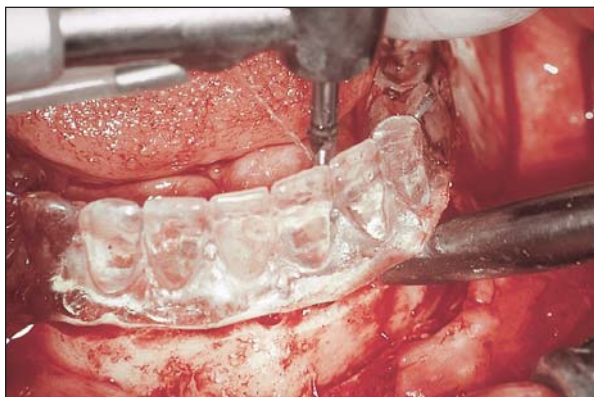


**Fig 2** Mandibular artificial teeth positioned inside the silicone index for later setting on a metallic framework.

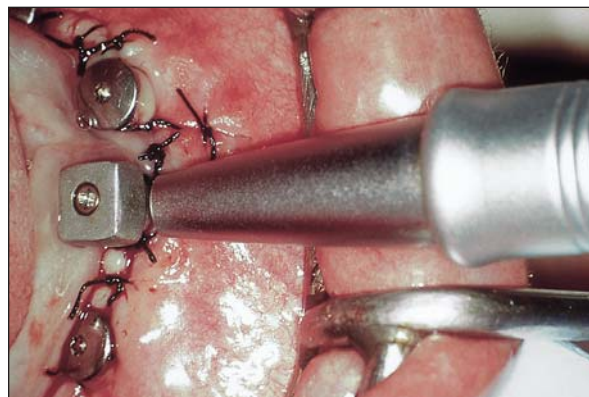
adjustable Whip-Mix articulator (Bio Art) and all of the conventional steps for the preparation of a complete denture. All parameters, such as centric relation, vertical dimension of occlusion, shade, alignment and position of the artificial teeth, compensation curves, and occlusal scheme, were addressed for the referred patient.

In the case of patients with edentulous maxillae, a conventional maxillary complete denture was fabricated according to the same criteria. The tooth arrangement was then tried in the mouth to confirm the references (Fig 1). The mandibular trial denture was duplicated in acrylic resin for use as a surgical template. The maxillary prosthesis was replaced by a plaster cast (Herodent; Vigodent, Rio de Janeiro, Brazil) over which a polymerized condensation silicone base (Zetalabor; Zhermack, Badia Polesine, Italy) was laid. The silicone impression registered the form and position of the mandibular teeth, as well as the vertical dimension of occlusion (VDO). This impression was obtained by closing the articulator with the nonpolymerized silicone against the mandibular teeth until the pre-established vertical dimension retained by the incisal guide pin (Fig 2) was realized.

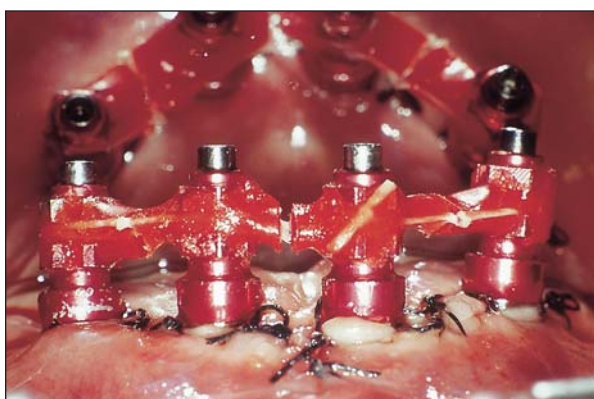
Twelve hours prior to the surgical procedure, each patient was given 500 mg amoxicillin (Amoxil, Glaxo-SmithKline, London, United Kingdom) and 50 mg rofecoxib (Vioxx; Merck, Whitehouse Station, NJ). With the aid of the surgical template, implant placement surgery was carried out (Fig 3). Following the surgery, the initial stability of each implant was measured with the Periotest instrument (Siemens, Bensheim, Germany). To standardize the arm lever position during the measurements, a tool previously cast in gold-palladium alloy (Spartan, Williams, New York) was used. It was screwed onto the implant with a Straumann Synocta abutment, and 3 measurements were made for each implant. Each time mobility measurements were taken, this tool was used (Fig 4).



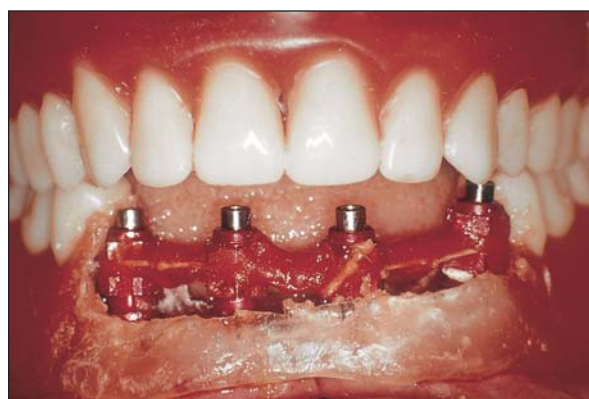**Fig 3** Surgical template positioned in the mouth, guiding the drilling for placement of the implants.



**Fig 4** Verification of initial stability through Periostest.



**Fig 5a** Impression copings screwed onto the implants, connected by acrylic resin and dental floss. Notice the sectioning of the acrylic resin unions between the implants to compensate for shrinkage (see mirror image).



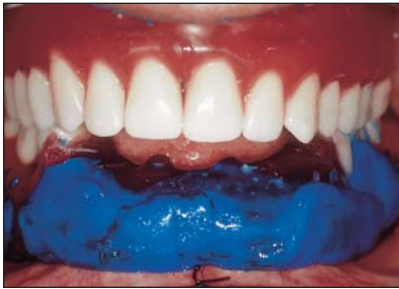**Fig 5b** Mandibular artificial teeth removed and the base positioned in the mouth to check eventual interference.

When the initial stabilization had been verified, an impression for obtaining the master cast was made. Impression copings were connected with chemically activated acrylic resin (Pattern Resin; GC America, Alsip, IL). After polymerization of the resin, the bulk of the resin union was sectioned in the area between the implants, and again the sections were connected with the same resin to compensate for the tension induced by shrinkage of the material (Fig 5a).

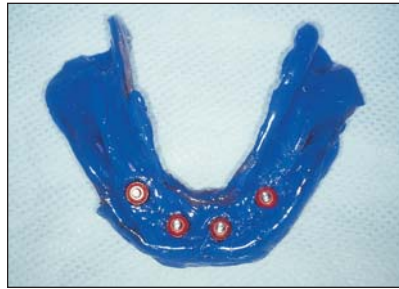
The artificial teeth in the implant region were removed from the mandibular prosthesis, and the polypropylene base was removed to expose the impression copings connected by resin. Only the edges of the teeth were retained to ensure stability. The assembly was seated over the alveolar ridge, positioned without any interference of the base in relation to the impression copings (Fig 5b). Using a syringe, condensation-polymerized wash silicone (Xantopren; Heraeus Kulzer, Hanau, Germany) was injected under the resin-connected impression cop-

ings, and another portion of the same silicone was inserted into inner part of the polypropylene base, which served as an individual impression tray (Fig 6a). The base containing the impression material was carried onto the ridge, confirming the absence of interference between the impression copings and the base. The patient was asked to keep the teeth seated in the pre-established contact position and maintain this position until the impression material had polymerized. The impression copings were then disconnected from the implants, and the impression was removed from the mouth (Fig 6b). The implant analogs were screwed onto the impression copings, and a Velmix type IV plaster (Kerr, Orange, CA) was poured to obtain the master cast (Fig 6c). The master cast was seated against the maxillary plaster and silicone cast and maintained in position through the use of wood sticks attached to the casts with sticky wax and subsequently mounted to the lower member of the articulator (Fig 7).

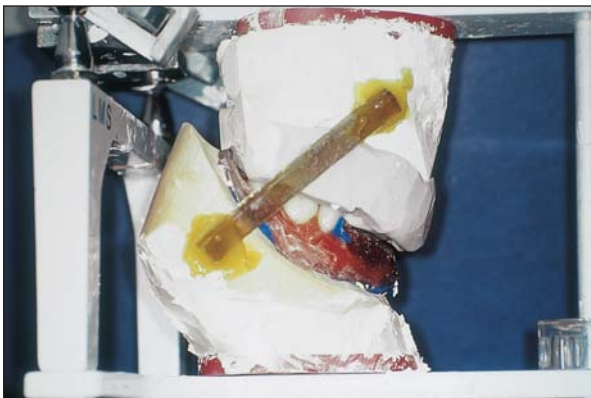
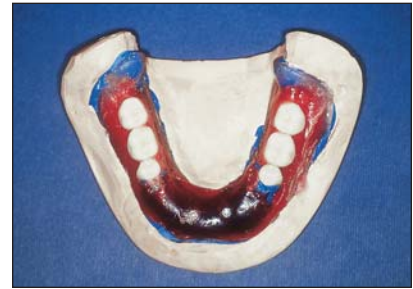


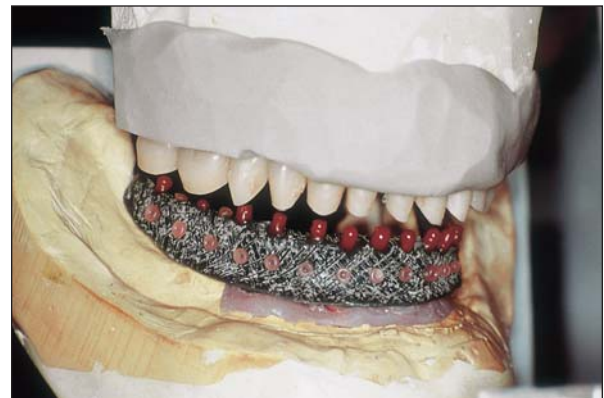**Fig 6a** Functional impression of the ridge and implants retaining the pre-established maxillomandibular relationship.



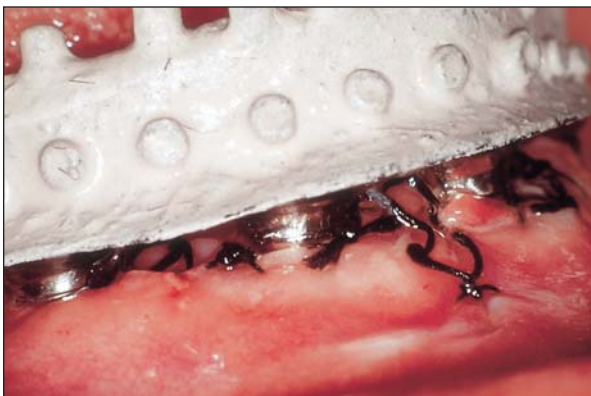**Figs 6b and 6c** Impression ready for the connection of implant analogs prior to pouring of the master cast.



**Fig 7** Master cast mounted to the lower member of the articulator, guided by the maxillary plaster and silicone cast.



**Fig 8** Mandibular artificial teeth connected to the plaster/silicone cast, guiding the metallic framework waxing.



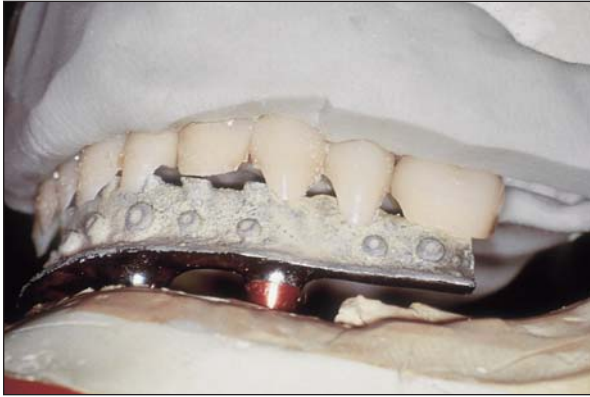**Fig 9** Metallic framework seated in the mouth. Notice the fit to the implants.

The entire base was removed from the master cast, and the mandibular artificial teeth were seated in the plaster/silicone cast, facilitating waxing of the metallic framework (Fig 8). After the framework was cast, it was seated on the master cast. It was then tried in the mouth to verify the fit (Fig 9). All mandibular artificial teeth connected to the plaster/silicone cast were then arranged on the

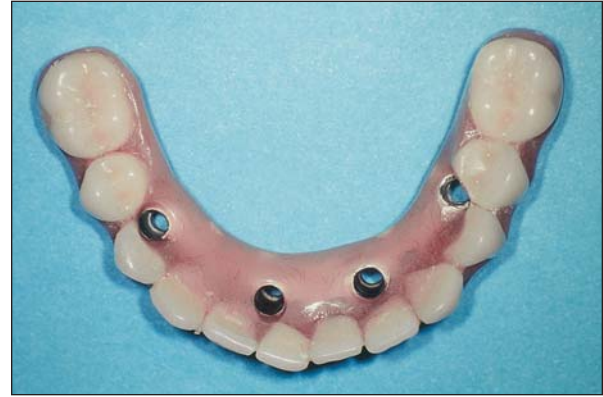framework with wax (Fig 10). The maxillary trial denture and mandibular framework with the attached teeth were seated in the mouth. After confirmation of the occlusal contacts, VDO, and esthetics, a functional impression of the maxillary arch was made. The definitive maxillary and mandibular prostheses were completed and placed within 48 hours of the surgery (Figs 11 and 12). After 10 days, all sutures were removed without removing the prosthesis, and, after 90 days, the mandibular prosthesis was removed and torque was applied to the abutments as suggested by the manufacturer (Fig 13).

At subsequent monthly clinical examinations, the prosthesis was removed to ascertain implant mobility, absence of pain, foreign body sensations/dyesthesia, peri-implant bleeding, and infection with supuration of the implants according to the success criteria established by Buser and associates.<sup>13,14</sup> At 6, 12, and 24 months, regular radiographs were obtained to detect radiolucent areas around the implants (Fig 14).

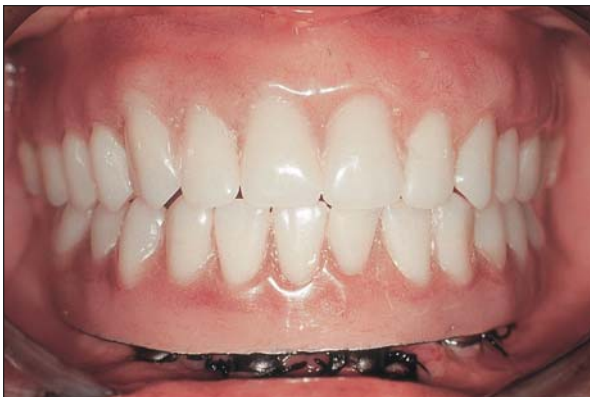A descriptive analysis of the stability was performed. A 2-factor analysis of variance (ANOVA) with repeated measures was applied to compare means stability on different occasions and at different implants.<sup>15</sup>



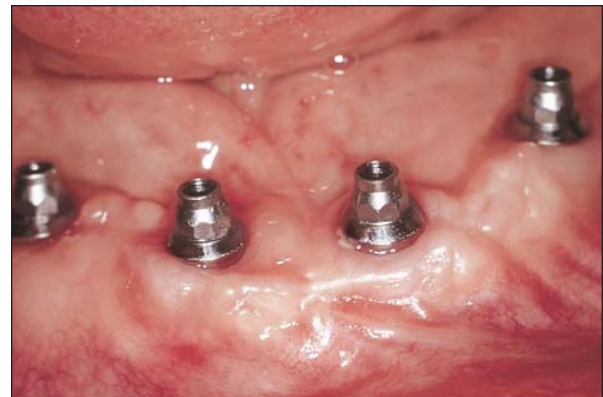**Fig 10** The mandibular artificial teeth being seated on the framework. This setting was facilitated by a maxillary plaster/silicone cast.



**Fig 11** Occlusal view of the fixed definitive prosthesis.



**Fig 12** Definitive prostheses seated in the mouth.



**Fig 13** Clinical status of the implants 90 days after the application of load.

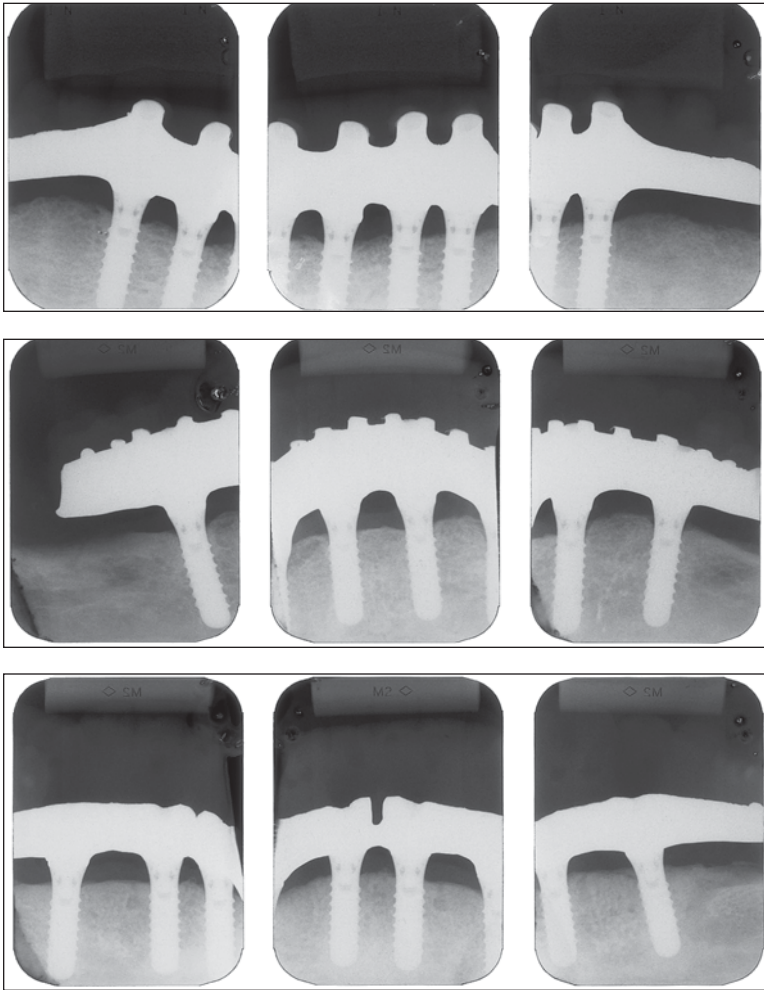
## RESULTS

Four patients reported mild pain and presented slight edema after the surgery. They were instructed to rest and prescribed medication to alleviate the pain. These measures were enough to control the clinical status. After 3 months, there was no loss of implants, and, according to the adopted criteria,<sup>13,14</sup> there was a survival rate of 100%. There were no signs or symptoms of pain or peri-implant infection or inflammation, with or without suppuration, during any of the clinical examinations, with the exception of the immediate postsurgical period, during which 4 patients presented mild edema and inflammation. According to the adopted criteria, recording of implants demonstrating bone loss past the first implant thread was required. None of the 36 implants presented such bone loss after 24 months; thus, the success rate was 100%. During the follow-

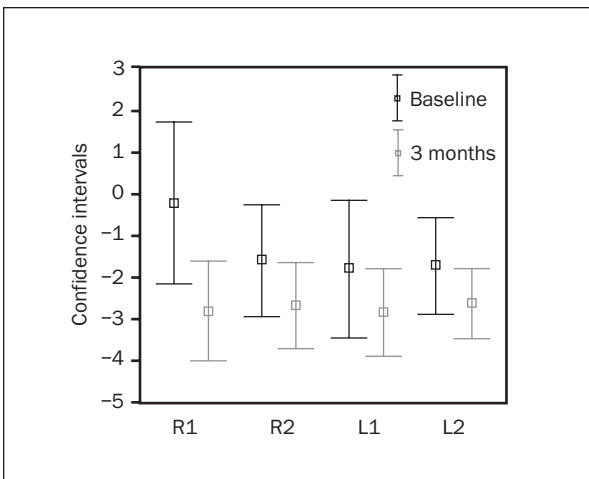
up period, the integrity of the prostheses and their components was observed.

Table 1 presents the stability means, standard deviations, and maximum and minimum values observed for each occasion and implant. The confidence intervals for the average stability with a confidence coefficient of 95% are presented in Fig 15.

In Table 2 it can be seen that the difference between the marginal averages of the stability on either of the 2 occasions was not statistically significant ( $P = .108$ ). However, this lack of statistical significance cannot be interpreted as implying no effect because of the size of the sample. An interaction effect between occasion and implant was detected ( $P = .048$ ). By establishing confidence intervals of 90% using the Bonferroni method, it was concluded that only 1 group (R1) of the 4 tested differed significantly on the 2 occasions ( $P = .048$ ).



**Fig 14** Radiographs obtained 24 months after the surgery.



**Fig 15** Confidence intervals for the average stability at each location with a confidence coefficient of 95%.

**Table 1** Stability (Periotest Values) Observed for Each Occasion and Implant

Implant/period	No. of patients	Mean	SD	Minimum	Maximum
<b>R1</b>					
Baseline	9	-0.2	2.51	-4.0	4.3
3 mo	9	-2.8	1.53	-5.0	0.0
<b>R2</b>					
Baseline	9	-1.6	1.74	-4.0	1.0
3 mo	9	-2.7	1.36	-4.0	0.3
<b>L1</b>					
Baseline	9	-1.8	2.16	-5.0	3.0
3 mo	9	-2.8	1.35	-4.7	-0.7
<b>L2</b>					
Baseline	9	-1.7	1.50	-4.0	1.0
3 mo	9	-2.6	1.09	-3.7	-0.7



## DISCUSSION

The literature reveals that it is possible to obtain osseointegration even when implants are submitted to immediate loading.<sup>8–12</sup> Among all these situations, it is made clear that the mandibular interforaminal area is the one where the most success has been achieved in the immediate load and delayed load situations. This fact can be best explained by the bone quality found in this region.<sup>9,11</sup>

A significant change in stability after 3 months only for the R1 implant position. From the biologic point of view this interaction effect cannot be justified, considering that all the implants were placed in the mandible, specifically in the area between the mental foramina, in bone tissue of very similar characteristics.

For evaluating implant osseointegration, the success criteria proposed by Buser and associates<sup>13,14</sup> were used. It is hypothesized that immediate loading alone does not interfere with the development of osseointegration, as long as the implant is not subjected to excessive movement.<sup>16–18</sup> Despite the controversy among authors concerning the definition of “excessive movement,” clinically it should be the least movement possible, to avoid interfering with osseointegration. Through the prosthesis, masticatory forces are transmitted to the implants. Connection of the implants through a metallic structure seems to be an efficient way to reduce mechanical stress imposed on the implants, as suggested by Skalak<sup>19</sup> in his theoretical model. For this reason, it is recommended that during the application of an immediate load, the prostheses should present a rigid structure, thus preventing deflections or fractures that could lead to excessive micromovement of the implants during the osseointegration period.

As with prostheses used in the delayed loading of implants, immediately loaded prostheses must present the most passive possible fit, adequate occlusal clearance, and a rigid framework aimed at reducing physical disturbances on the healing bone tissue,<sup>18</sup> especially during the osseointegration phase.<sup>20</sup> Moreover, these prostheses cannot neglect important requirements for the rehabilitation of a completely edentulous patient, such as esthetics, centric relation, VDO, and lip support.

The technique presented in this work allows the accomplishment of an implant-supported prosthesis in a period of less than 48 hours, with all the requirements mentioned above established during appointments prior to the surgery. Despite the advantages this technique presents, it also has some limitations, such as the need of a lab technician's time for continuous activity over a 48-hour laboratory period and

**Table 2 ANOVA Table to Test the Occasion and Implant Effects on Stability**

Variable	DF	Sum of squares	Average squares	F	P
Occasion	1	35.56	35.56	3.28	.108
Residue 1	8	86.70	10.84		
Implant	3	6.38	2.13	1.13	.357
Residue 2	24	45.26	1.89		
Occasion × implant	3	8.64	2.88	3.04	.048
Residue 3	24	22.74	0.95		

DF = degree of freedom.

more expensive lab costs because of the short fabrication time.

If an implant failed, the same prosthesis would be placed as a temporary restoration until a new prosthesis could be fabricated.

Although it is characterized by a large number of technical procedures, the proposed technique presents, for the most part, procedures familiar to all clinicians, apart from the fact that the preparatory procedures can be checked as often as necessary before the surgical phase.

## CONCLUSION

The results presented demonstrated a survival rate of 100% of the implants in a period of 90 days and a final success rate of 100% at the end of 24 months in the selected patient population. This technique provides safe, quick, and predictable restorations while meeting all requirements for the appropriate execution of definitive fixed prostheses. It is clear that there is a need for longitudinal studies and controlled clinical trials to evaluate, on a permanent basis, not only the proposed technique, but also the effect of immediate loading.

## REFERENCES

1. Brånemark P-I, Adell R, Breine U, Hanson BO, Linström J, Ohlsson A. Intraosseous anchorage of dental prostheses. I. Experimental studies. *Scand J Plast Reconstr Surg* 1969;3:81–100.
2. Brånemark P-I, Hanson BO, Adell R, et al. Osseointegrated implants in treatment of the edentulous jaw. Experience from a 10-year period. *Scand J Plast Reconstr Surg* 1977;16(suppl):1–132.
3. Henry PJ, Tan AES, Leavy J, Johansson CB, Albrektsson T. Tissue regeneration in bony defects adjacent to immediately loaded titanium implants placed into extraction sockets: A study in dogs. *Int J Oral Maxillofac Implants* 1997;12:758–766.

4. Piattelli A, Corigliano M, Scarano A, Costigliola G, Paolantonio M. Immediate loading of titanium plasma-sprayed implants: An histologic analysis in monkeys. *J Periodontol* 1998;69: 321–327.
5. Romanos G, Toh CG, Siar CH, et al. Peri-implant bone reactions to immediately loaded implants. An experimental study in monkeys. *J Periodontol* 2001;72:506–511.
6. Romanos G, Toh CG, Siar CH, Swaminathan D, Ong AH. Histologic and histomorphometric evaluation of peri-implant bone subjected to immediate loading: An experimental study with *Macaca Fascicularis*. *Int J Oral Maxillofac Implants* 2002;17: 44–51.
7. Costa FC. Analysis of Titanium Implants Interface Placed in Rabbit Tibia Bones (*Oryctolagus cuniculus*) and Submitted to Immediate Load, Continuous and Non-axial [thesis]. São Paulo, Brazil: Biomedic Sciences Institute, University of São Paulo, 2001.
8. Ledermann PD. Stegprothetische Versorgung des zahnlosen Unterkiefers mit Hilfe plasmabeschichteten Titanschraubimplantaten. *Deutsch Zahnärztliche Zeitung* 1979;34:907–911.
9. Schnitman PA, Wöhrle PS, Rubenstein JE, DaSilva JD, Wang N-H. Ten-year results for Brånemark implants immediately loaded with fixed prosthesis at implant placement. *Int J Oral Maxillofac Implants* 1997;12:495–503.
10. Tarnow DP, Emtiaz S, Classi A. Immediate loading of threaded implants at stage 1 surgery in edentulous arches: Ten consecutive case reports with 1- to 5 year data. *Int J Oral Maxillofac Implants* 1997; 12:319–324.
11. Chiapasco M, Gatti C, Rossi E, Haefliger W, Markwalder TH. Implant-retained mandibular overdentures with immediate loading. A retrospective multicenter study on 226 consecutive cases. *Clin Oral Implants Res* 1997;8:48–57.
12. Brånemark P-I, Engstrand P, Öhrnell L-O, et al. Brånemark Novum: A new treatment concept for rehabilitation of the edentulous mandible. Preliminary results from a perspective clinical follow-up study. *Clin Implant Dent Relat Res* 1999;1: 2–16.
13. Buser D, Weber H-P, Lang NP. Tissue integration of nonsubmerged implants. 1-year results of a prospective study with 100 ITI hollow-cylinder and hollow-screw implants. *Clin Oral Implants Res* 1990;1:33–40.
14. Buser D, Mericske-Stern R, Bernard JP, et al. Long-term evaluation of non-submerged ITI implants. Part I: 8-year life table analysis of a prospective multi-center study with 2359 implants. *Clin Oral Implants Res* 1997;8:161–172.
15. Neter J, Kutner MH, Nachtsheim CJ, Wasserman W. *Applied Linear Statistical Models*, ed 4. Chicago: Irwin, 1996.
16. Pilliar RM, Deporter D, Watson P. A quantitative evaluation of the effect of movement at a porous coated implant-bone interface. In: Davies EJ (ed). *The Bone-Biomaterial Interface*. Toronto: University of Toronto Press, 1991:380–387.
17. Brunski JB. Influence of biomechanical factors at the bone-biomaterial interface. In: Davies EJ (ed). *The Bone-Biomaterial Interface*. Toronto: University of Toronto Press, 1991:391–405.
18. Szmukler-Moncler S, Salama H, Reingewirtz Y, Dubruille J-H. Timing of loading and effect of micromotion on bone-dental implant interface: Review of experimental literature. *J Biomed Mater Res* 1998;43:192–203.
19. Skalak R. Biomechanical considerations in osseointegrated prostheses. *J Prosthet Dent* 1983;49:843–848.
20. Davies JE. Mechanisms of endosseous integration. *Int J Prosthodont* 1998;11:391–401.