

Bone Density Assessments of Dental Implant Sites: 2. Quantitative Cone-Beam Computerized Tomography

Prasit Aranyarachkul, DDS, MS¹/Joseph Caruso, DDS, MSD, MS²/Bernard Gantes, DDS, MS³/Eloy Schulz, MD⁴/
Matt Riggs, PhD⁵/Ivan Dus, MD, DDS, PhD⁶/Jason M. Yamada, DDS, MS⁷/Max Crigger, DDS, MS⁸

Purpose: Bone density was evaluated in designated implant sites using a novel volumetric computerized tomographic device. Those measurements were then compared with traditional quantitative computerized axial tomography and subjective bone density evaluation. **Materials and Methods:** Sixty-three potential sites for implant placement in jaws from 9 human cadavers were used. Indicator rods 2 mm in diameter were placed in all sites. Radiographic images representing 1-mm buccolingual slices immediately mesial and distal to the rods were selected. Bone density in Hounsfield units was assessed using quantitative cone-beam computerized tomography (QCBCT) and quantitative computerized tomography (QCT) in a standardized implant area superimposed on the images. Bone density was also subjectively evaluated by 2 independent examiners using the Lekholm and Zarb classification. **Results:** The QCBCT bone density values were generally found to be higher than the corresponding QCT measurements. The correlations between the QCT and QCBCT values, however, were very high in spite of this systematic difference between the 2 methods. The Lekholm and Zarb ratings for the 2 examiners showed correlation coefficients ranging between 0.46 and 0.60 for the relationships with the QCBCT values. For each of the scores used for the subjective classification, however, a wide range of corresponding QCBCT values was observed. **Discussion:** High dosage has been the major impediment to the utilization of CT in implant dentistry. The development of a reliable volumetric CT alternative with reduced radiation should provide an effective method for the assessment of both bone quantity and bone density. **Conclusions:** Access to objective radiographic bone density values should constitute a valuable supplement to subjective bone density evaluations prior to implant placement. QCBCT could be considered an alternative diagnostic tool for preoperative bone density evaluation, especially since the reported radiation dose is minimal. *INT J ORAL MAXILLOFAC IMPLANTS* 2005;20:416-424

Key words: bone density, computerized tomography, cone-beam computerized tomography, dental implants, Hounsfield units

¹Resident, Advanced Education Program in Periodontics and Implant Surgery, School of Dentistry, Loma Linda University, Loma Linda, California.

²Associate Professor, Advanced Education Program in Orthodontics, School of Dentistry, Loma Linda University, Loma Linda, California.

³Associate Professor, Department of Periodontology, School of Dentistry, Loma Linda University, Loma Linda, California.

⁴Professor, Department of Radiology, Loma Linda Medical Center, Loma Linda, California.

⁵Professor, Statistician, School of Public Health, Loma Linda University, Loma Linda, California.

⁶Assistant Professor, Advanced Education Program in Orthodontics, School of Dentistry, Loma Linda University, Loma Linda, California.

⁷Assistant Professor, Department of Periodontology, School of Dentistry, Loma Linda University, Loma Linda, California.

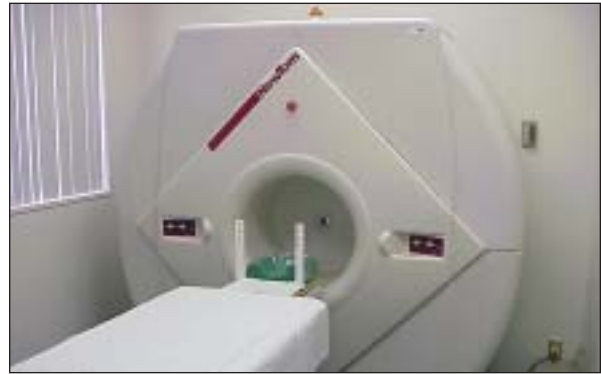⁸Professor, Department of Periodontology, School of Dentistry, Loma Linda University, Loma Linda, California.

Correspondence to: Dr Max Crigger, School of Dentistry, Loma Linda University, Loma Linda, CA 92354. Fax: +909 558 4801. E-mail: mcigger@sd.llu.edu

Clinical success of dental implants is influenced by both the volume (quantity) and density (quality) of available bone. Bone quality and quantity varies from site to site and from patient to patient. Results of studies indicate higher survival rates for implants placed in bone of good quality and quantity, such as that found in the anterior region of the mandible.¹⁻¹² Therefore, an accurate evaluation of bone structure is essential prior to implant placement.

Classification systems for osseous evaluation have been introduced. Lekholm and Zarb¹³ classified bone density radiographically into 4 types, based on the amount of cortical bone versus trabecular bone. Misch¹⁴ related bone density to the clinical hardness of the bone as subjectively perceived during drilling prior to implant placement. A method of obtaining objective measurements of the cutting resistance prior to placement of implants was developed by Johansson and Strid.¹⁵

Fig 1 Cone-beam computerized tomography (CBCT) device (NewTom).



Computerized axial tomography (CT) is an established method for acquiring bone images before dental implant surgery.^{16–20} It can also be used for objective quantification of trabecular and cancellous bone mineral densities, ie, quantitative CT (QCT).^{21,22} QCT allows precise 3-dimensional anatomic localizations and furnishes direct density measurements, expressed in Hounsfield units (HU). Only a few studies have reported on the use of QCT in relation to oral implants.^{23–25}

The amount of radiation reportedly delivered to the patient for each CT scan is 3 mGy, measured at the skin surface.²² The x-ray dose absorbed by the patient during CT scanning may limit the use of this modality for routine diagnosis or repeated surveys. However, a new type of CT machine for the purpose of dental and maxillofacial imaging has been introduced (NewTom, Model QR-DVT 9000; QR, Verona, Italy) (Fig 1) that lessens the patient's radiation exposure. This technique uses a cone-shaped x-ray beam centered on an x-ray area detector and is termed cone-beam CT (CBCT).^{26–28} As in conventional CT imaging, quantitative bone density measurements expressed in HU can be retrieved (ie, quantitative CBCT [QCBCT]). Volume data can be acquired in a single rotation of the beam and detector. The amount of radiation absorbed by the patient for each scan is reportedly 0.62 mGy.²⁷

A series of studies using cadaver specimens has been initiated in the authors' laboratory that will evaluate and compare (1) the Lekholm and Zarb subjective assessment of bone density¹³; (2) HU density recordings with conventional QCT; (3) HU density recordings with the new QCBCT approach; (4) torque resistance during implant placement; (5) resonance frequency analysis after implant placement; and, ultimately, (6) histologic determination of bone density.

In the first study of this series, Lekholm and Zarb¹³ subjective assessments by 2 independent examiners were compared to HU density recordings with the conventional QCT. Coefficients of correlation ranging

between 0.5 and 0.7 were observed for the relationship between these methods. However, for each score used for the subjective classification, a wide range of corresponding QCT values was observed. It was concluded that access to objective QCT values should constitute a valuable supplement to subjective bone density evaluations prior to implant placement.²⁵

The aims of the present study, the second study in the series, were (1) to evaluate variations in bone density in designated implant recipient sites using HU density recordings made with the new QCBCT method; (2) to compare HU density recordings made using the conventional QCT method with HU density recordings made with the new QCBCT method; and (3) to compare Lekholm and Zarb subjective assessments to HU density recordings made with the new QCBCT method.

MATERIALS AND METHODS

The overall design of this study is presented in the flowchart of Fig 2.

Specimens

Specimens for the present study were the same as those for the previous study of this series.²⁵ Human cadavers fixed in formalin from the Division of Anatomy at Loma Linda University were screened for suitable partially or completely edentulous maxillae and mandibles. An attempt was made to retrieve specimens with potential implant sites representing all regions of the jaws. A total of 63 implant sites distributed among 36 specimen blocks from 9 skulls were selected and freed of all soft tissues. Each specimen block provided 1 to 4 implant sites, and each had at least the minimum alveolar bone height necessary to accommodate 4.0 × 10-mm dental implants.

Aluminum direction-indicator rods 2 mm in diameter were placed in all designated implant recipient sites to a depth of 2 mm. A 2-mm-diameter twist drill

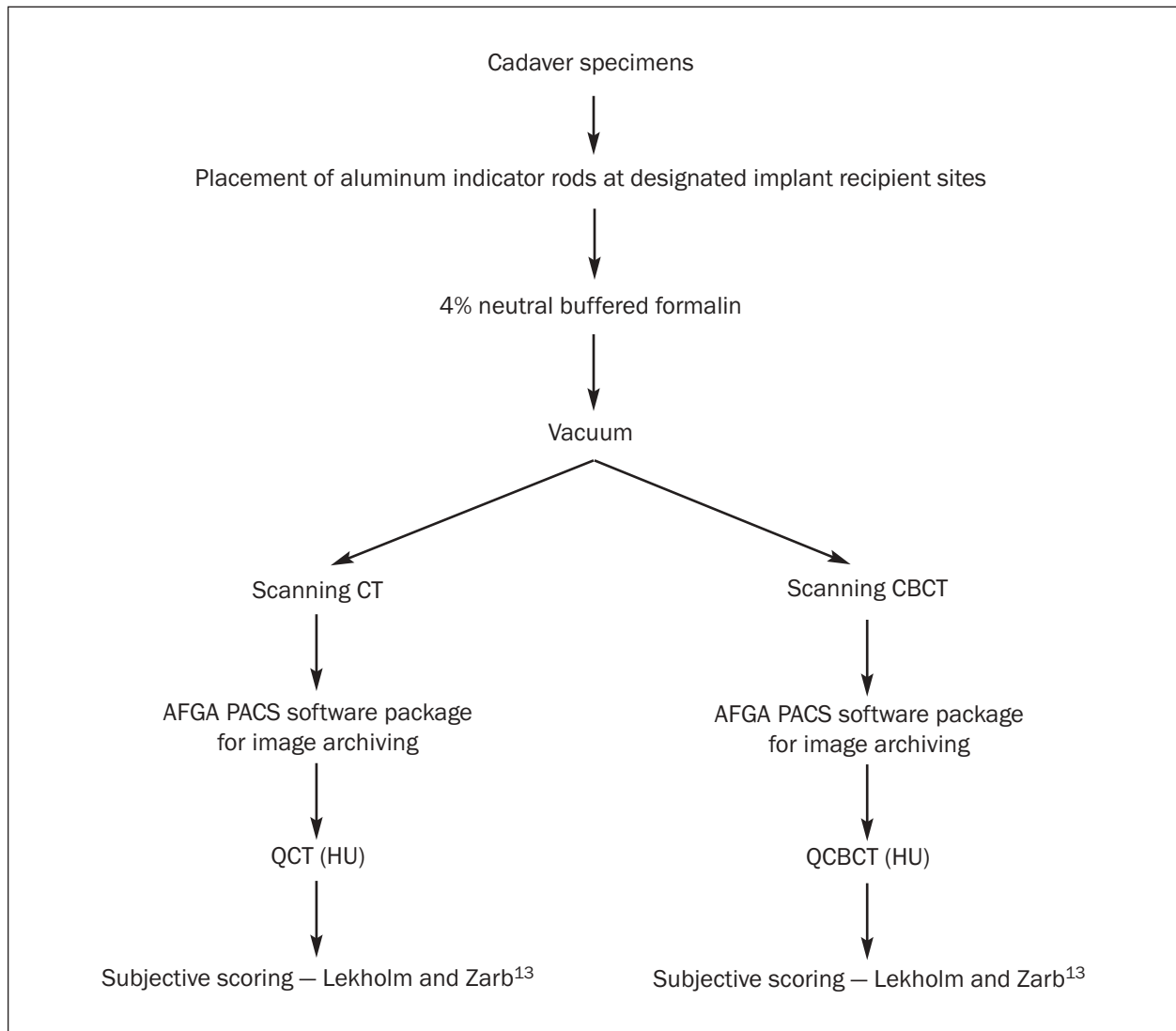


Fig 2 Flowchart demonstrating sequence of procedures. All implant sites underwent both conventional CT and CBCT scanning.

guided by a paralleling device was used to perform osteotomies in the specimens. The rods extended 2 to 4 mm coronal to the bony crest.

Preparation for and Acquisition of CT Images

The methods used to prepare for CT scanning, acquire CT images, and perform the QCT bone density readings were described in the first article.²⁵

Preparation for CBCT Scanning

The jaw specimens were mounted in acrylic plastic sheets (Acrylite; Cyro Industries, Rockaway, NJ) as described previously.²⁵ However, to accommodate for the CBCT scanning, 14 × 27-cm containers housing 1 sheet with 3 specimen blocks immersed in formalin were used. The containers were placed in a

vacuum chamber for 30 minutes to remove air bubbles, which can create errors in the density evaluation.

Acquisition of CBCT Images

Each container housing specimens was placed on the CBCT (NewTom) table and positioned so the specimen blocks were parallel to the axis of the table. The image slices to be obtained with the CBCT unit were perpendicular to this axis and parallel to the indicator rods.

Data from the radiographic examinations were transferred to an Agfa picture archiving communication system (Impax DS 3000 version 4.1 SP2; Agfa, Ridgefield Park, NJ) for easy access and analysis. The images were sequentially examined to identify each of the 63 aluminum indicator rods. For each of the

sites, an image representing a 1-mm-thick buccolingual slice immediately mesial to the rod and an image representing a 1-mm-thick buccolingual slice immediately distal to the rod were selected for analysis. In this way, each of the designated 4-mm-wide implant sites were evaluated based on two 1-mm-wide images separated by 2 mm (the diameter of the aluminum rod). Depending on the position of the specimen within the box, the aluminum rods could occasionally be seen on 3 sequential slice images. When this occurred, the adjacent mesial and distal images selected for analysis were separated by 3 mm rather than 2 mm.

QCBCT Bone Density Measurements

The selected 126 images mesial and distal to the aluminum rods were analyzed using Impax software (Agfa). This software includes an application to map the bone within a defined area and to provide the average bone density within this area in HU. A rectangular area 4.1×10.5 mm was first mapped onto each image and placed over the image where the implant would be placed. The positioning of the rectangle was guided by the direction of the aluminum rod as observed from the adjacent image and also by the desire to have the entire implant placed in bone, without exposure of the implant threads, as would be the case in a clinical situation, where a peaked crest would be leveled, if necessary, to enable complete implant burial. In the present study, on occasion, the 4.1×10.5 -mm rectangle had to be shifted apically to define the relevant bone housing for the implant. Bone density readings were then obtained from 3 equal portions of the rectangular area: the coronal third, the middle third, and the apical third, each 4.1×3.5 mm. In addition, a separate reading of the top 1 mm layer of the coronal third of the rectangular area was obtained.

Reproducibility of the QCBCT bone density measurements was evaluated using duplicate readings of 20 randomly selected images of the mesial and distal aspects of the 63 implant sites. The procedures used to retrieve QCBCT bone density measurements were identical to those used previously to acquire QCT density recordings.²⁵ This allowed a comparison of these 2 radiographic methods of measuring bone density expressed in HU.

HU are based on a linear scale defined only by 2 points; the attenuation of dry air set at $-1,000$ HU and the attenuation of pure water at 25°C set at 0 HU. Cortical bone may show HU values in the $1,000$ to $1,600$ range. Trabecular bone shows lower HU values than cortical bone. Negative readings might indicate trabecular bone that was mostly replaced by fat.²⁹

Subjective Bone Density Evaluation

As in the previous study of this series,²⁵ subjective bone density assessments were also performed. Paper prints of each of the 20 selected images magnified 1.5 times were obtained. Two examiners with extensive clinical dental implant experience (the same examiners as in the previous study) independently rated the bone density of these images of the designated implant sites. On each film, the location and the angulation of the aluminum indicator rod as observed from the adjacent image was indicated by a pencil line. Each examiner scored the bone density of the implant sites using the classification system of Lekholm and Zarb¹³:

- Type 1 bone: Almost entirely comprised of homogeneous compact bone
- Type 2: A thick layer of compact bone surrounding a core of dense trabecular bone
- Type 3: A thin layer of cortical bone surrounding a core of dense trabecular bone
- Type 4: A thin layer of cortical bone surrounding a core of low-density trabecular bone

Repeat classifications of the 20 images were performed by the examiners for the purpose of evaluating the intraobserver reproducibility of the ratings.

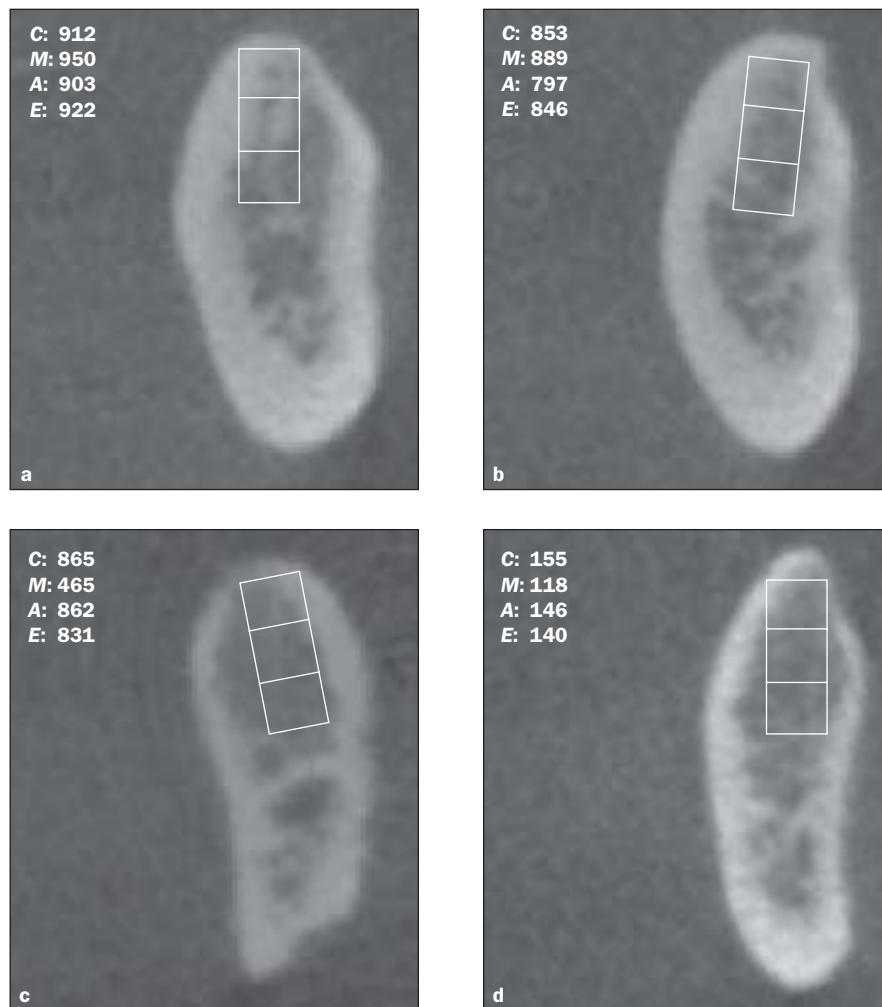
Data Analysis

Both bone density measurements made using the QCT method and measurements made using the QCBCT method were expressed in HU. Comparisons were expressed in terms of simple covariance (Pearson r values) and absolute agreement (intraclass correlation coefficients [ICCs]). Comparison of QCT and QCBCT measurements in HU with subjective Lekholm and Zarb¹³ scores (1 to 4) were expressed by Spearman rank order correlations. Calibration between QCT and QCBCT was not addressed. Instead, the authors opted to use the independent settings and conditions established for each method. Use of Pearson r values allows assessment of the magnitude of the covariance regardless of the starting parameters. All analyses used implant site as the computational unit.

RESULTS

Examples of individual images together with the HU bone density readings obtained using QCBCT and Lekholm and Zarb¹³ classifications are provided in Figs 3a to 3d.

Reproducibility of the QCBCT bone density measurements as evaluated from the duplicate readings showed an ICC of 0.99. The repeat ratings by the



Figs 3a to 3d Mandibular scans with a 4.1×10.5 -mm rectangle superimposed over the region of interest. Bone density in HU is provided for each third of the rectangle and for the entire rectangle. Lekholm and Zarb¹³ subjective bone density classification: (a) type 1; (b) type 2; (c) type 3; (d) type 4. Where necessary, the rectangle was moved apically from the crest to enable complete bone encasement, as in (d). C = coronal third; M = middle third; A = apical third; E = entire area.

examiners using the Lekholm and Zarb¹³ classification showed ICC of 0.70 for examiner 1 and 1.00 for examiner 2.

QCBCT Bone Density

Means and ranges for the QCBCT bone density values are presented in Table 1. The highest readings were found for the coronal 1 mm of the rectangular implant area, followed by the coronal third of the rectangular area. Values for images from the mesial aspect of the designated implant sites were generally higher than corresponding readings for the distal aspects. Large ranges of values were seen for all subdivisions of the rectangular implant areas.

Comparison Between QCT and QCBCT

The relationships between QCT and QCBCT bone density recordings are illustrated in Fig 4. QCT and QCBCT bone density values for mesial images have been plotted separately for the coronal 1 mm, coronal third, middle third, and apical third according to descending QCT HU values, which were fitted on the regression line. It can be observed that QCBCT bone density values for the coronal, middle, and apical thirds were generally higher than the corresponding QCT recordings. The relationships between the QCT and QCBCT values were close, as demonstrated by the Pearson correlation coefficients, which ranged from 0.92 to 0.98. Use of ICCs, as well as taking the

absolute agreement of the numerical values into account, resulted in somewhat lower coefficients of correlation for the coronal, middle, and apical thirds because of the systematic difference in magnitude between the 2 methods. These ranged between 0.73 and 0.96. Results for distal images (not shown) corresponded to those for the mesial images.

Correlation Between QCBCT Bone Density and Subjective Scoring

Spearman's rho coefficients of correlation for the relationship between QCBCT bone density values and the Lekholm and Zarb¹³ classification were calculated to be 0.60 (mesial) and 0.47 (distal) for examiner 1 and 0.46 (mesial) and 0.50 (distal) for examiner 2. Although overall relationships were observed, there was a lack of precision in the Lekholm and Zarb measurement ratings. Wide ranges of HU were present within each of the 4 Lekholm and Zarb classes, particularly for the ratings used most frequently, bone density types 2 and 3. A scatter plot to illustrate this is presented in Fig 5.

DISCUSSION

Preoperative evaluation of bone density is essential to assist the clinician with planning implant therapy. Accurate information on bone density will help the surgeon identify suitable implant sites, thereby improving the surgical planning and, eventually, the success rate of the procedures. To obtain this knowledge preoperatively, adequate radiographic examination is required. This study was designed to compare assessment of bone density using a new type of CT with assessment using conventional CT.

Postmortem cadaveric material kept in 4% formalin was used. Cadavers were chosen because this article was part of a continuing investigation using the same specimens to evaluate various methods of assessing bone density which will eventually include histological examination. It should be kept in mind that the density of cadaveric bone may not correspond to the density of vital bone.

The availability of cadavers was limited, especially since edentulous sites with sufficient bone volumes were being sought. This resulted in an uneven distribution of subject age groups and jaw locations of designated implant sites.²⁵ Therefore, the bone density data may not be fully representative. Nevertheless, comparisons of bone density determinations within the available material should be meaningful.

As the research plan included placement of 4.0 × 10-mm implants in designated implant sites, a rectangular area of 4.1 × 10.5 mm was chosen as the

Table 1 Means and Ranges for QCBCT Bone Density in HU of the Rectangular Implant Area

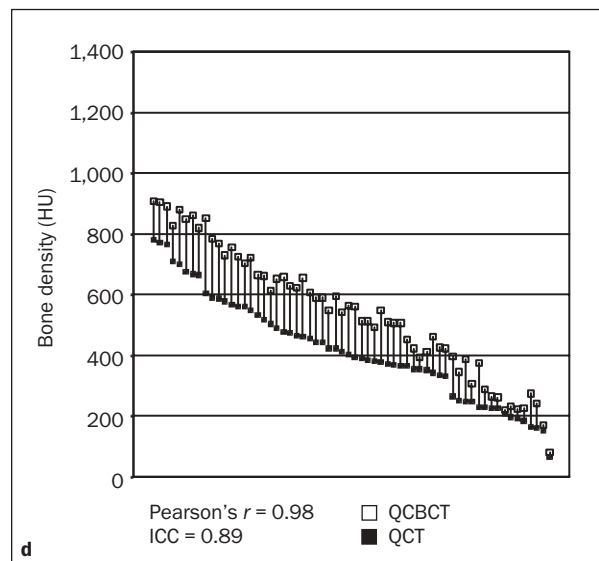
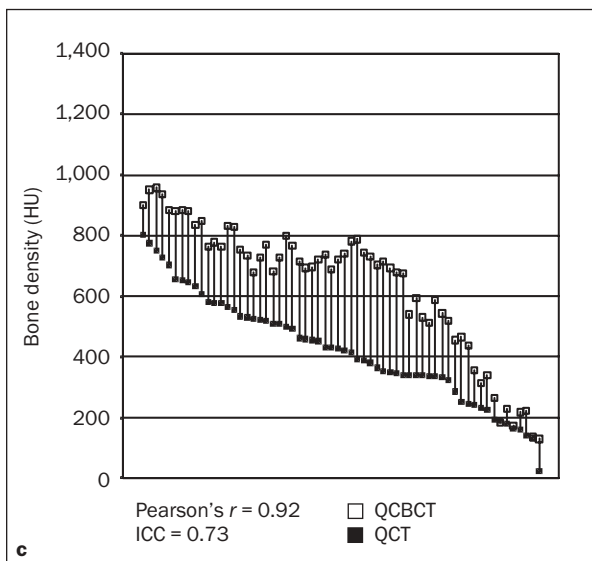
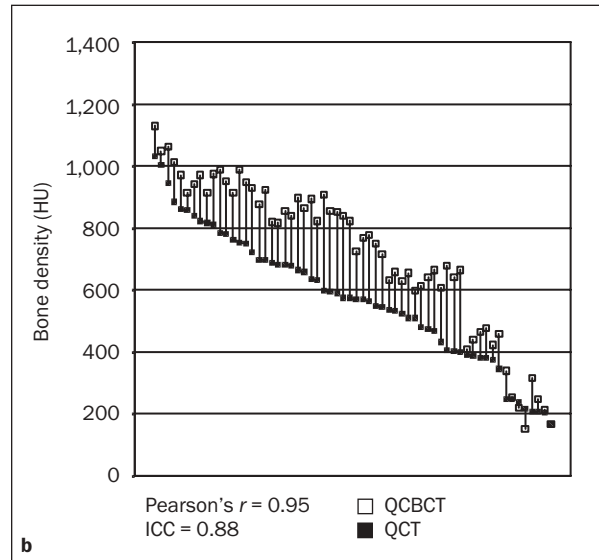
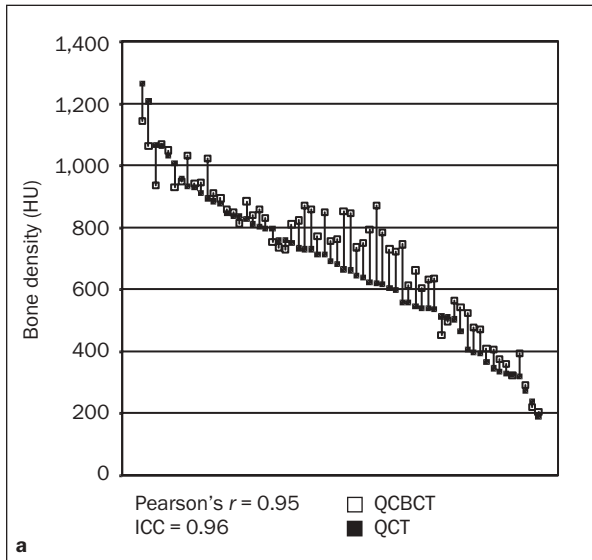
Location	Bone density (HU)	
	Mean	Range
Mesial (n = 63)		
Coronal 1 mm	726	204-1143
Coronal third	718	153-1130
Middle third	638	129-957
Apical third	542	80-907
Entire area	633	143-940
Distal (n = 63)		
Coronal 1 mm	666	170-1181
Coronal third	639	155-1022
Middle third	527	118-895
Apical third	524	142-824
Entire area	563	140-887

region of interest (the closest fit to the size of the implants, including immediate adjacent areas, that could be mapped out with the available software). As mentioned, the positioning of the rectangle was guided by the direction of the aluminum rod as observed from the adjacent images. It was also guided by the desire to have the entire implant placed in bone without exposure of implant threads. This meant that in many sites, because of the anatomy of the ridge, the superior aspect of a dense crest was not included in the areas to be measured. This is a reflection of what may happen in the clinical setting, as in many instances the superior part of a peaked bone crest may be removed during osteotomy to optimize implant placement.

In the present study it was observed that the capability to reproduce the QCBCT HU values was very high, as demonstrated by an ICC for absolute agreement of 0.99.

The QCBCT bone density values were generally found to be higher than the corresponding QCT recordings. The relationships between the QCT and QCBCT values, however, were very consistent, as demonstrated by high Pearson correlation coefficients. Use of the ICC, as well as taking the absolute agreement of the numerical values into account, resulted in somewhat lower coefficients of correlation because of the systematic difference between the 2 methods. Whether the QCT or the QCBCT values are closer to the corresponding histological bone densities remains to be learned. This topic will be addressed in a future study relating both QCT and QCBCT HU values to histologic measurements of bone density.

The comparisons of QCBCT HU values to the subjective bone quality classification of Lekholm and



Figs 4a to 4d QCBCT and QCT²⁵ Bone density in HU plotted for the mesial scans for the (a) coronal 1 mm, (b) coronal third, (c) middle third, and (d) apical third.

Zarb¹³ in the present study disclosed an overall relationship between these 2 methods. However, wide ranges of HU values within each of the 4 Lekholm and Zarb classes were observed, particularly for the ratings used most frequently, bone density types 2 and 3. This same variation was previously observed when QCT HU values were compared to the Lekholm and Zarb classification^{24,25} and may be a reflection of the limitations of a subjective system

for bone density assessment. It would seem that access to objective, radiographic bone density values should constitute a valuable supplement to subjective assessments prior to implant placement.

In conclusion, CBCT should be considered an alternative diagnostic tool to CT for implant preoperative evaluation, particularly as the associated radiation dosage is reportedly much lower.

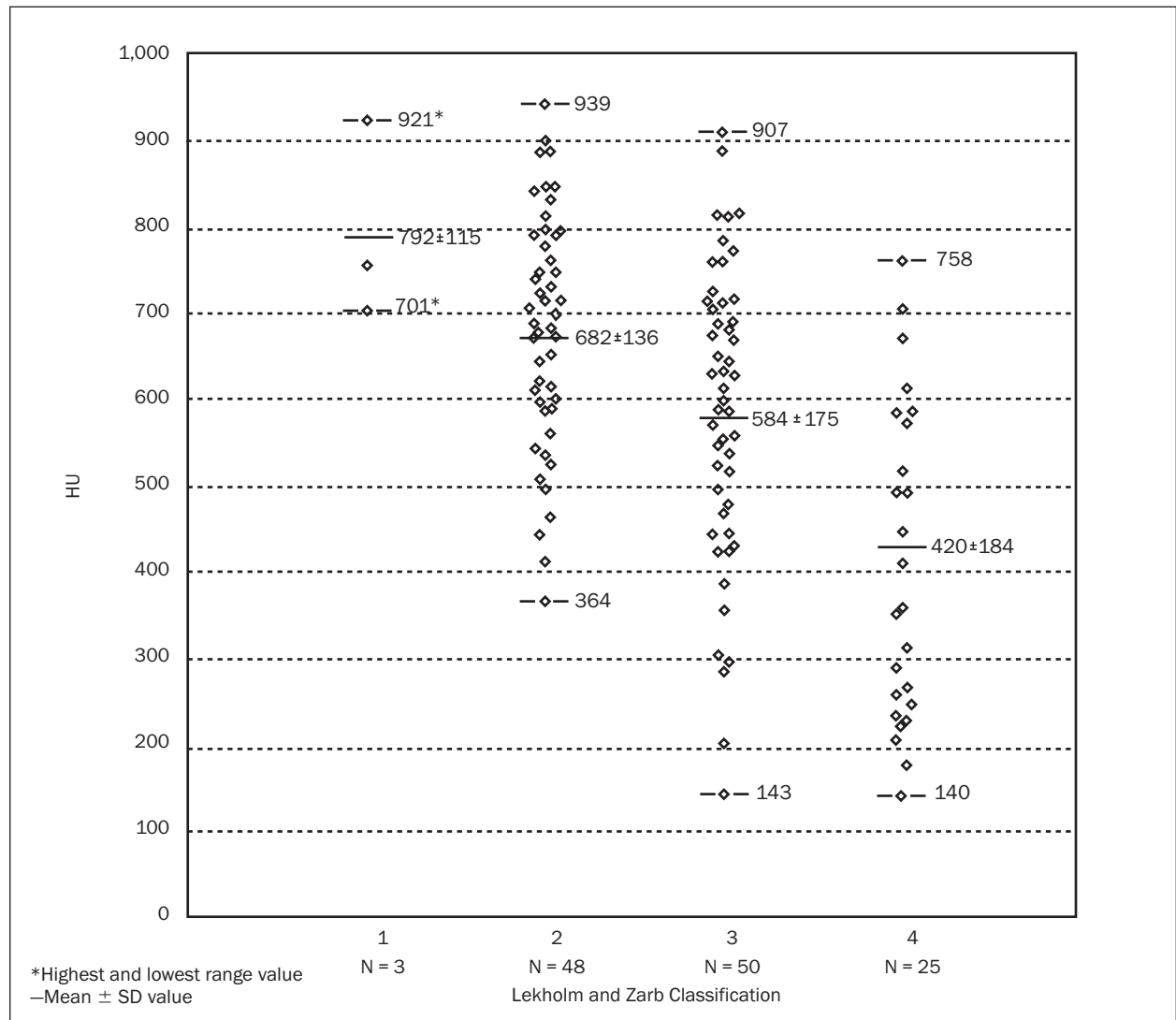


Fig 5 Scatter plot relating respective HU measurements and Lekholm and Zarb subjective classifications.

REFERENCES

- Adell R, Lekholm U, Rockler B, Brånemark P-I. A 15-year study of osseointegrated implants in the treatment of the edentulous jaw. *Int J Oral Surg* 1981;10:387-416.
- Adell R, Eriksson B, Lekholm U, Brånemark P-I, Jemt T. Long-term follow-up study of osseointegrated implants in the treatment of totally edentulous jaws. *Int J Oral Maxillofac Implants* 1990;5:347-359.
- Bass SL, Triplett RG. The effects of preoperative resorption and jaw anatomy on implant success. A report of 303 cases. *Clin Oral Implants Res* 1991;2:193-198.
- Jaffin RA, Berman CL. The excessive loss of Brånemark fixtures in type IV bone: A 5-year analysis. *J Periodontol* 1991;62:2-4.
- Friberg B, Jemt T, Lekholm U. Early failures in 4,641 consecutively placed Brånemark dental implants: A study from stage 1 surgery to the connection of completed prostheses. *Int J Oral Maxillofac Implants* 1991;6:142-146.
- Saadoun AP, LeGall ML. Clinical results and guidelines on Steri-Oss endosseous implants. *Int J Periodontics Restorative Dent* 1992;12:486-495.
- Jemt T. Implant treatment in elderly patients. *Int J Prosthodont* 1993;6:456-461.
- Bahat O. Treatment planning and placement of implants in the posterior maxillae: Report of 732 consecutive Nobelpharma implants. *Int J Oral Maxillofac Implants* 1993;8:151-161.
- Henry PJ, Bower RC, Wall CD. Rehabilitation of the edentulous mandible with osseointegrated dental implants: 10-year follow-up. *Aust Dent J* 1995;40:1-9.

10. Spiekerman H, Jansen VK, Richter EJ. A 10-year follow-up study of IMZ and TPS implants in the edentulous mandible using bar-retained overdentures. *Int J Oral Maxillofac Implants* 1995;10:231–243.
11. Jemt T, Lekholm U. Implant treatment in edentulous maxillae: A 5-year follow-up report on patients with different degrees of jaw resorption. *Int J Oral Maxillofac Implants* 1995;10:303–311.
12. Higuchi KW, Folmer T, Kultje C. Implant survival rates in partially edentulous patients: A 3-year prospective multicenter study. *J Oral Maxillofac Surg* 1995;53:264–268.
13. Lekholm U, Zarb GA. Patient selection and preparation. In: Brånemark P-I, Zarb GA, Albrektsson T (eds). *Tissue-Integrated Prostheses: Osseointegration in Clinical Dentistry*. Chicago: Quintessence, 1985:199–209.
14. Misch CE. Divisions of available bone in implant dentistry. *Int J Oral Implantol* 1990;7:17–21.
15. Johansson P, Strid KG. Assessment of bone quality from cutting resistance during implant surgery. *Int J Oral Maxillofac Implants* 1994;9:279–288.
16. Ames JR, Johnson RP, Stevens EA. Computerized tomography in oral and maxillofacial surgery. *J Oral Surg* 1980;38:145–149.
17. Rothman SLG, Chafetz N, Rhodes ML, Schwarz MS. CT in the preoperative assessment of the mandible and maxilla for endosseous implant surgery. *Radiology* 1988;168:171–175.
18. Weinberg LA. CT scan as radiologic data base for optimum implant orientation. *J Prosthet Dent* 1993;69:381–385.
19. Sethi A. Precise site location for implants using CT scans: A technical note. *Int J Oral Maxillofac Implants* 1993;8:433–438.
20. Falk A, Gielen S, Heuser L. CT data acquisition as a basis for modern diagnosis and therapy in maxillofacial surgery. *Int J Oral Maxillofac Surg* 1995;24:69–75.
21. Genant HK, Steiger P, Block JE, Glueer CC, Ettinger B, Harris ST. Quantitative computed tomography: Update 1987. *Calcif Tissue Int* 1987;41:179–186.
22. Cann CE. Quantitative CT for determination of bone mineral density: A review. *Radiology* 1988;166:509–522.
23. Lindh C, Nilsson M, Klinge B, Petersson A. Quantitative computed tomography of trabecular bone in the mandible. *Dentomaxillofac Radiol* 1996;25:146–150.
24. Norton MR, Gamble C. Bone classification: An objective scale of bone density using the computerized tomography scan. *Clin Oral Implants Res* 2001;12:79–84.
25. Shahlaie M, Gantes B, Schulz E, Riggs M, Crigger M. Bone density assessments of dental implant sites: I. Quantitative computed tomography. *Int J Oral Maxillofac Implants* 2003;18:224–231.
26. Mozzo P, Procacci C, Tacconi A, Martini PT, Andreis IA. A new volumetric CT machine for dental imaging based on the cone-beam technique: Preliminary results. *Eur Radiol* 1998;8:1558–1564.
27. Arai Y, Tammsialo E, Iwai K, Hashimoto K, Shinoda K. Development of a compact computed tomographic apparatus for dental use. *Dentomaxillofac Radiol* 1999;28:245–248.
28. Ito K, Yoshinuma N, Goke E, Arai Y, Shinoda K. Clinical application of a new compact computed tomography system for evaluating the outcome of regenerative therapy: A case report. *J Periodontol* 2001;72:696–702.
29. Fleckenstein P, Trantum-Jensen J. Techniques based on x-rays. In: Fleckenstein P, Trantum-Jensen J (eds). *Anatomy in Diagnostic Imaging*, ed 2. Copenhagen: Munksgaard, 2001:24–25.