

# Optimizing Esthetics for Implant Restorations in the Anterior Maxilla: Anatomic and Surgical Considerations

Daniel Buser, DMD, Prof Dr Med Dent<sup>1</sup>/William Martin, DMD, MS<sup>2</sup>/Urs C. Belser, DMD, Prof Dr Med Dent<sup>3</sup>

*The placement of dental implants in the anterior maxilla is a challenge for clinicians because of patients' exacting esthetic demands and difficult pre-existing anatomy. This article presents anatomic and surgical considerations for these demanding indications for implant therapy. First, potential causes of esthetic implant failures are reviewed, discussing anatomic factors such as horizontal or vertical bone deficiencies and iatrogenic factors such as improper implant selection or the malpositioning of dental implants for an esthetic implant restoration. Furthermore, aspects of preoperative analysis are described in various clinical situations, followed by recommendations for the surgical procedures in single-tooth gaps and in extended edentulous spaces with multiple missing teeth. An ideal implant position in all 3 dimensions is required. These mesiodistal, apicocoronal, and orofacial dimensions are well described, defining "comfort" and "danger" zones for proper implant position in the anterior maxilla. During surgery, the emphasis is on proper implant selection to avoid oversized implants, careful and low-trauma soft tissue handling, and implant placement in a proper position using either a periodontal probe or a prefabricated surgical guide. If missing, the facial bone wall is augmented using a proper surgical technique, such as guided bone regeneration with barrier membranes and appropriate bone grafts and/or bone substitutes. Finally, precise wound closure using a submerged or a semi-submerged healing modality is recommended. Following a healing period of between 6 and 12 weeks, a reopening procedure is recommended with a punch technique to initiate the restorative phase of therapy. INT J ORAL MAXILLOFAC IMPLANTS 2004;19(SUPPL):43-61*

**Key words:** bone augmentation, endosseous dental implantation, esthetic failures, guided bone regeneration, implant esthetics, implant position, surgical procedures

Over the past 10 years, dental esthetics has been an important issue in implant dentistry. At major conferences it is common to see lectures addressing various techniques for obtaining esthetic implant restorations. In the anterior maxilla, unsuccessful

treatment outcomes can lead to disastrous clinical situations that can only be corrected with removal of the implant and subsequent tissue augmentation procedures. With this in mind, it is important to establish sound clinical concepts with clearly defined parameters that lead to successful esthetics in the anterior maxilla, with long-term stability of the peri-implant tissues. This consensus article addresses these aforementioned concepts and parameters from an anatomic and surgical perspective.

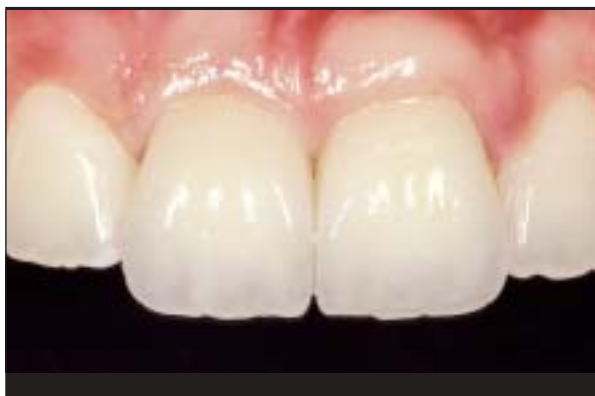Initiation of therapy starts with an understanding of the patient's desires. In most cases, the patient's primary demand is an esthetic tooth replacement offering a nice smile. For the dental clinician, the re-establishment of esthetics and function requires knowledge of all treatment modalities. Of the fixed options, conventional fixed partial dentures and implant-supported restorations should be objectively evaluated for their potential to provide long-term

<sup>1</sup>Professor and Chairman, Department of Oral Surgery and Stomatology, School of Dental Medicine, University of Berne, Switzerland.

<sup>2</sup>Clinical Assistant Professor, University of Florida, Center for Implant Dentistry, Departments of Oral and Maxillofacial Surgery and Prosthodontics, Gainesville, Florida.

<sup>3</sup>Professor and Chairman, Department of Fixed Prosthodontics and Occlusion, School of Dental Medicine, University of Geneva, Switzerland.

**Correspondence to:** Dr Daniel Buser, School of Dental Medicine, University of Berne, Freiburgstrasse 7, CH-3010 Berne, Switzerland. Fax: +41-31-632-9884. E-mail: daniel.buser@zmk.unibe.ch



**Fig 1** Various aspects of an esthetic implant restoration can be influenced by the implant surgeon: a harmonious gingival line without abrupt changes in tissue height, intact papillae, and a convex contour of the facial aspect of the alveolar process.

function and stability in a given situation. Today, implant-supported restorations often represent the best solution, because intact tooth structure and supporting tissues can be preserved.

Esthetic parameters that have been defined for conventional dental restorations<sup>1,2</sup> can also be used for implant patients during preoperative planning. These parameters can help define potential risk factors for esthetic shortcomings. The main esthetic objectives of implant therapy from a surgical point of view are the achievement of a harmonious gingival margin without abrupt changes in tissue height, maintaining intact papillae, and obtaining or preserving a convex contour of the alveolar crest<sup>3-5</sup> (Fig 1).

Implant therapy in the anterior maxilla is challenging for the clinician because of the esthetic demands of patients and difficult pre-existing anatomy. In this area of the mouth, the clinician is often confronted with tissue deficiencies caused by various conditions. These conditions can be divided into 2 categories: anatomic and pathologic (Table 1).

Tissue deficiencies often require bone augmentation procedures such as the guided bone regeneration (GBR) technique, which uses a simultaneous or staged approach to regenerate adequate volumes of bone to allow for implant placement.<sup>6</sup> Soft tissue handling, precise implant placement in a restorative-driven 3-dimensional approach,<sup>7</sup> and follow-up procedures represent a variety of challenges for the implant surgeon.

To help categorize the difficulty level of a given treatment, in 1999 the Swiss Society of Oral Implantology proposed a system for classifying implant patients from surgical and prosthetic points of view. In the SAC classification system, the S rep-

**Table 1 Clinical Conditions Presenting Tissue Deficiencies in the Anterior Maxilla**

Conditions	Remarks
Anatomic	
Narrow alveolar crest and/or facial undercut of alveolar process	Congenitally missing teeth
Pathologic	
Dental trauma	Tooth avulsion with fracture of the facial bone plate
Posttraumatic conditions	Root ankylosis with infraocclusion, root resorption, root fractures
Acute or chronic infections	Periodontal disease, periapical lesions, endo/perio lesions
Disuse bone atrophy	Long-standing tooth loss

resents simple, A advanced, and C complex treatment procedures. In the surgical classification, all esthetic indications have been placed in either the A or C category, acknowledging the challenging clinical conditions often present in the anterior maxilla and the frequent need for bone augmentation procedures (Table 2).

To successfully meet the challenges of esthetic implant dentistry in daily practice, a team approach is advantageous and highly recommended. The team includes an implant surgeon, a restorative clinician, and a dental technician who preferably has advanced knowledge and clinical experience. In special situations, an orthodontist can supplement the team. The successful implant surgeon working in the esthetic zone should have a good biologic understanding of tissue response to implant placement, a thorough surgical education enabling performance of precise and low-trauma surgical procedures, and a large patient pool providing sufficient surgical experience with esthetic implant placement.

## POTENTIAL CAUSES OF ESTHETIC IMPLANT FAILURE

### Anatomic Factors

It is important for the clinician to understand that ridge anatomy includes the soft tissues and the supporting bone in all dimensions, and that soft tissue contours around an implant are heavily influenced by the bone anatomy. In recent years, numerous experimental studies have revealed that the concept of *biologic width*, once described for natural teeth,<sup>8</sup> can also be applied to osseointegrated implants,

**Table 2 Surgical SAC Classification\* of Implant Sites With or Without Bone Deficiencies**

	Simple	Advanced	Complex
Sites without bone defects	<ul style="list-style-type: none"> <li>• Edentulous mandible with 2 implants for a removable denture (ball attachment or bar)</li> <li>• Distal-extension situation maxilla/mandible</li> <li>• Extended edentulous gap in posterior maxilla/ mandible</li> <li>• Extended edentulous gap in anterior mandible</li> <li>• Single-tooth gap in posterior area</li> <li>• Single-tooth gap in anterior mandible</li> </ul>	<ul style="list-style-type: none"> <li>• Edentulous mandible with 4 to 6 implants for a bar-supported prosthesis or full-arch prosthesis</li> <li>• Edentulous maxilla for removable denture</li> <li>• Single-tooth gap in anterior maxilla</li> <li>• Extended edentulous gap in anterior maxilla</li> </ul>	<ul style="list-style-type: none"> <li>• Edentulous maxilla for a fixed full-arch prosthesis</li> </ul>
Sites with bone defects	<ul style="list-style-type: none"> <li>• None</li> </ul>	<ul style="list-style-type: none"> <li>• Implants with simultaneous membrane application</li> <li>• Implants placed with osteotome technique</li> <li>• Implants combined with "bone splitting" of the alveolar crest</li> </ul>	<ul style="list-style-type: none"> <li>• All 2-stage bone augmentation procedures</li> <li>• Sinus floor elevation with the window technique</li> <li>• Combined bone and soft tissue augmentation procedures</li> </ul>

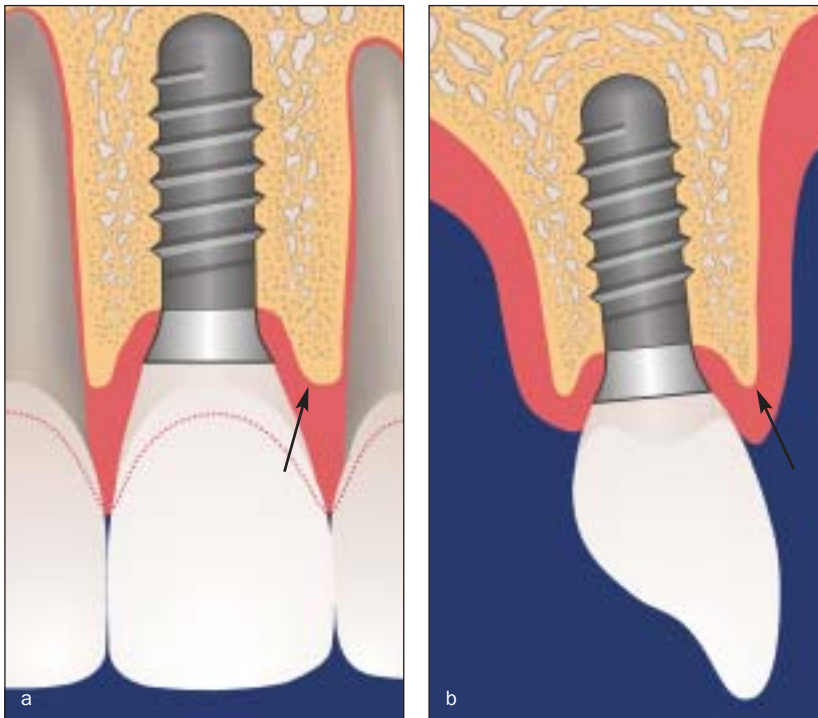
\*Classification of the Swiss Society of Oral Implantology (1999).

because the soft tissues also demonstrate relatively constant dimensions around implants.<sup>9-13</sup> These animal studies have demonstrated a relatively constant thickness of the peri-implant soft tissues of approximately 3 mm. The biologic width of the peri-implant mucosa comprises the zone of supracrestal connective tissue, which measures approximately 1 mm, and the epithelial structures, including the junctional and sulcular epithelium, which measure about 2 mm in height.<sup>11,13,14</sup> It should be noted that the thickness of about 3 mm was measured around implants without adjacent teeth. In patients, the soft tissues in interproximal areas are thicker because of the papillae that form at the contact point to support the emerging restoration. In addition, clinical studies have also demonstrated that there are some differences in soft tissue thickness among different gingival biotypes.<sup>15</sup> A *thin biotype*, with a highly scalloped gingival architecture, has a reduced soft tissue thickness when compared with a *thick biotype* featuring blunted contours of the papillae.<sup>15,16</sup>

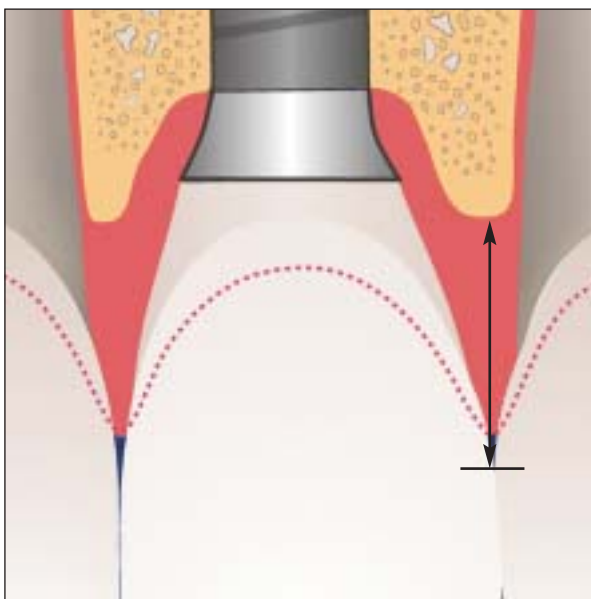
Keeping these relatively constant dimensions of peri-implant soft tissues in mind, the underlying bone structure plays a key role in the establishment of esthetic soft tissues in the anterior maxilla. Two anatomic structures are important: the bone height of the alveolar crest in the interproximal areas and the height and thickness of the facial bone wall (Figs 2a and 2b). The interproximal crest height plays a role in the presence or absence of peri-implant papillae. A clinical study around teeth<sup>17</sup> demonstrated that a distance of 6 mm or more from the

alveolar crest to the contact point reduces the probability of intact papillae (Fig 3). This observation has been confirmed with implant-supported restorations.<sup>18</sup> It has also been shown that the height of peri-implant papillae in single-tooth gaps is independent of the proximal bone level next to the implant but is dependent on the interproximal bone height of the adjacent teeth.<sup>15</sup> Clinical situations with reduced vertical bone on adjacent teeth are challenging, because there are currently no surgical techniques available to predictably regain lost crest height. In an attempt to regain this lost tissue, orthodontic tooth extrusion techniques have been proposed.<sup>19,20</sup> However, no clinical studies with long-term results have been presented to date. To detect patients at risk for short peri-implant papillae, a detailed preoperative analysis of crest height of the adjacent teeth is necessary. It is important to openly discuss treatment limitations with the patient prior to therapy to avoid unrealistic expectations.

Having a facial bone wall of sufficient height and thickness is important for long-term stability of harmonious gingival margins around implants and adjacent teeth.<sup>4,21</sup> In daily practice, implant patients frequently present with a bone wall that is missing or of insufficient height and/or thickness because of the various causes of tooth loss (Table 1). Attempts to place implants in sites with facial bone defects in the absence of bone reconstruction will frequently result in soft tissue recession, potentially exposing implant collars and leading to loss of the harmonious gingival margin.



**Fig 2** Esthetic peri-implant soft tissues significantly depend on 2 supporting bone structures: (a) the height of the alveolar crest at adjacent teeth, and (b) the height and thickness of the facial bone wall.



**Fig 3** The presence or absence of a peri-implant papilla mainly depends on the distance (H) between the alveolar crest and the contact point. In single-tooth gaps, the bone height at adjacent teeth determines the status of the papilla.

Various surgical techniques have been proposed in the past 15 years to correct such bone defects at the facial aspect of potential implant sites, including onlay grafting,<sup>22-24</sup> GBR using barrier membranes,<sup>25-29</sup> a combination of block bone grafts and barrier membranes,<sup>30,31</sup> and most recently distraction osteogenesis.<sup>32-34</sup> From a scientific point of

view, the GBR technique is a well-documented procedure that can be used with either a simultaneous or a staged approach.<sup>6,25</sup> Clinical studies and experience demonstrate that horizontal bone augmentation can be predictably obtained with the GBR technique,<sup>30</sup> whereas with vertical bone augmentation, a clearly more difficult procedure, it is more difficult to obtain successful results.<sup>35,36</sup>

### Iatrogenic Factors

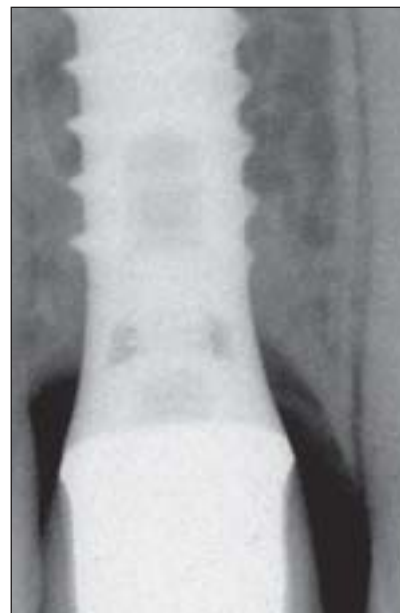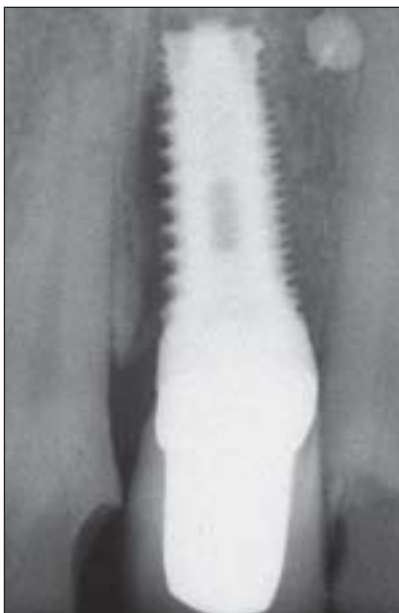
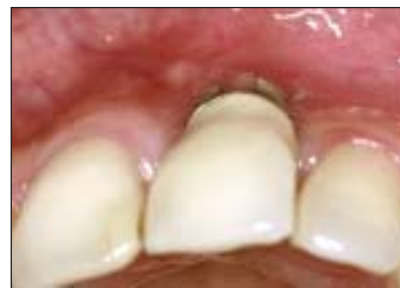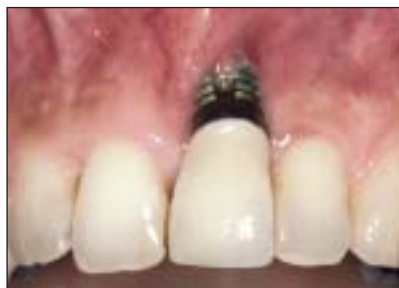Esthetic failures can also be caused by inappropriate implant positioning and/or improper implant selection. Placement of implants in a correct 3-dimensional position is a key to an esthetic treatment outcome regardless of the implant system used. This position is dependent on the planned restoration that the implant will support. The relationship of the position between the implant and the proposed restoration should be based on the position of the implant shoulder, because this will influence the final hard and soft tissue response. The implant shoulder position can be viewed in 3 dimensions: orofacial, mesiodistal, and apicocoronal. In the orofacial direction, an implant shoulder placed too far facially will result in a potential risk for soft tissue recession, because the thickness of the facial bone wall is clearly reduced by the malpositioned implant (Fig 4). In addition, potential prosthetic complications could result in restoration-implant axis problems, making the implant difficult to restore. Implants positioned too far palatally can result in emergence problems, as

**Fig 4a** (Left) Esthetic failure of an implant crown. The implant was placed immediately into an extraction socket. Following implant restoration, significant soft tissue recession developed within a few months, exposing the implant surface.

**Fig 4b** (Right) The occlusal view clearly demonstrates that the implant shoulder is located too far facially in the danger zone. This malposition was aggravated by the selection of a wide-platform implant.

**Fig 4c** (Left) The periapical radiograph shows an osteolytic lesion at the mesial aspect of the implant. The diameter of the implant shoulder is clearly too large.

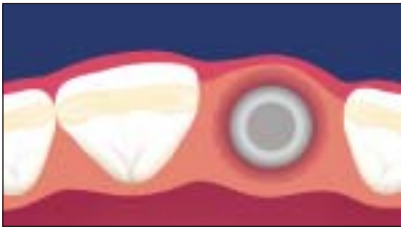
**Fig 5** (Right) Following implant restoration, some peri-implant bone resorption is routinely seen on periapical radiographs. This bone "saucer" has a vertical component of about 1.5 to 2.0 mm and a horizontal component of at least 1.0 mm.



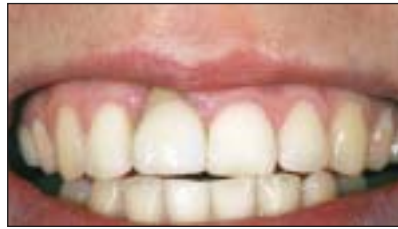seen with ridge-lap restorations. These restorations can be unesthetic and extremely difficult to maintain, and should therefore be avoided.<sup>3,4,37,38</sup>

Improper mesiodistal positioning of implants can have a substantial effect on the generation of interproximal papillary support as well as on the osseous crest on the adjacent natural tooth. Placement of the implant too close to the adjacent tooth can cause resorption of the interproximal alveolar crest to the level of that on the implant.<sup>39,40</sup> With this loss of the interproximal crest height comes a reduction in the papillary height. Restorative problems exist as well. Poor embrasure form and emergence profile will result in a restoration with a long contact zone and compromised clinical outcomes. The loss of crest height on adjacent teeth is caused by the bone saucerization routinely found around the implant shoulder of osseointegrated implants. This saucerization comprises 2 dimensions: horizontal and vertical. Radiographs demonstrate that the horizontal dimension of the proximal bone saucerization measures about 1.0 to 1.5 mm from the implant surface.<sup>41</sup> This minimal distance needs to be respected on implant placement to prevent vertical bone loss on adjacent teeth.

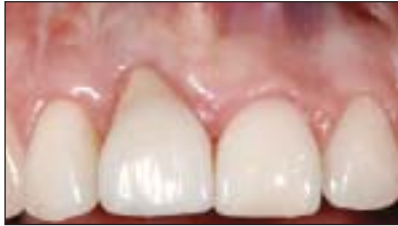This saucerization can also play a role with regard to the apicocoronal position of the implant shoulder. If the implant is placed too far apically using extensive countersinking procedures, the vertical dimension of the bone saucerization will lead to unnecessary bone loss. This vertical dimension amounts to approximately 2 mm in interproximal areas when measured from the implant shoulder (Figs 3 and 5). This radiographic observation routinely seen in patients<sup>39</sup> was confirmed by experimental studies.<sup>14,42-44</sup> These studies demonstrated that the position of the implant/abutment interface, often called the microgap, has an important influence on the hard and soft tissue reactions around osseointegrated implants. The more apically the microgap was located, the more bone resorption was observed. The extent of vertical bone resorption measured between 1.3 and 1.8 mm in these animal studies. Clinically, if an implant is placed with an excessive countersinking procedure, an unnecessary amount of bone loss will occur. Because this resorption will take place circumferentially (Fig 6), it will affect not only the proximal bone structure but also the height of the facial bone wall and can lead to undesired soft



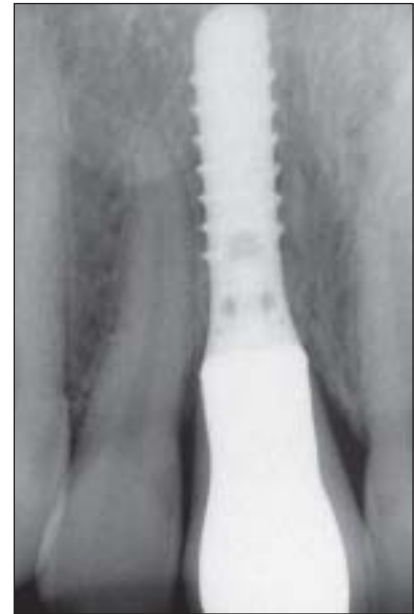**Fig 6** (Above) This peri-implant bone “saucer” is a circumferential phenomenon and can lead to a partial resorption of the facial bone wall, with subsequent soft tissue recession.



**Fig 7a** (Top center) Compromised esthetic result in a young female patient with a high lip line. Clinical status 4 months following implant restoration.

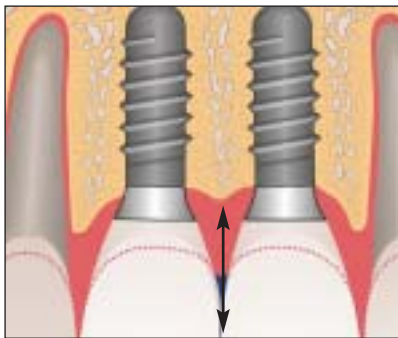


**Fig 7b** (Right) The detailed view clearly shows the loss of a harmonious gingival line following soft tissue recession at the implant crown.

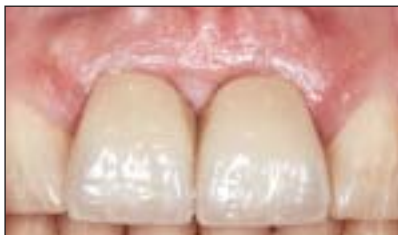

**Fig 7c** (Far right) The periapical radiograph demonstrates the cause of the esthetic failure: The implant shoulder was positioned too far apically, which led to the resorption of the facial bone wall.

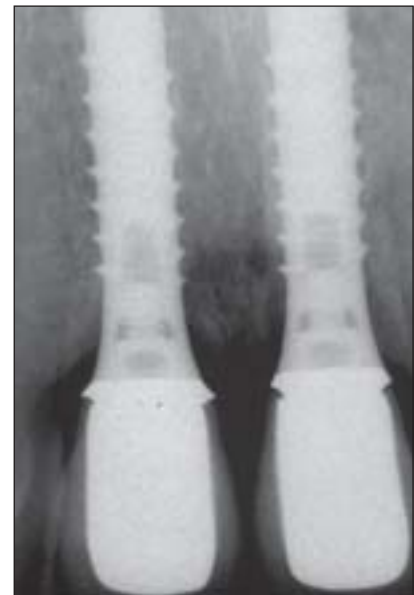**Fig 8a** (Top left) Schematic diagram of a situation with two adjacent implants. The “saucer” developed around both implants and led to a flattening between both implants, resulting in a distance (H) that clearly exceeds 5 mm.



**Fig 8b** (Bottom left) Clinical status of 2 adjacent implants in central incisors. The interimplant papilla is approximately 2 mm shorter than adjacent papillae because of the bone resorption between the 2 implants. The short papilla is nicely compensated with prosthetic means, such as a long interproximal contact line.



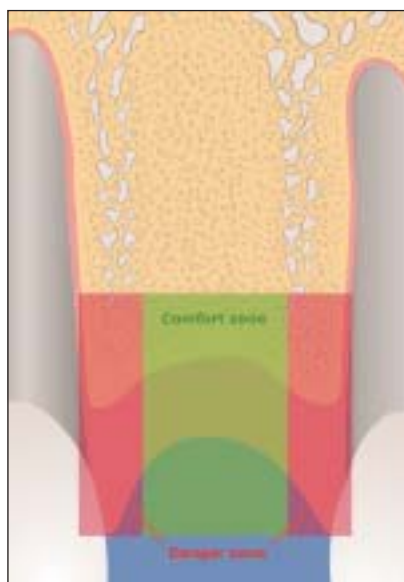
**Fig 8c** (Right) The periapical radiograph 6 years following implant placement shows the reduction in crest height between the 2 implants.



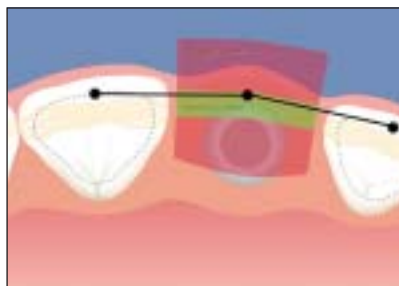
tissue recession. Restoratively, long clinical crowns, pink porcelain, or visible metal margins will result, compromising the esthetic treatment outcome (Figs 7a to 7c). This phenomenon is also important in sites with 2 adjacent implants because the interimplant bone will be resorbed, leading to a shortened interimplant papilla<sup>41</sup> (Figs 8a to 8c).

Esthetic failures can also be caused by improper implant selection, mainly because of the use of oversized implants. The use of “tooth-analogous”

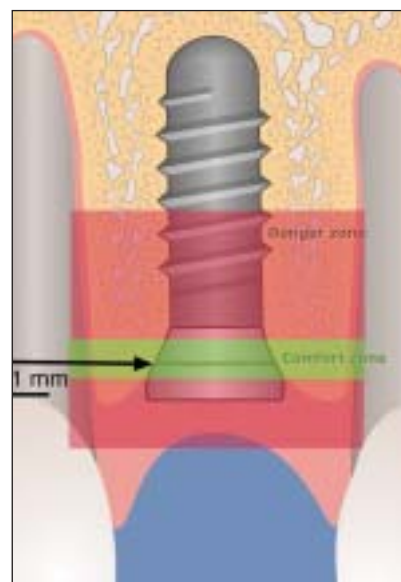
implant diameters based solely on the mesiodistal dimension of the tooth to be replaced should be avoided. With such wide-platform or wide-neck implants, the implant shoulder may be too close to adjacent teeth and too far facially, leading to the above-mentioned complications. In the case of adjacent implant placement, wide-platform implants will reduce the amount of interimplant bone and increase the risk of extensive interimplant bone loss.



**Fig 9a** Correct implant position in the mesiodistal dimension. The implant shoulder should be positioned within the comfort zone, avoiding the danger zones, which are located close to adjacent root surfaces. The danger zone is about 1.0 to 1.5 mm wide.



**Fig 9b** Correct implant position in the orofacial dimension. The implant shoulder is positioned about 1 mm palatal to the point of emergence at adjacent teeth. The danger zone is clearly entered when the implant is placed too facially; this can cause resorption of the facial bone wall with subsequent recession. A second danger zone is located too far palatally, which can require an implant crown with a ridge-lap design.



**Fig 9c** Correct implant position in the apicocoronal dimension. The implant shoulder is positioned about 1 mm apical to the CEJ of the contralateral tooth in patients without gingival recession. The danger zone is entered when the implant is placed too far apically using excessive countersinking, or too far coronally, which results in implant shoulder exposure at the mucosa.

## IDEAL IMPLANT PLACEMENT IN THE ANTERIOR MAXILLA

As previously mentioned, esthetic implant placement is based on a restorative-driven philosophy.<sup>3-5,7,45</sup> Correct 3-dimensional positioning of the planned implant restoration is the driving force in implant placement. This will allow for optimal support and stability of the peri-implant hard and soft tissues. In the anterior maxilla, the following implant types are recommended for clinical use: standard screw, wide body, narrow neck, TE 4.1/4.8, and TE 3.3/4.8 (Institut Straumann, Waldenburg, Switzerland). These implants differ in restorative shoulder and implant thread dimensions. To utilize these implants successfully in the anterior maxilla, correct implant selection relative to the mesiodistal dimension of the tooth to be replaced is critical. In this article, this dimension is referred to as *gap size*.

When planning for an ideal 3-dimensional implant position, a distinction is made between so-called “comfort” and “danger” zones in each dimension. Selection and placement of the dental implant should be based on the planned restoration in these zones. If the implant shoulder is positioned within the danger zones, one of the above-mentioned complications could occur, potentially resulting in

esthetic shortcomings. Implants positioned in the comfort zones provide the basis for an esthetic restoration. Comfort and danger zones are defined in mesiodistal, orofacial, and apicocoronal dimensions. In the mesiodistal dimension, the danger zones are located next to adjacent teeth. At present, it is not clear how wide these danger zones are. Previous publications recommended that the implant shoulder and the adjacent root surface be at least 1 mm apart.<sup>21</sup> With the tulip shape of the implant shoulder on Straumann implants, this would place the implant body surface no closer than 1.5 mm to the adjacent root surface (Fig 9a). With this in mind, the minimal gap size for implant selection in the anterior maxilla, based upon the implant shoulder, can be defined (Table 3). Wide-neck implants, with their 6.5-mm shoulder diameter, are not recommended for use in the anterior maxilla. Their implant shoulder margin is likely to be located too close to adjacent teeth or too far facially, entering into the respective danger zones.

With regard to the orofacial dimension, it has been proposed that the position of the implant shoulder margin should be at the ideal point of emergence.<sup>3,4</sup> The facial danger zone is located anywhere facially to the imaginary line highlighted from the point of emergence of the adjacent teeth

**Table 3 Relationship Between the Mesiodistal Gap Size and the Diameter of the Implant Shoulder (Straumann Dental Implant System)**

Implant type	Shoulder diameter (mm)	Minimal gap size (mm)	Ideal gap size (mm)
Standard screw (S 4.1)	4.8	7.0	8.0 to 9.0
Wide-body (S 4.8)	4.8	7.0	8.0 to 9.0
Narrow-neck (NN 3.3)	3.5	5.5	6.0 to 7.0
TE (TE 3.3/4.8)	4.8	7.0	8.0 to 9.0
TE (TE 4.1/4.8)	4.8	7.0	8.0 to 9.0

**Table 4 Risk Factors in Implant Patients**

Risk factors	Remarks
Medical	Severe bone disease causing impaired bone healing Immunologic disease Medication with steroids Uncontrolled diabetes mellitus Irradiated bone Others
Periodontal	Active periodontal disease History of refractory periodontitis Genetic disposition
Smoking habits	Light smoking (< 10 cigarettes per d) Heavy smoking (≥ 10 cigarettes per d)
Oral hygiene/compliance	Home care measured by gingival indices Personality, intellectual aspects
Occlusion	Bruxism

and/or planned restoration (Fig 9b). The palatal danger zone starts about 2 mm from this point of emergence and leads to an increased risk of a ridge-lap restoration. Placement of the implant orofacially in the comfort zone, which is located anywhere in between these areas, will allow for a restoration with the proper emergence profile to maintain the harmonious scalloping of the gingival margins.

The apicocoronal positioning of the implant shoulder follows the philosophy “as shallow as possible, as deep as necessary,” as a compromise between esthetic and biologic principles. As agreed upon at the last ITI consensus meeting, the position of the implant shoulder should be approximately 2 mm apical to the midfacial gingival margin of the planned restoration.<sup>21</sup> This can be accomplished through the use of surgical templates that highlight the gingival margin of the planned restoration. In patients without vertical tissue deficiencies, the use of periodontal probes leveled on the adjacent cemento-enamel junction (CEJ) in single-tooth gaps has proven to be a valid alternative.<sup>21</sup> It is important to note that the CEJs of adjacent teeth can vary,

depending on the tooth to be replaced, and must be taken into consideration.<sup>46</sup> In particular, lateral incisors are smaller and their CEJ is normally located more coronally than the CEJs of central incisors or canines. Implant placement within the apical danger zone (located anywhere 3 mm or more apical to the proposed gingival margin) can result in undesired facial bone resorption and subsequent gingival recession. The coronal danger zone is invaded with a supragingival shoulder position, leading to a visible metal margin and poor emergence profile (Fig 9c). Respecting the comfort zones in 3 dimensions results in an implant shoulder located in an ideal position, allowing for an esthetic implant restoration with stable, long-term peri-implant tissue support.

## PREOPERATIVE ANALYSIS

### Risk Assessment

In each patient, a detailed preoperative analysis should be performed to assess the individual risk profile and the level of difficulty of the planned therapy. Risk assessment in the anterior maxilla of potential implant patients includes several aspects (Table 4). The goal of risk assessment is to identify patients whose implant therapy carries a high risk of a negative outcome. Among the listed factors, patients with increased periodontal susceptibility and/or a history of a rapidly progressing or refractory periodontitis should be identified, because there is increasing evidence in the literature that these patients have an increased risk of biologic complications around osseointegrated implants.<sup>47,48</sup> In the past 5 years, genetic testing using a swab has been recommended to identify positive interleukin-1 (IL-1) genotype patients, because these patients have an increased risk of developing periodontitis.<sup>49-51</sup> It seems that the combination of an IL-1-positive genotype and smoking further increases this risk.<sup>52,53</sup> Smoking is also an important risk factor for implant complications. Several clinical studies have demonstrated increased failure rates for smokers either during the healing or the follow-up period.<sup>54-57</sup> Recently published studies have provided the first evidence that the combination of positive IL-1 genotype and smoking also has a negative synergistic effect on peri-implant tissues, because increased bone loss and a higher frequency of biologic complications have been noted.<sup>58-60</sup> Thus, the identification of patients with a history of periodontitis combined with smoking is important during preoperative analysis, because these patients are clearly at risk for the development of biologic peri-implant complications.



### Anatomic Site Analysis: General Remarks

An optimal esthetic implant restoration depends on 4 anatomic and surgical parameters: (1) submucosal positioning of the implant shoulder, (2) adequate 3-dimensional implant positioning, (3) long-term stability of esthetic and peri-implant soft tissue contours, and (4) symmetry of clinical crown volumes between the implant site and contralateral teeth.<sup>3,4</sup> With this in mind, implant placement in an optimal position begins with a restorative plan and an anatomic assessment of the single- or multiple-tooth gap (Table 5).

Assessment begins extraorally and includes the patient's smile. A keen eye is needed to determine if the smile is natural. Patients with unacceptable tooth health, shade, or position may not give a full smile when asked. Previous photographs of the patient and family interviews may help to determine the natural position of the patient's lip during a smile. As expected, patients with a high lip line will show more tissue and will require maximal efforts to maintain peri-implant tissue support throughout the planning, provisional, surgical, and restorative phases.

The dental midline, tooth size, and shade should be recorded. The intraoral exam should document excessive or irregular gingival tissue, crowding, and asymmetric teeth (eg, peg laterals), in addition to including a thorough periodontal and radiographic charting. It is paramount that orthodontic and periodontal esthetic problems be addressed either prior to or during implant rehabilitation. Tissue shaping—whether excessive or deficient—should be managed with a restorative plan by experienced clinicians.

Characteristics of the soft tissue biotype<sup>15,16</sup> will play a prominent role in planning for final shoulder position of the implant. A thin biotype with highly scalloped tissue will require the implant body and shoulder to be placed more palatal to mask any titanium show-through. When implants are placed toward the palate, a slightly deeper placement (within the apicocoronal comfort zone) is required to allow for a proper emergence profile of the restoration. Adjacent implant placement challenges the treatment team's ability to place dental implants in a position that allows for subgingival shoulder location and an ideal emergence profile while maximizing the osseous crest height. In general, a patient with the combination of a high lip line and a thin biotype is extremely difficult to treat and should be considered an anatomic risk. Patients who fit into these treatment categories should be made aware of the challenges involved in obtaining an esthetic result before treatment begins.

Once the extraoral examination has been completed, a vision of the emergence and position of the

**Table 5 Anatomic Site Analysis in the Anterior Maxilla**

Factor	Areas for analysis
Location of the smile line	<ul style="list-style-type: none"> <li>• High lip line</li> <li>• Medium lip line</li> <li>• Low lip line</li> </ul>
Gingival morphotype	<ul style="list-style-type: none"> <li>• Thin with highly scalloped gingiva</li> <li>• Thick with shallow scalloped gingiva</li> </ul>
Interocclusal relationship	<ul style="list-style-type: none"> <li>• Horizontal overlap</li> <li>• Vertical overlap</li> </ul>
Dimensions of edentulous gap	<ul style="list-style-type: none"> <li>• Mesiodistal gap size</li> <li>• Multiple missing tooth dimensions</li> </ul>
Anatomy of alveolar crest	<ul style="list-style-type: none"> <li>• Horizontal bone deficiency</li> <li>• Vertical bone deficiency</li> </ul>
Status of adjacent dentition	<ul style="list-style-type: none"> <li>• Crown integrity</li> <li>• Endodontic status</li> <li>• Periodontal status</li> </ul>
Radiographic status	<ul style="list-style-type: none"> <li>• Vertical bone height</li> <li>• Anatomic structures (eg, nasopalatal canal)</li> <li>• Position and axis of adjacent roots</li> <li>• Radiolucencies in alveolar process</li> <li>• Foreign bodies in alveolar process</li> </ul>

definitive implant-supported restoration is vital for the diagnosis of hard and soft tissue deficiencies prior to implant placement. Retention of the restoration, whether with cement or screws, will play a role in positioning of the shoulder of the implant to allow for sufficient peri-implant tissue support and proper crown emergence. The use of diagnostic waxups and templates for determination of anatomic comfort and danger zones in the planning process will provide the team members with information that can help maximize esthetic outcomes. With this vision of the definitive restoration in hand, a comprehensive anatomic site analysis is possible.

### Anatomic Site Analysis in Single-Tooth Gaps

As mentioned earlier, the single-tooth gap in the anterior maxilla is assessed in 3 dimensions based on a planned restoration and the surrounding teeth. Single-tooth sites offer less of a challenge because of the ability to use the adjacent teeth as landmarks in planning. With this in mind, several key analyses must still take place prior to commencing with implant placement. A diagnostic waxup highlighting tissue deficiencies and final tooth positioning can assist in this planning process.

One of the first things to be assessed is orofacial ridge anatomy, including whether there is sufficient

crest width and the presence or absence of facial bone atrophy. Deficient alveolar crest width and/or facial bone atrophy require a bone augmentation procedure so that the implant can be positioned in a correct orofacial position. Depending on the extent and morphology of the bone defect, a simultaneous or staged approach is necessary. Clinical sounding and sophisticated radiographic techniques such as conventional tomograms, dental computerized tomograms (CTs) or volume CTs can assist in diagnosing deficiencies in this dimension.

Mesiodistally, the space should be equal to that of the adjacent tooth (centrals) or the contralateral tooth (laterals and canines). Excesses or deficiencies in these dimensions must be addressed through the use of orthodontics, enameloplasty, or restorative materials prior to implant placement. For patients with diastemas, it is necessary to decide whether to eliminate or maintain the space prior to implant placement, as this will affect the mesiodistal shoulder position. Guidelines for implant selection based on gap size can be found in Table 3.

The most critical assessment remains the apico-coronal dimension. Deficient tissue in this dimension can result from several factors: periodontal disease of the adjacent tooth/teeth, atrophy, trauma, infection, or a congenital abnormality. A tissue deficit in this dimension must be addressed and managed carefully throughout the course of treatment. Because of the complexity of vertical hard/soft tissue grafting, patients with this condition are placed in a high anatomic risk group. Patients with excess tissue height require attention as well. A bone-scalloping procedure will be required to allow placement of the implant shoulder in a subgingival position. The most efficient way to examine this position is through the use of a template highlighting the proposed gingival margin position of the implant restoration.

Interocclusal space must be addressed for reasons in addition to the obvious ones. Placing the long axis of the implant through the incisal edge of anterior teeth is beneficial for patients with excessive vertical overlap. A diagnostic waxup will highlight the potential difficulties in restoring the proposed implant and managing the patient's occlusion. Prior to placement of the dental implant, a radiographic survey should be performed. A radiographic template outlining the proposed implant position in the orofacial and mesiodistal dimensions with a metallic rod will help determine if the implant will interfere with adjacent tooth structure or vital anatomy.<sup>45</sup> Magnification and distortion of the imaging technique can be taken into account by inserting the known dimensions of the rod into the template.

Determination of the location of the nasopalatine foramen and the distance to the adjacent teeth and the floor of the nose are necessary for proper implant selection. If sectional imaging is not necessary, the periapical radiograph will generally provide sufficient information, with greater accuracy than a panoramic radiograph.<sup>61</sup> Proper anatomic site analysis in conjunction with restorative-driven planning will optimize predictable esthetic results in the maxillary single-tooth gap.

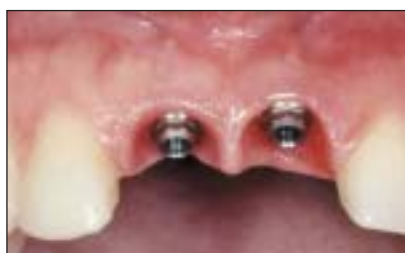### **Anatomic Site Analysis in Extended Edentulous Spaces**

Patients with extended edentulous spaces present additional anatomic challenges, making it even more difficult to produce an esthetic result with any certainty. Varying clinical situations such as missing centrals, central and lateral, lateral and canine, or even several anterior teeth are possible, leading to an array of treatment obstacles. With the loss of an adjacent tooth or teeth, planning for implant placement will require a diagnostic waxup based on sound esthetic principles, tooth morphology, and occlusal schemes. Understanding the fundamental objectives in the anterior esthetic zone—such as tooth axis, interdental closure, gingival contours, balance of gingival levels, interdental contacts, tooth dimensions, and tooth form—will help produce a waxup that will dictate to the surgeon the goals necessary for replacement of the missing teeth and tissue.<sup>46</sup>

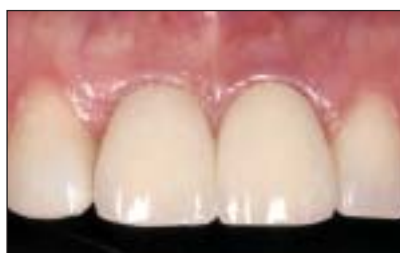The replacement of 2 missing central incisors with dental implants can often lead to an acceptable esthetic result because of the symmetric gingival margin positions and the ability to form an interimplant papilla with the redundant nasopalatine tissue commonly found in that region. Placement of the implants in a strict apicocoronal position honoring the maxim “as shallow as possible, as deep as necessary” will help maintain the interimplant crest height and provide support for the peri-implant tissues (Figs 10a to 10c).

Patients with a thin gingival morphotype will be challenging because the implants will need to be placed closer to the palate and deeper to provide for proper emergence, thus increasing the potential for loss of interimplant tissue and resulting in a “black triangle” and/or broad contact points. Patients who are missing a central and a lateral incisor or a lateral incisor and a canine are clinically more challenging because the edentulous space is smaller and the interimplant soft tissue tends to be less voluminous (Figs 11a to 11c).

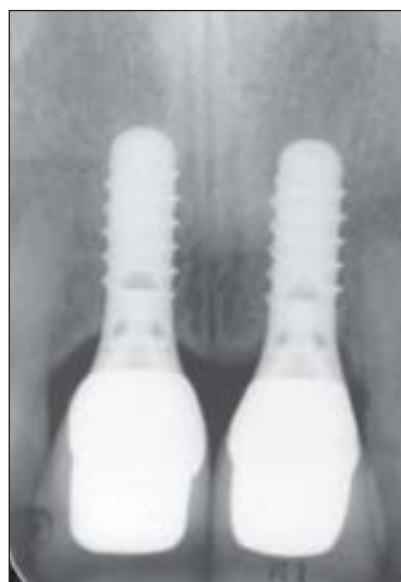
Replacement of several missing teeth with implants allows for the use of fixed partial dentures



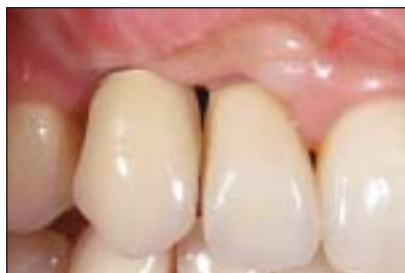**Fig 10a** (Above) Two implants were placed in central incisor positions following the principle “as shallow as possible, as deep as necessary” to maintain as much of the interimplant papilla as possible.



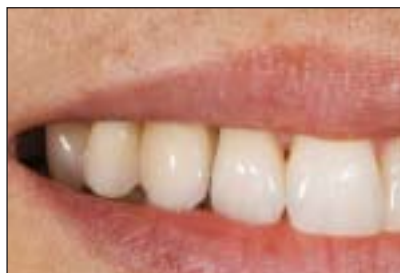**Fig 10b** (Center) Final treatment outcome shows a pleasing result, since the interimplant papilla was well maintained.



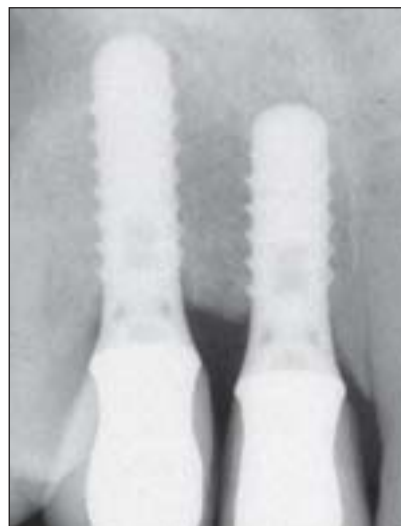
**Fig 10c** (Right) Periapical radiograph, taken 3 years after implant placement, shows minimal bone resorption around both implants.



**Fig 11a** (Left) The esthetic result with 2 adjacent implants in the central and lateral positions is compromised because of a short interimplant papilla.



**Fig 11b** (Center) The esthetic result was still acceptable since the patient had a low lip line.



**Fig 11c** (Right) The radiograph at the 5-year examination shows stable bone crest levels with a flat bone crest between both implants.

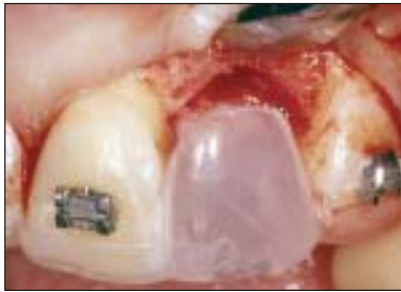and the opportunity to use ovate pontics to help support the tissues and form pseudo-papillae. Questions arise when bone augmentation procedures have been performed previously and pontics are used to restore the sites. Will the bone remain, or is there a need to place an implant in these sites to maintain the bone? Replacement of several missing teeth—eg, lateral-central-central-lateral—with implants requires maximizing placement in all 3 dimensions, avoiding embrasures, supragingival shoulders, and irregular gingival margins. Implant selection becomes critical, because the implant needs to provide for emergence as well as maintain peri-implant hard tissue support.

Following the template and planning procedures previously mentioned should allow the clinician to maximize the potential for an acceptable esthetic result in a difficult clinical situation. Future implant designs with anatomically contoured implant shoulders may benefit treatments of this type by improving interproximal tissue support.<sup>5,62,63</sup>

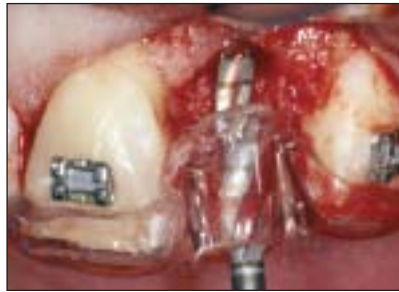## SURGICAL PROCEDURES

### Implant Selection

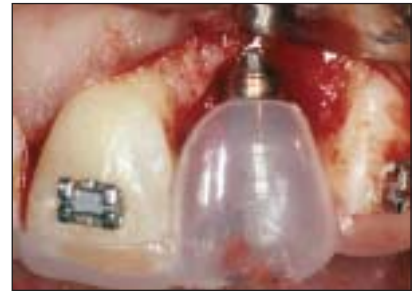
Based on the anatomic site analysis, the appropriate implant type is selected to best fit a single-tooth gap.



**Fig 12a** Correct implant positioning using a surgical template. The template imitates the future soft tissue margin at the implant crown.



**Fig 12b** The spiral drill is guided by the surgical template for proper alignment.



**Fig 12c** Status following implant placement. The implant shoulder is located about 2 mm apical to the future soft tissue margin.

In central incisors and canines, implants with a regular-neck configuration (shoulder diameter of 4.8 mm) are most often used. The minimal mesiodistal gap size for such a standard-neck implant is 7 mm, whereas 8 to 9 mm are ideal to allow a sufficient distance to adjacent roots (Table 3). The narrow-neck implant with a shoulder diameter of 3.5 mm is most often used in lateral incisor areas with a minimal gap size of 5.5 mm. The TE implants, mainly developed for placement in extraction socket defects, are offered with 2 different neck diameters: regular and wide. In the anterior maxilla, the 2 TE implant types with the regular-neck configuration (diameter of 4.8 mm) are used for standard prosthetic procedures. The wide-neck configuration (shoulder diameter of 6.5 mm) should only be used in exceptional clinical situations because of its potential for reaching too far facially and/or proximally.

### Surgical Templates

The use of surgical templates in the anterior maxilla can be valuable to properly place the implant shoulder in a position that will allow for an ideal emergence profile and long-term peri-implant hard and soft tissue support.<sup>3,4,7</sup> Templates are mandatory for implant treatment of extended edentulous spaces. Many variations of surgical templates exist. Good templates should have the following features: they should be easy to place and remove, they should be rigid and stable, they must allow for placement and removal of bite blocks when possible, and they must not interfere with tissue reflection and visualization of the depth indicators or the cooling of the surgical drills. A key feature of a surgical template used in the anterior maxilla is designation of the final apico-coronal, mesiodistal, and orofacial positioning of the implant shoulder. The best way to indicate these positions is to complete a diagnostic waxup highlighting the final gingival margin position, facial surface, and embrasure form of the proposed restoration. Working backward from this waxup

generates a template that will place the implant in a position that will support the planned restoration (Figs 12a to 12c) and make restoring it easier.

It is clear that templates can be helpful in making anterior esthetics more predictable and reliable. However, they are only as good as the team that uses them. Communication between the restorative clinician making the template and the surgeon using it is imperative, so that they can agree on a design that will make the placement process efficient and accurate.

### Surgical Procedures in Single-Tooth Gaps

Under local anesthesia, the mucosa is opened with a crestal incision located approximately 2 to 3 mm toward the palatal aspect and extended through the sulcus of adjacent teeth to the facial aspect of the alveolar crest. This incision avoids the formation of scar tissue in the midcrestal area and ensures sufficient vascularity of the facial flap in the area of the future papillae. Facial line-angle relieving incisions are most often necessary to allow sufficient access to the surgical site (Figs 13a and 13b). In patients who need a bone augmentation procedure, this flap design also allows for tension-free wound closure with the release of the periosteum and a coronal mobilization of the flap. As an alternative, a parapapillary incision technique may be used. Implant placement without flap elevation (often called “flapless implant placement”) is considered experimental, because no clinical studies with sufficient data have been published yet.

After the incisions have been made, the facial and palatal mucoperiosteal flaps are elevated with a fine tissue elevator to guarantee low-trauma soft tissue handling. This is followed by an intrasurgical site analysis to evaluate the facial aspect of the alveolar crest. For implant sites in the central incisor area, location of the nasopalatal foramen must be determined. A crest-flattening or bone-scalloping procedure is recommended, since this facilitates easier and more precise preparation of the implant bed

and the natural shape of the alveolar crest is imitated. However, the surgeon should not remove any bone in the proximal area of adjacent teeth, because this bone is important for the support and maintenance of the papillae.

The precise position of the implant site is marked with small round burs. Correct 3-dimensional implant placement can be determined by using either a periodontal probe and landmarks of adjacent teeth<sup>21</sup> or a prefabricated surgical template with a built-in gingival margin for the future implant crown.<sup>45</sup> Both techniques provide sufficient guidance in single-tooth gaps.

Preparation of the implant bed is carried out with standard spiral drills of increasing diameter (2.2 mm, 2.8 mm, and 3.5 mm). This technique reduces the trauma to the bone tissue and gives the surgeon a chance to change the position of the implant and/or the direction of the implant axis between drill steps. As previously outlined, the objective is to position the implant shoulder within the comfort zones in all 3 dimensions. To ensure correct esthetic implant placement, the entrance of the bone cavity has to be prepared with the profile drill to allow deeper implant placement. In addition, implants with a short neck configuration are most often used to limit the amount of bone resorption in the crestal area.

During bone preparation, different depth gauges help the surgeon to control the future implant position in the mesiodistal, orofacial, and apicocoronal directions, as well as the implant axis (Figs 13c and 13d). Pretapping of the thread is rarely done in the anterior maxilla. Most often, self-tapping implants are used, since the bone structure in the anterior maxilla is rather spongy. Implant placement is performed either with an adapter attached to a special contra-angle handpiece (at 15 rpm) or with the hand ratchet. Following implant placement, primary stability of the implant is carefully checked.

An appropriate healing cap is then selected. It is recommended that a healing cap be used that covers the implant shoulder, such as the 1.5-mm cover screw (Figs 13e and 13f) or an esthetic healing cap with a buccal bevel, which is available in 2 heights (2 mm and 3.5 mm). All these healing caps have the advantage that no bone can grow on top of the implant shoulder during healing, and the caps support the soft tissues in the proximal area. The buccal bevel of the esthetic healing cap will also allow for additional space for the interim restoration during the healing phase.

In the case of a peri-implant bone defect, either with an intact or a deficient facial bone wall, a local bone augmentation procedure is recommended.

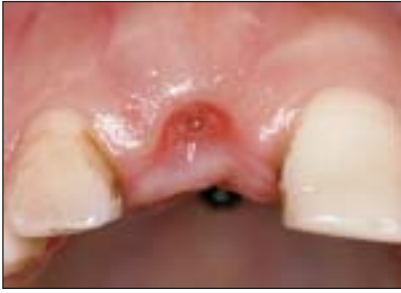Today, the GBR procedure, ie, applying barrier membranes in combination with bone grafts and/or bone substitutes, is routinely used (Figs 13g to 13j). The goal of GBR is to establish a thick facial bone wall of at least 2 to 3 mm to achieve sufficient and long-lasting bone support for the facial soft tissues. Improvement of soft tissue esthetics can also be achieved with soft tissue grafting at implant placement.<sup>21</sup> In patients with thin soft tissues and/or a concave contour of the facial mucosa, a connective tissue graft can be used to improve the thickness and contour of the soft tissues. These grafts are harvested in the premolar area of the palate and can be sutured to the periosteum of the mucoperiosteal flap to avoid displacement of the graft during wound closure.

Prior to completion of the surgical procedure, the mucoperiosteal flap is repositioned precisely, particularly in the area of the future papillae. The surgeon has to make sure that wound closure is precise and tension-free. To achieve this, an incision of the periosteum is often necessary to release the flap in a coronal direction (Fig 13k). For suturing, fine atraumatic suture material (5-0) is recommended. Following surgery, a periapical radiograph is taken to examine the position and direction of the placed implant and its relationship to the roots of adjacent teeth (Fig 13l).

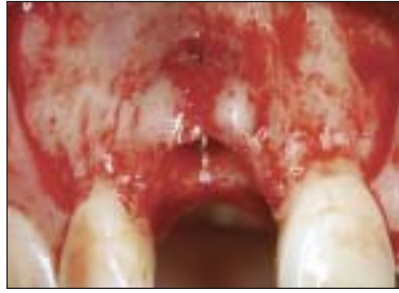### **Surgical Procedures in Extended Edentulous Spaces**

In implant sites with multiple missing teeth, the surgical procedure is clearly more demanding and requires optimal preoperative planning and an implant surgeon with sufficient experience. The use of an appropriate surgical template is mandatory to enable correct 3-dimensional implant positioning in the mesiodistal, orofacial, and apicocoronal directions. In sites with adjacent implants, an additional aspect needs to be considered: the interimplant distance. In such sites, bone resorption of 1 to 2 mm at the proximal aspects of the implant leads to a flattening of the interimplant bone and consequently a short interimplant papilla. A distance of at least 3 mm has been recommended between 2 adjacent implants to minimize this bone resorption.<sup>41</sup> This recommendation seems logical based on current knowledge, but no clinical and radiographic studies are yet available to support it.

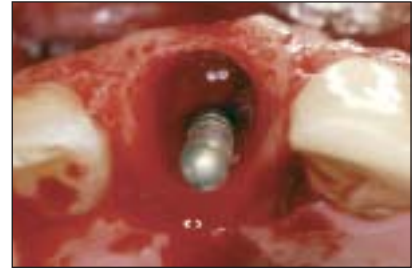The surgical procedures with regard to incision technique, flap design, bone preparation, and implant placement in extended edentulous spaces follow the same guidelines as previously outlined. Such sites most often also have horizontal and/or vertical bone deficiencies. Therefore, bone augmentation



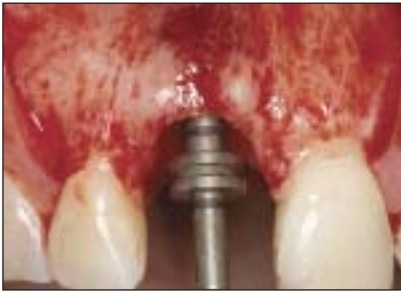**Fig 13a** Single-tooth gap in the central incisor area. Status 8 weeks following tooth extraction. A palatal incision will be used about 3 mm from the middle of the crest.



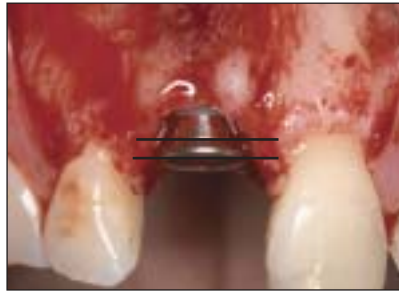
**Fig 13b** The surgical site is exposed with a full-thickness flap using 2 distal-line-angle relieving incisions.



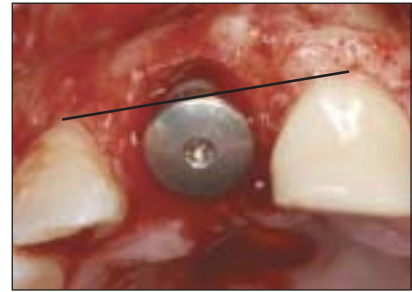
**Fig 13c** Following preparation with the first round burs and drills, the depth gauge is inserted to examine the future implant position and axis. Note the palatal position of the pin in relation to the extraction socket.



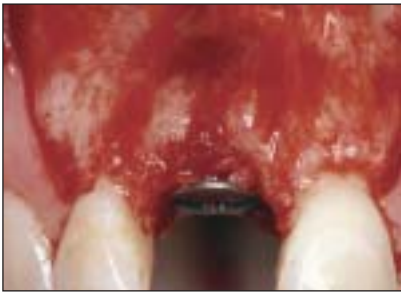**Fig 13d** The second depth gauge, with a built-in 5-mm ring, is used to check the proximity of the future implant shoulder to adjacent root surfaces.



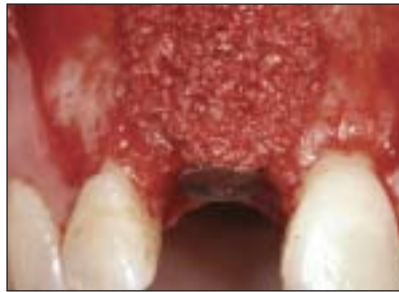**Fig 13e** Status following implant placement and insertion of 1.5-mm large healing cap to cover the implant shoulder. Note the correct apicocoronary position of the implant shoulder, about 1 mm apical to the CEJ of the adjacent contralateral tooth (*line*).



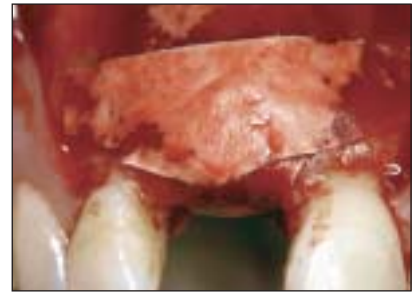**Fig 13f** The occlusal view confirms the correct orofacial position of the implant shoulder being slightly palatal to the point of emergence of the contralateral central incisor (*line*). Note the minor bone defect at the facial aspect, which requires bone grafting.



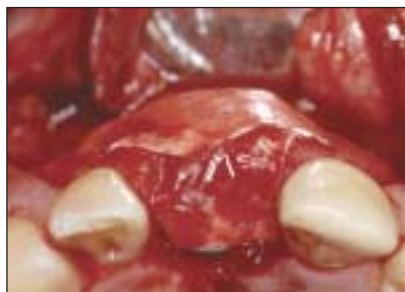**Fig 13g** The facial bone defect is filled with autogenous bone chips harvested in the vicinity, such as the anterior nasal spine.



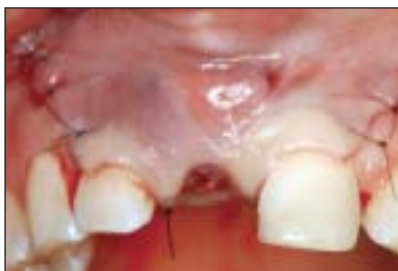**Fig 13h** A second layer of bone substitute is used to overaugment the surgical site. A bone filler with a low substitution rate (Bio-Oss) is preferred.



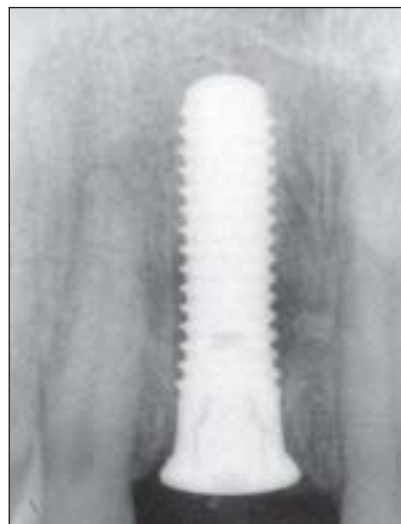**Fig 13i** The augmentation material is covered with a collagen-based barrier membrane using the principles of GBR. Two membrane strips are used ("double layer technique") to improve membrane stability.



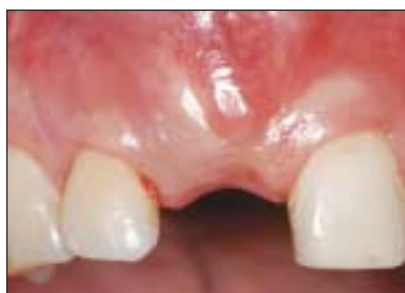**Fig 13j** (Left) The occlusal view clearly shows how the alveolar crest was locally overaugmented.



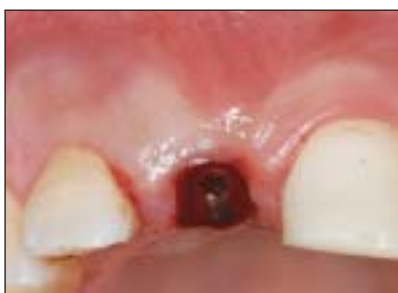**Fig 13k** (Center) Following incision of the periosteum, the flap is mobilized coronally, and a tension-free primary wound closure is obtained. To close the wound, 5-0 and 6-0 nonresorbable suture material is used.



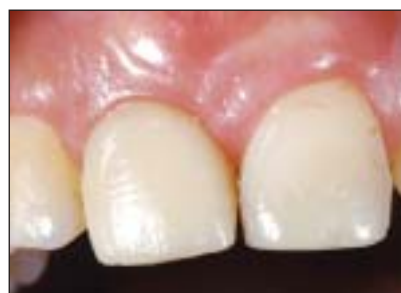**Fig 13l** (Right) Periapical postsurgical radiograph. Note the minor radiolucency in the middle of the implant.



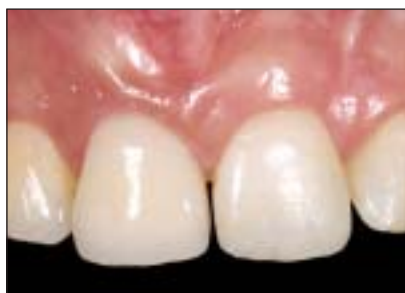**Fig 13m** Soft tissue status at 8 weeks of healing. The site is ready for reopening to gain access to the implant shoulder and initiate the restorative phase.



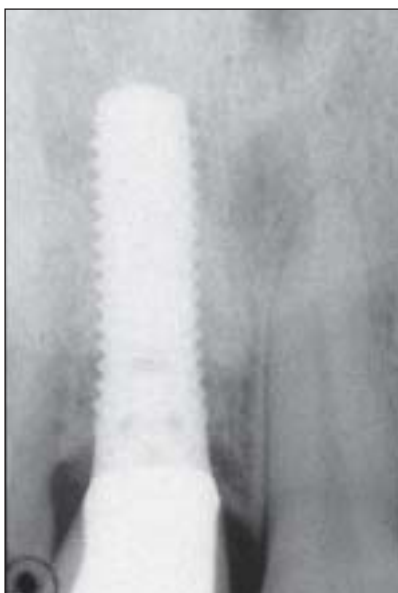
**Fig 13n** The reopening was done with a 12b blade, removing some keratinized mucosa slightly palatal to the healing cap. A larger healing cap was inserted to compress the soft tissues slightly to the facial aspect.



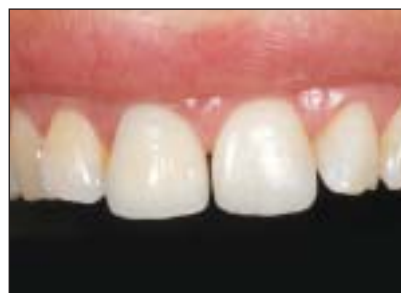**Fig 13o** Status a few weeks following placement of the provisional crown based on a titanium coping. The shape of the provisional restoration was used for soft tissue conditioning.



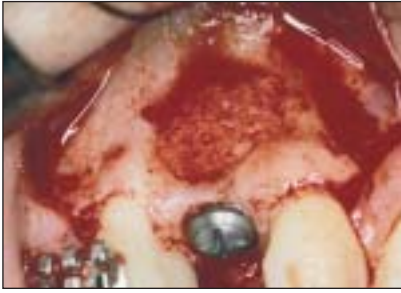**Fig 13p** (Above) Status 12 months following implant placement. The definitive ceramometallic crown has been seated. The esthetic result is pleasing with a harmonious gingival margin and intact papillae.



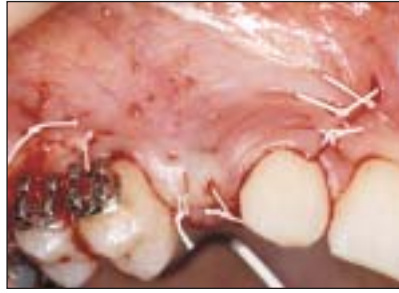**Fig 13q** (Right) The periapical radiograph at 12 months with the definitive crown indicates minimal bone resorption.



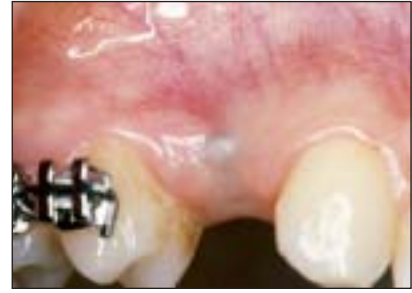**Fig 13r** Final treatment outcome of this 27-year-old female patient with a high lip line.



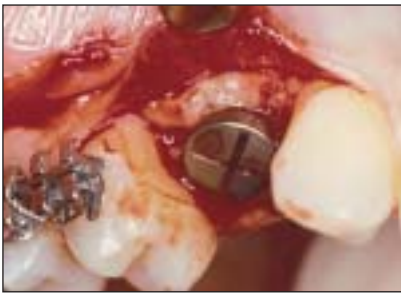**Fig 14a** Intraoperative status following placement of a standard screw implant in area 13 in a correct 3-dimensional position and an intact facial bone wall in the crestal area. An apical fenestration defect was augmented with locally harvested autogenous bone grafts.



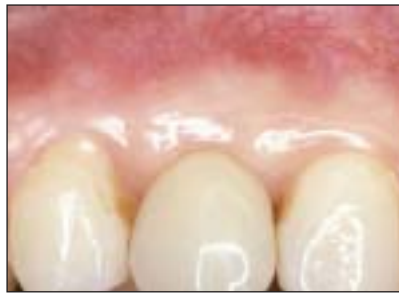**Fig 14b** Submerged implant healing for 3 months was chosen for this patient in 1992.



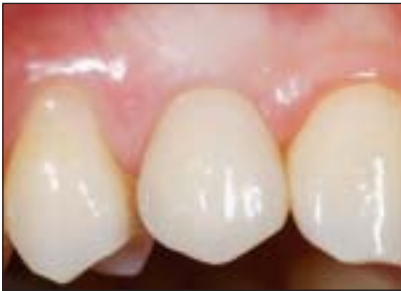**Fig 14c** Three months following implant placement, a thin facial mucosa was apparent, requiring soft tissue graft at the reopening procedure.



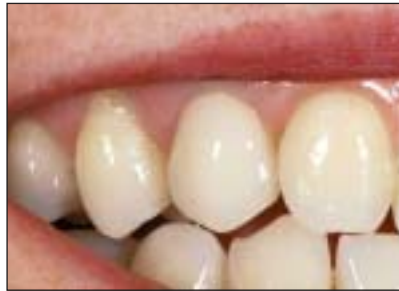**Fig 14d** At reopening, a free connective tissue graft was applied to improve the thickness of the facial soft tissues.



**Fig 14e** Clinical status during the phase of provisional restoration demonstrates the convex facial soft tissue margin at the right level.

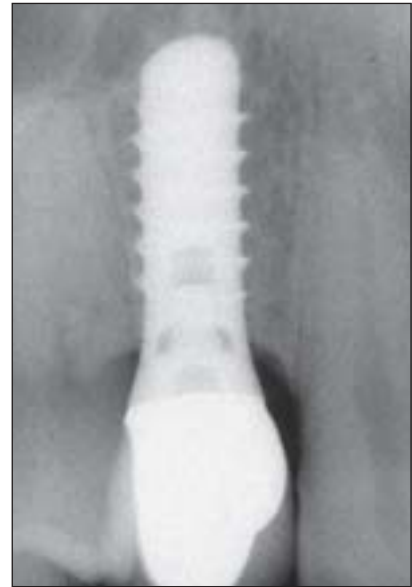


**Fig 14f** (Left) Clinical status at 12 years following implant placement (2004) demonstrates remarkable soft tissue stability at the mid-facial margin and nice convex contour of the facial mucosa.



**Fig 14g** (Center) Esthetic result with the lip line.

**Fig 14h** (Right) The periapical radiograph 12 years following implant placement confirms stable bone crest values around the standard screw implant.



procedures are common in sites with multiple missing teeth, using either a simultaneous or a staged approach.

### Interim Restoration

Delivery of an appropriate interim restoration at the time of implant placement in the anterior maxilla is paramount for patient satisfaction and peri-implant tissue protection. Fabrication of an interim

restoration that will not place intermittent pressure on the healing cap and tissues is recommended. For this reason, removable partial dentures should be adjusted to prevent these contacts, which can cause difficulty in patients with limited interocclusal space or excessive vertical overlap. Interim restorations that are fixed to the adjacent teeth or that completely eliminate the possibility for soft tissue contacts are more beneficial for implant integration and



soft tissue maintenance. Orthodontic brackets and archwires on several teeth adjacent to the implant site, with an attached pontic, offer a low-maintenance option for patients undergoing long-term therapy, eg, hard/soft tissue grafting prior to implant placement. Patients without excessive vertical overlap can benefit from interim resin-retained fixed partial dentures that are retained with spot etching and bonding with an appropriate composite material on the adjacent teeth. In limited interocclusal space or excessive vertical overlap situations, an Essix retainer with an acrylic resin restoration can be used in the edentulous space.<sup>64</sup> These restorations offer good esthetic results for short periods; however, patient compliance is important in preventing rapid occlusal wear through the template material.

### Postsurgical Treatment and Re-entry Procedure

During the soft tissue healing period of 2 to 3 weeks, chemical plaque control with chlorhexidine digluconate (0.12%) is recommended. Mechanical toothbrushing is abandoned at the surgical sites for at least 2 weeks. Follow-up visits are recommended after 7, 14, and 21 days, with clinical examination and wound cleaning. The sutures are removed after 7 to 10 days.

Bone healing for implants with an SLA surface (sandblasted, large-grit, acid-etched; Straumann) is sufficiently progressed after 6 weeks in standard sites without peri-implant bone defects.<sup>65,66</sup> In sites with peri-implant bone defects requiring a simultaneous bone augmentation procedure, the healing period has to be extended for as many as 12 weeks depending on the extent and morphology of the bone defect present at implant placement.

At completion of the bone healing period (Figs 13m and 13n), a reopening procedure is performed with a blade or a tissue punch to expose the implant and initiate the soft tissue conditioning. A tissue punch should be used only in sites with an abundance of keratinized mucosa, because it is a process that removes valuable tissue. In most cases, the reopening is performed with a 13b blade from a slightly palatal aspect to allow for tissue pressure in a facial and proximal direction. After removal of the originally placed healing cap, a longer healing cap or provisional restoration is placed to initiate the soft tissue support (Fig 13n). With the synOcta design (Straumann), an impression can be made on the day of reopening to fabricate the provisional restoration and 3 to 6 months later for the definitive restoration (Figs 13o to 13r). Another case report with long-term follow-up is shown in Figs 14a to 14h.

## REFERENCES

1. Belser UC. Esthetics checklist for the fixed prosthesis. Part 2: Biscuit bake try-in. In: Schärer P, Rinn LA, Kopp FR (eds). *Esthetic Guidelines for Restorative Dentistry*. Chicago: Quintessence, 1982:188–192.
2. Magne P, Belser UC (eds). *Bonded Porcelain Restorations in the Anterior Dentition: A Biomimetic Approach*. Chicago: Quintessence, 2002.
3. Belser UC, Bernard JP, Buser D. Implant-supported restorations in the anterior region: Prosthetic considerations. *Pract Periodontics Aesthet Dent* 1996;8:875–883.
4. Belser UC, Buser D, Hess D, Schmid B, Bernard JP, Lang NP. Aesthetic implant restorations in partially edentulous patients—A critical appraisal. *Periodontol 2000* 1998;17:132–150.
5. Belser UC, Bernard JP, Buser D. Implant placement in the esthetic zone. In: Lindhe J, Karring T, Lang NP (eds). *Clinical Periodontology and Implant Dentistry*, ed 4. London: Blackwell Munksgaard, 2003:915–944.
6. Buser D, Dahlin C, Schenk RK (eds). *Guided Bone Regeneration in Implant Dentistry*. Chicago: Quintessence, 1994.
7. Garber DA, Belser UC. Restorative-driven implant placement with restoration-generated site development. *Compend Contin Educ Dent* 1995;16:796,798–802.
8. Gargiulo AW, Wentz FM, Orban B. Dimensions and relations of the dentogingival junction in humans. *J Periodontol* 1961;32:261–267.
9. Buser D, Weber HP, Donath K, Fiorellini JP, Paquette DW, Williams RC. Soft tissue reactions to non-submerged unloaded titanium implant in beagle dogs. *J Periodontol* 1992;63:225–235.
10. Berglundh T, Lindhe J. Dimension of the periimplant mucosa. Biological width revisited. *J Clin Periodontol* 1996;23:971–973.
11. Cochran DL, Hermann JS, Schenk RK, Higginbottom FL, Buser D. Biologic width around titanium implants. A histometric analysis of the implanto-gingival junction around unloaded and loaded nonsubmerged implants in the canine mandible. *J Periodontol* 1997;68:186–198.
12. Hermann JS, Buser D, Schenk RK, Higginbottom FL, Cochran DL. Biologic width around titanium implants. A physiologically formed and stable dimension over time. *Clin Oral Implants Res* 2000;11:1–11.
13. Todescan FF, Pustiglioni FE, Imbronito AV, Albrektsson T, Gioso M. Influence of the microgap in the peri-implant hard and soft tissues: A histomorphometric study in dogs. *Int J Oral Maxillofac Implants* 2002;17:467–472.
14. Hermann JS, Buser D, Schenk RK, Cochran DL. Crestal bone changes around titanium implants. A histometric evaluation of unloaded nonsubmerged and submerged implants in the canine mandible. *J Periodontol* 2000;71:1412–1424.
15. Kan JY, Rungcharassaeng K, Umezaki K, Kois JC. Dimensions of peri-implant mucosa: An evaluation of maxillary anterior single implants in humans. *J Periodontol* 2003;4:557–562.
16. Kois JC. Predictable single tooth peri-implant esthetics: Five diagnostic keys. *Compend Contin Educ Dent* 2001;22:199–206.
17. Tarnow DP, Magner AW, Fletcher P. The effect of the distance from the contact point to the crest of bone on the presence or absence of the interproximal dental papilla. *J Periodontol* 1992;63:995–996.

18. Choquet V, Hermans M, Adriaenssens P, Daelemans P, Tarnow DP, Malevez C. Clinical and radiographic evaluation of the papilla level adjacent to single-tooth dental implants. A retrospective study in the maxillary anterior region. *J Periodontol* 2001;2:1364–1371.
19. Salama H, Salama M. The role of orthodontic extrusive remodeling in the enhancement of soft and hard tissue profile prior to implant placement: A systemic approach to the management of extraction site defects. *Int J Periodontics Restorative Dent* 1993;13:312–334.
20. Goldberg PV, Higginbottom FL, Wilson TG. Periodontal considerations in restorative and implant therapy. *Periodontol* 2000 2001;25:100–109.
21. Buser D, von Arx T. Surgical procedures in partially edentulous patients with ITI implants. *Clin Oral Implants Res* 2000;11(suppl 1):83–100.
22. Raghoobar GM, Batenburg RH, Vissink A, Reintsema H. Augmentation of localized defects of the anterior maxillary ridge with autogenous bone before insertion of implants. *J Oral Maxillofac Surg* 1996;54:1180–1185.
23. Widmark G, Andersson B, Ivanoff CJ. Mandibular bone graft in the anterior maxilla for single-tooth implants. Presentation of surgical method. *Int J Oral Maxillofac Surg* 1997;26:106–109.
24. Cordaro L, Amade DS, Cordaro M. Clinical results of alveolar ridge augmentation with mandibular block bone grafts in partially edentulous patients prior to implant placement. *Clin Oral Implants Res* 2002;13:103–111.
25. Nyman S, Lang NP, Buser D, Bragger U. Bone regeneration adjacent to titanium dental implants using guided tissue regeneration: A report of two cases. *Int J Oral Maxillofac Implants* 1990;5:9–14.
26. Buser D, Bragger U, Lang NP, Nyman S. Regeneration and enlargement of jaw bone using guided tissue regeneration. *Clin Oral Implants Res* 1990;1:22–32.
27. Hermann JS, Buser D. Guided bone regeneration for dental implants. *Curr Opin Periodontol* 1996;3:168–177.
28. Wang HL, Carroll MJ. Guided bone regeneration using bone grafts and collagen membranes. *Quintessence Int* 2001;32:504–515.
29. Hämmerle CH, Jung RE. Bone augmentation by means of barrier membranes. *Periodontol* 2000 2003;33:36–53.
30. Buser D, Dula K, Hirt HP, Schenk RK. Lateral ridge augmentation using autografts and barrier membranes. A clinical study in 40 partially edentulous patients. *J Oral Maxillofac Surg* 1996;54:420–432.
31. Simion M, Baldoni M, Zaffe D. Jawbone enlargement using immediate implant placement associated with a split-crest technique and guided tissue regeneration. *Int J Periodontics Restorative Dent* 1992;12:462–473.
32. Chin M. Distraction osteogenesis for dental implants. *Atlas Oral Maxillofac Surg Clin North Am* 1999;7:41–63.
33. Chiapasco M, Romeo E, Vogel G. Vertical distraction osteogenesis of edentulous ridges for improvement of oral implant positioning: A clinical report of preliminary results. *Int J Oral Maxillofac Implants* 2001;16:43–51.
34. Rachmiel A, Srouji S, Peled M. Alveolar ridge augmentation by distraction osteogenesis. *Int J Oral Maxillofac Surg* 2001;30:510–517.
35. Simion M, Trisi P, Piattelli A. Vertical ridge augmentation using a membrane technique associated with osseointegrated implants. *Int J Periodontics Restorative Dent* 1994;14:496–511.
36. Simion M, Jovanovic SA, Tinti C, Benfenati SP. Long-term evaluation of osseointegrated implants inserted at the time or after vertical ridge augmentation. A retrospective study on 123 implants with 1-5 year follow-up. *Clin Oral Implants Res* 2001;12:35–45.
37. Parel SM, Sullivan DY (eds.). *Esthetics and Osseointegration*. Dallas: Osseointegration Seminars, 1989.
38. Tarnow DP, Eskow RN. Considerations for single-unit esthetic implant restorations. *Compend Contin Educ Dent* 1995;16:782–784.
39. Esposito M, Ekkestube A, Gröndahl K. Radiological evaluation of marginal bone loss at tooth surfaces facing single Brånemark implants. *Clin Oral Implants Res* 1993;4:151–157.
40. Thilander B, Odman J, Jemt T. Single implants in the upper incisor region and their relationship to the adjacent teeth. An 8-year follow-up study. *Clin Oral Implants Res* 1999;10:346–355.
41. Tarnow DP, Cho SC, Wallace SS. The effect of inter-implant distance on the height of inter-implant bone crest. *J Periodontol* 2000;71:546–549.
42. Hermann JS, Cochran DL, Nummikoski PV, Buser D. Crestal bone changes around titanium implants. A radiographic evaluation of unloaded nonsubmerged and submerged implants in the canine mandible. *J Periodontol* 1997;68:1117–1130.
43. King GN, Hermann JS, Schoolfield JD, Buser D, Cochran DL. Influence of the size of the microgap on crestal bone levels in non-submerged dental implants: A radiographic study in the canine mandible. *J Periodontol* 2002;73:1111–1117.
44. Piattelli A, Vrespa G, Petrone G, Iezzi G, Annibaldi S, Scarano A. Role of the microgap between implant and abutment: A retrospective histologic evaluation in monkeys. *J Periodontol* 2003;74:346–352.
45. Higginbottom FL, Wilson TG Jr. Three-dimensional templates for placement of root-form dental implants: A technical note. *Int J Oral Maxillofac Implants* 1996;11:787–793.
46. Magne P, Gallucci GO, Belser UC. Anatomic crown width/length ratios of unworn and worn maxillary teeth in white subjects. *J Prosthet Dent* 2003;89:453–461.
47. Ellegaard B, Baelum V, Karring T. Implant therapy in periodontally compromised patients. *Clin Oral Implants Res* 1997;8:180–188.
48. Karrousis IK, Salvi GE, Heitz-Mayfield LJ, Bragger U, Hämmerle CH, Lang NP. Long-term implant prognosis in patients with and without a history of chronic periodontitis: A 10-year prospective cohort study of the ITI Dental Implant System. *Clin Oral Implants Res* 2003;14:329–339.
49. Kornman KS, Crane A, Wang HY, et al. The interleukin-1 genotype as a severity factor in adult periodontal disease. *J Clin Periodontol* 1997;24:72–77.
50. Nieri M, Muzzi L, Cattabriga M, Rotundo R, Cairo F, Pini Prato GP. The prognostic value of several periodontal factors measured as radiographic bone level variation: A 10-year retrospective multilevel analysis of treated and maintained periodontal patients. *J Periodontol* 2002;73:1485–1493.
51. Tai H, Endo M, Shimada Y, et al. Association of interleukin-1 receptor antagonist gene polymorphisms with early onset periodontitis in Japanese. *J Clin Periodontol* 2002;29:882–888.
52. McDevitt MJ, Wang HY, Knobelman C, et al. Interleukin-1 genetic association with periodontitis in clinical practice. *J Periodontol* 2000;71:156–163.

53. Meisel P, Siegemund A, Grimm R, et al. The interleukin-1 polymorphism, smoking, and the risk of periodontal disease in the population-based SHIP study. *J Dent Res* 2003;82:189–193.
54. Bain CA, Moy PK. The association between the failure of dental implants and cigarette smoking. *Int J Oral Maxillofac Implants* 1993;8:609–615.
55. De Bruyn H, Collaert B. The effect of smoking on early implant failure. *Clin Oral Implants Res* 1994;5:260–264.
56. Lambert PM, Morris HF, Ochi S. The influence of smoking on 3-year clinical success of osseointegrated dental implants. *Ann Periodontol* 2000;5:79–89.
57. Wallace RH. The relationship between cigarette smoking and dental implant failure. *Eur J Prosthodont Restorative Dent* 2000;8:103–106.
58. Feloutzis A, Lang NP, Tonetti MS, et al. IL-1 gene polymorphism and smoking as risk factors for peri-implant bone loss in a well-maintained population. *Clin Oral Implants Res* 2003;14:10–17.
59. Shimpuku H, Nosaka Y, Kawamura T, Tachi Y, Shinohara M, Ohura K. Genetic polymorphisms of the interleukin-1 gene and early marginal bone loss around endosseous dental implants. *Clin Oral Implants Res* 2003;14:423–429.
60. Gruica B, Wang HY, Lang NP, Buser D. Impact of IL-1 genotype and smoking status on the prognosis of osseointegrated implants. *Clin Oral Implants Res* 2004;15(4):393–400.
61. Reddy MS, Mayfield-Donahoo T, Vanderven FJ, Jeffcoat MK. A comparison of the diagnostic advantages of panoramic radiography and computed tomography scanning for placement of root form dental implants. *Clin Oral Implants Res* 1994;5:229–238.
62. Holt RL, Rosenberg MM, Zinser PJ, Ganeles J. A concept for a biologically derived, parabolic implant design. *Int J Periodontics Restorative Dent* 2002;22:473–481.
63. Wohrle PS. Nobel Perfect esthetic scalloped implant: Rationale for a new design. *Clin Implant Dent Relat Res* 2003;5(suppl 1):64–73.
64. Moskowitz EM, Sheridan JJ, Celenza F Jr, Tovilo K, Munoz AM. Essix appliances. Provisional anterior prosthesis for pre- and post-implant patients. *NY State Dent J* 1997;63:32–35.
65. Cochran DL, Buser D, ten Bruggenkate CM, et al. The use of reduced healing times on ITI implants with a sandblasted and acid-etched (SLA) surface: Early results from clinical trials on ITI SLA implants. *Clin Oral Implants Res* 2002;13:144–153.
66. Bornstein MM, Lussi A, Schmid B, Belser UC, Buser D. Early loading of titanium implants with a sandblasted and acid-etched (SLA) surface: 3-year results of a prospective study in partially edentulous patients. *Int J Oral Maxillofac Implants* 2003;18:659–666.