

# Immediate Placement and Implant Loading for Expedited Patient Care: A Patient Report

Thomas J. Balshi, DDS<sup>1</sup>/Glenn J. Wolfinger, DMD<sup>1</sup>

*This patient report concerns etiologic factors leading to a failed natural dentition, masticatory function, and poor dental esthetics in a 30-year-old woman. The surgical and restorative treatment provided for the patient was designed to address her dental phobia, location of residence, and debilitated oral condition. While the following case report details an example of the clinical success that can be achieved through advances in dental implant treatment, the most satisfying event was not necessarily the procedure itself, but the profound change that the generosity of the osseointegration community has made on the life of a needy individual. Through the active leadership of the Osseointegration Foundation Charitable Grant Program, the patient, whose complex treatment is described here, was able to take advantage of treatment that otherwise would not have been available to her. This complex treatment was enabled by the Osseointegration Foundation and other caring donors. (INT J ORAL MAXILLOFAC IMPLANTS 2002;17:587-592)*

**Key words:** conversion prosthesis, dental implants, dental phobia, edentulism, immediate loading, osseointegration

Complete edentulism is usually a slowly developing condition that occurs as a result of dental neglect, although there are some instances when trauma or systemic disease may contribute to the creation of the same condition. Regardless of the etiology, the dentally debilitated patient generally experiences deficiencies in the physiologic functions of speech, deglutition, and mastication.

A major reason for patient procrastination in seeing a dentist can be because of a psychologic impairment related to dental care. Fear of dental treatment can stem from previous negative dental experiences, an innate or socially engendered fear of professional care, or even personal embarrassment for allowing the condition to proceed to its current state. Economic considerations may also play a role in inhibit-

ing patients from proceeding with and enjoying the benefits of dental care. Lastly, physical access or proximity to the appropriate level of professional care prevents some from taking advantage of innovative multidisciplinary approaches to modern dentistry.

Oral debilitation, even when a substantial number of natural teeth remain, is difficult to manage. Periodontally hopeless teeth cannot serve as functional abutments for either fixed or removable prostheses. As natural teeth are lost and the patient becomes edentulous, conventional complete dentures are a common treatment option. Despite strict adherence to accepted denture fabrication techniques, complete denture wearers generally continue to experience deterioration of the supporting alveolar bone.<sup>1</sup>

An alternative to the complete removable denture is the use of endosseous implants as support for a fixed prosthesis. The use of dental implants has become an increasingly popular and predictable method of providing prosthesis support, retention, and stability. Brånemark and colleagues proposed the concept of osseointegration over 37 years ago, but total acceptance of implant-based therapy has been hampered by the cost of treatment and limited

<sup>1</sup>Prosthodontics Intermedica, Institute for Facial Esthetics, Fort Washington, Pennsylvania.

**Reprint requests:** Dr Thomas J. Balshi, Prosthodontics Intermedica, Institute for Facial Esthetics, 467 Pennsylvania Ave. #201, Fort Washington, PA 19034. Fax: +215-643-1149. E-mail: PITEAM@aol.com

access to professional care. Their initial clinical report focused on completely edentulous patients in 1969.<sup>2</sup> Since the early studies, dental implants have been used to treat partial edentulism,<sup>3</sup> replace single teeth,<sup>4</sup> and facilitate overdenture applications.<sup>5</sup>

As experience has accumulated with osseointegrated implants and long-term success rates have climbed, implant designs, surface characteristics, and loading protocols have evolved in an effort to reduce treatment time and cost.<sup>6-10</sup> The following history and treatment is typical of that provided for patients using the immediate functional loading concept in the edentulous mandible.

## HISTORY

Pretreatment patient communication determined that this 30-year-old female patient was in excellent systemic health, with previous hospitalizations only for the birth of 4 children. Cigarette smoking of half a pack per day and the social use of alcohol were reported. The patient's oral debilitation resulted from an intense fear of dentistry brought on by a frightening and demoralizing dental experience 12 years earlier. Financial resources and local access to comprehensive dental care were limited.

Approximately 12 years prior to presentation, the patient experienced traumatic avulsion of the maxillary anterior teeth, and several other teeth were luxated in this accident. Dental rehabilitation following the loss of teeth was ineffective because of the patient's inability to successfully use the removable partial denture that was fabricated at that time.

Prior to evaluation of the patient, a series of written and verbal communications took place between the patient and the prosthodontic caregivers. These communications revealed a state of advanced periodontal disease, loose and malpositioned teeth, extremely painful function, and associated pathology. One of the most challenging aspects of treatment was to overcome the patient's psychological fear so as to begin clinical procedures.

## CLINICAL EVALUATION AND DIAGNOSIS

The patient arrived in the late afternoon for clinical evaluation and review of medical history. She appeared to be in physical and emotional distress and described severe pain from her dentition, which was exacerbated by occlusal contact (Fig 1a). The examination revealed missing teeth in the maxilla and mandible, advanced loss of supporting bone, and generalized tooth mobility (Fig 1b). A panoramic

radiograph (Fig 1c) was obtained immediately upon arrival, but intraoral periapical radiographs were extremely difficult to acquire because of the patient's painful condition and reluctance to have instruments contact her loose and infected dentition.

The patient suffered from severe dental phobia. Dental diagnoses included periapical pathosis, tooth mobility, advanced periodontitis, partial edentulism, posterior occlusal collapse, caries lesions, and malodor. A tentative treatment plan was developed and reviewed in detail with the patient. It involved the removal of all remaining teeth under general anesthesia, the immediate placement of 5 endosseous implants in the anterior mandible, 1 in the left posterior mandible, and 2 in the right posterior mandible, followed by the fabrication of an acrylic resin conversion prosthesis for immediate placement and a conventional maxillary complete denture.

Comprehensive informed consents for extraction of the remaining teeth and implant placement, as well as administration of general anesthesia, were reviewed and discussed with the patient. All evaluation, diagnostic, and treatment planning decisions were completed during the day of initial presentation to the treatment office.

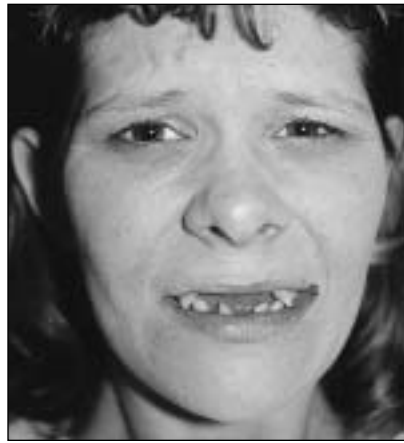## CLINICAL TREATMENT

Overnight, on-premises dental laboratory technicians fabricated the custom-designed acrylic resin immediate dentures for both the maxilla and mandible from the initial impressions and jaw records obtained at the initial appointment.

General anesthesia was administered using nasal intubation. Local anesthesia was accomplished with a combination of bupivacaine hydrochloride (Marcaine 0.5%; Cook Waite/Abbott Laboratories, Chicago, IL) and lidocaine hydrochloride (Lignospin Forte; Septodont, New Castle, DE), which also provided additional hemostasis at the surgical site. All remaining teeth were removed; granulation tissue was thoroughly debrided from the alveolus.

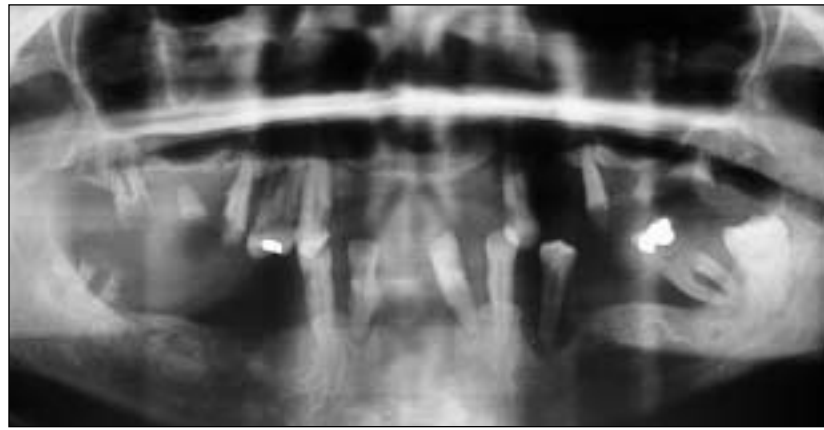
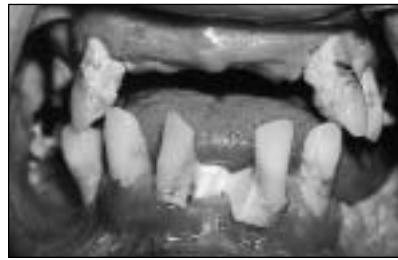In the maxillary arch, minor alveoloplasty was performed to remove sharp bony projections and provide an acceptable ridge configuration for placement of the immediate maxillary removable denture. Mucosal tissues were then sutured (Vicryl; Ethicon/Johnson & Johnson, Somerville, NJ) to achieve primary closure.

In the mandibular arch, a more aggressive alveoloplasty was performed to reduce the height of the anterior mandible to the level of the incisor apices. This radical alveoloplasty assured total clinical debridement of tooth socket soft tissue from the

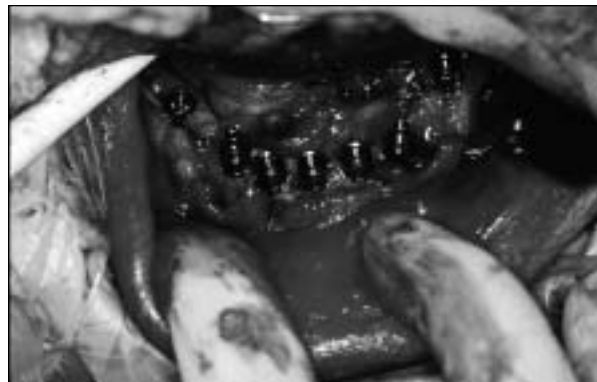

**Fig 1a** (Left) Pretreatment distress of the patient in dental pain.

**Fig 1b** (Below) Pretreatment clinical view showing advanced periodontitis, missing teeth, and angular cheilitis from lost vertical dimension.



**Fig 1c** Pretreatment panoramic radiograph.

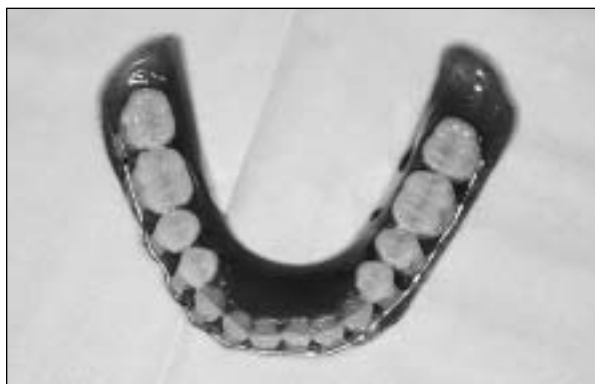

**Fig 2** Alveolar debridement and implant and abutment surgery for stage 1 of treatment.

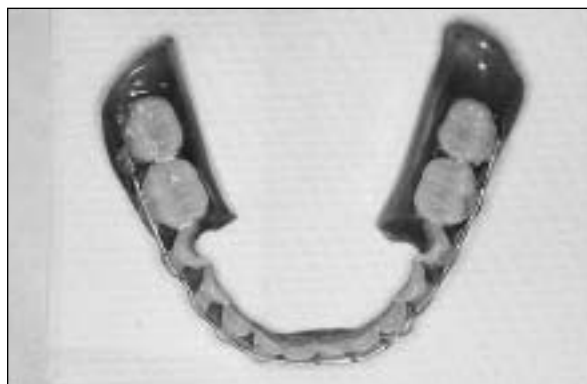bone. Eight Brånemark System implants (Nobel Biocare USA, Yorba Linda, CA) were placed: five  $3.75 \times 18$ -mm implants in the anterior mandible and three  $4 \times 10$ -mm implants in the posterior mandible (2 in the right and 1 in the left). The bone quality at the time of implant placement was determined clinically by the surgeon<sup>11</sup> to be quality 2 according to the classification established by Lekholm and Zarb.<sup>12</sup> A tap was used to prepare threads in the osteotomy sites prior to implant placement. Immediately following implant placement, a combination of Brånemark System abutments (Nobel Biocare USA) were securely fastened: two 3-mm Esthetic-Cone abutments were used in the positions of the mandibular left canine and right first molar, while 3-mm and 4-mm standard abutments were used for the remaining implants (Fig 2).

Immediately following abutment placement, Vicryl sutures were used to obtain primary closure with secure adaptation of the mucosa around the titanium abutments. Modified stainless steel impression copings (Nobel Biocare USA) were then

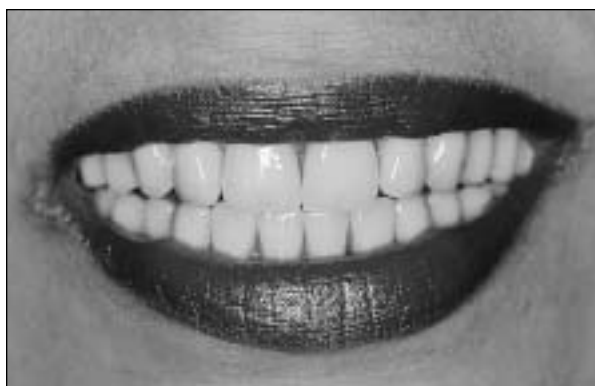placed on the abutments with 10-mm guide pins. The wire-reinforced complete mandibular immediate denture was relieved lingually (Figs 3a and 3b) to permit its placement, and so that maxillo-mandibular jaw relation records could be obtained without contacting the prosthetic cylinders or



**Fig 3a** Mandibular immediate denture with labial wire reinforcement.



**Fig 3b** The mandibular immediate denture is relieved for a "pickup" impression of prosthetic components.



**Fig 4** Facial view of provisional restorations immediately following surgery.

screws. Rubber dam (Hygenic; Coltene/Whaledent, Mahwah, NJ) was then placed over the surgically closed mucosal tissue to protect it from the autopolymerizing acrylic resin (Jet Acrylic; Lang Dental, Wheeling, IL) used to connect the prosthetic cylinders to the complete mandibular denture using the conversion prosthesis protocol.<sup>13,14</sup> Once polymerization of the resin was complete, the guide pins were removed from the prosthesis. The prosthesis was then taken from the operating room to the laboratory to be structurally enhanced, refined, and polished.

While the laboratory modifications were performed, a master impression was made at the level of the abutments using fast-setting impression plaster (Kerr, Romulus, MI). A master cast with metal analogs of the abutments was fabricated and prepared for articulation. At the same time, a stone cast of the maxillary prosthesis was also prepared for articulation.

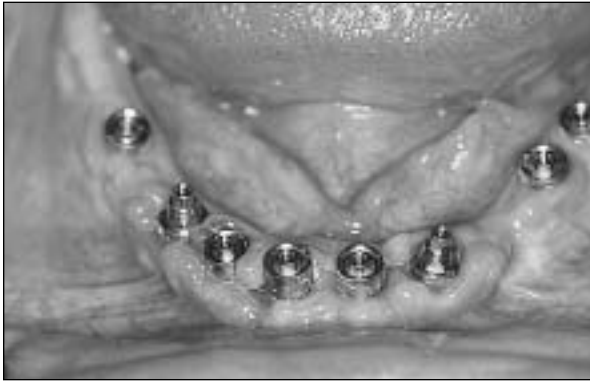Once the acrylic resin temporary implant-supported prosthesis was refined and disinfected, it was

returned to the operatory and fastened on the mandibular implants with gold screws for occlusal adjustment. An interocclusal registration was made and the prosthesis was once again removed from the patient's mouth, attached to the master cast, and articulated to the maxillary denture cast. Following articulation, the temporary prosthesis was seated in the patient and the screw access holes sealed with a cotton pellet and Fermit (Ivoclar, Amherst, NY). Extubation of the nasal tracheal tube occurred with the cessation of general anesthesia approximately 4 hours after the initiation of treatment.

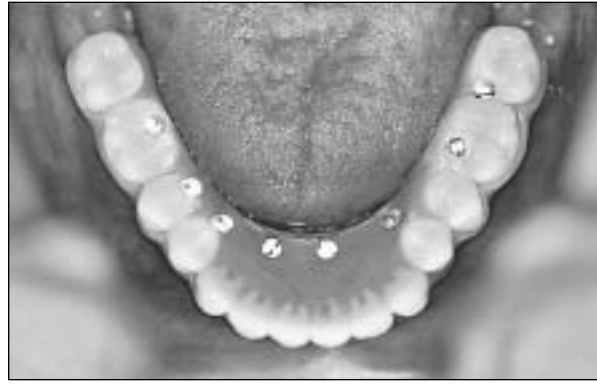The patient was monitored in recovery for an hour after the procedure, at which time she was permitted to walk about the clinical facility (Fig 4). Appropriate medications were prescribed for follow-up, including the use of posttreatment antibiotics (penicillin 500 mg, 1 tablet 4 times a day for 10 days) and analgesics as needed. The patient returned home the next morning, and daily follow-up communication was carried on for 2 weeks. Four months following extractions and implant placement, the patient returned for a 1-hour visit to change the prostheses. At that visit, a definitive gold and acrylic resin custom-designed fixed mandibular tissue-integrated prosthesis and a new maxillary denture were placed (Figs 5a to 5d). Oral hygiene instructions and sufficient quantities of oral hygiene supplies were provided to the patient.

## DISCUSSION

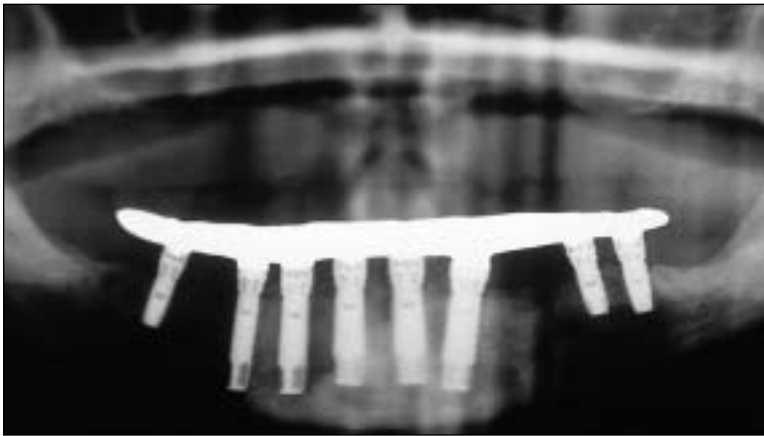
Total failure of the natural dentition leading to a condition of an oral invalid can emanate from multiple dental pathologies, leading to a collapse of vertical occlusal dimension and an accelerated aged appearance of the lower third of the face. One of



**Fig 5a** Healed mucosa around abutments 4 months after stage 1 surgery.



**Fig 5b** Second visit 4 months after stage 1 surgery; delivery of definitive prostheses.



**Fig 5c** Posttreatment radiograph.



**Fig 5d** Patient response to treatment.

COPYRIGHT © 2002 BY QUINTESSENCE PUBLISHING CO. INC. PRINTING OF THIS DOCUMENT IS RESTRICTED TO PERSONAL USE ONLY. NO PART OF THIS ARTICLE MAY BE REPRODUCED OR TRANSMITTED IN ANY FORM WITHOUT WRITTEN PERMISSION FROM THE PUBLISHER.

the major reasons patients neglect having dental treatment to the point of becoming edentulous is the fear of dentistry, fear of the dentist, and fear in general of the entire dental experience. The patient must be made to feel comfortable with the dental office from the first moment of contact with reception personnel, the dental assistants and technicians, and the dentist, creating a positive dental experience on which trust is built. Another reason that patients may neglect or not complete treatment is the lack of access to treatment without traveling long distances for multiple dental appointments.

This article describes the expedited clinical and laboratory procedures involved in the treatment of a patient affected by such circumstances. Even for patients who express no anxiety about dental treatment, the described protocol offers an effective

treatment option to impending tooth loss or a long-standing struggle with ill-fitting, uncomfortable, or unsightly removable prostheses. It relies heavily on coordinated surgical and restorative treatment provided by an experienced prosthodontic team. When organized in a sequence that mandates multiple clinical and laboratory procedures in a timely and coordinated manner, total treatment time can be significantly reduced.

Providing appropriate occlusion and a firmly supported vertical dimension of occlusion, reconstructions using the Teeth in a Day protocol (Prosthodontics Intermedica, Fort Washington, PA) (as was used for this patient) can also provide the patient with an improved cosmetic appearance. The benefits of this aspect of therapy cannot be overstated. The psychosocial implications were immediately apparent.

## ACKNOWLEDGMENTS

The following organizations generously contributed to the care of this patient: the Academy of Osseointegration, Osseointegration Foundation, Charitable Grant Program; Nobel Biocare USA, Yorba Linda, CA (implant components); Prosthodontics Intermedica Foundation; Prosthodontics Intermedica (clinical, administrative, and laboratory staff); Fort Washington Dental Laboratory; Anesticare Inc (general anesthesia services); Angel Flight, Fort Washington, PA (air transportation); Stephen Eckert, DDS, Mayo Clinic (editorial assistance).

## REFERENCES

1. Tallgren A. The continuing reduction of the residual alveolar ridges in complete denture wearers: A mixed-longitudinal study covering 25 years. *J Prosthet Dent* 1972;27:120-132.
2. Brånemark P-I, Breine U, Adell R, Hansson BO, Ohlsson A. Intraosseous anchorage of dental prostheses. Part 1: Experimental studies. *Scand J Plast Reconstr Surg Hand Surg* 1969;3:81-100.
3. Lekholm U, van Steenberghe D, Hermann I, et al. Osseointegrated implants in the treatment of partially edentulous jaws: A prospective 5-year multicenter study. *Int J Oral Maxillofac Implants* 1994;9:627-635.
4. Henry P, Laney WR, Jemt T, et al. Osseointegrated implants for single tooth replacement: A prospective 5-year multicenter study. *Int J Oral Maxillofac Implants* 1996;11:450-455.
5. Jemt T, Chai J, Harnell J, et al. A 5-year prospective multicenter follow-up report on overdentures supported by osseointegrated implants. *Int J Oral Maxillofac Implants* 1996;11:291-298.
6. Schnitman PA, Wohrle PS, Rubenstein JE. Immediate fixed interim prostheses supported by two-stage threaded implants: Methodology and results. *J Oral Implantol* 1990;16:96-105.
7. Schnitman PA, Wohrle PS, Rubenstein JE, et al. Ten-year results for Brånemark implants immediately loaded with fixed prostheses at implant placement. *Int J Oral Maxillofac Implants* 1997;2(4):495-503.
8. Randow K, Ericsson I, Nilner K, Petersson A, Glantz P-O. Immediate functional loading of Brånemark dental implants: An 18-month clinical follow-up study. *Clin Oral Implants Res* 1999;10:8-15.
9. Balshi TJ, Wolfinger GJ. Immediate loading of Brånemark implants in edentulous mandibles: A preliminary report. *Implant Dent* 1997;6(2):83-88.
10. Brånemark P-I, Engstrand P, Öhrnell L-O, et al. Brånemark Novum: A new treatment concept for rehabilitation of the edentulous mandible. Preliminary results from a prospective clinical follow-up study. *Clin Implant Dent Relat Res* 1999;1:2-16.
11. Johansson P, Strid KG. Assessment of bone quality from cutting resistance during implant surgery. *Int J Oral Maxillofac Implants* 1994;9:279-288.
12. Lekholm U, Zarb GA. Patient selection and preparation. In: Brånemark P-I, Zarb GA, Albrektsson T (eds). *Tissue-Integrated Prostheses: Osseointegration in Clinical Dentistry*. Chicago: Quintessence, 1985:199-220.
13. Balshi TJ. The Biotes conversion prosthesis: A provisional fixed prosthesis supported by osseointegrated titanium fixtures for restoration of the edentulous jaw. *Quintessence Int* 1985;16:667-677.
14. Balshi TJ, Wolfinger GJ. Conversion prosthesis: A transitional fixed implant-supported prosthesis for an edentulous arch—A technical note. *Int J Oral Maxillofac Implants* 1996;11:106-111.