

Treatment of Congenital Ectodermal Dysplasia with Zygomatic Implants: A Case Report

Thomas J. Balshi, DDS ¹/Glenn J. Wolfinger, DMD¹

Dental abnormalities associated with ectodermal dysplasia (ED) can result in severe functional and esthetic problems. To correct these problems, dental implants have increasingly become the treatment of choice. This patient study illustrates the use of implants to rehabilitate a 20-year-old ED patient who initially presented with only 2 permanent and 6 primary teeth in the maxilla. Along with conventional endosseous implants, 2 specially designed zygomatic implants were utilized to avoid the need for bone grafting in the patient's severely resorbed maxilla. This expedited achievement of the final satisfactory result. (INT J ORAL MAXILLOFAC IMPLANTS 2002;17:277-281)

Key words: ectodermal dysplasia, endosseous dental implants, implant-supported dental prosthesis, zygoma

Ectodermal dysplasia (ED) is a syndrome of genetic disorders that are identified by abnormalities in at least 2 structures derived from the development of the ectoderm (the outer layer of cells in a developing embryo). Dental abnormalities have been associated with 80% of cases¹ and may include anodontia, hypodontia, misshapen teeth, taurodontia, supernumerary teeth, neonatal teeth, natal teeth, retained primary teeth, enamel hypoplasia, and lack of an alveolar ridge.²

First identified by Charles Darwin in the 1860s,³ ED is now recognized to include more than 120 subtypes,⁴ but 2 broad categories of the condition have been distinguished. In hypohidrotic ED, the sweat glands are decreased significantly or completely absent, and dental defects tend to be more numerous. In contrast, the sweat glands of hidrotic ED patients tend to be normal, but teeth, hair, and nails are affected.⁵ The incidence of hypohidrotic ED has been estimated to be as high as 7 in 10,000.⁶

Hypodontia resulting from ED appears to follow a definite pattern. Guckes and colleagues⁷ found that the permanent teeth most likely to be present in 52 ED patients were the maxillary central incisors (42%), followed by the maxillary first molars (41%)

and mandibular first molars (39%). Mandibular anterior teeth were the least likely to be present. In addition to the absence of teeth, ED can also lead to underdevelopment of the jaws. With little or no dental support, a hypoplastic maxilla and mandible result in bite collapse and narrowing of the alveolar ridges. This condition produces a collapsed appearance of the lower third of the face. In full frontal view (Fig 1), the reduction in size and width of the jaws and supporting musculature can be distractingly apparent. In profile, the underdeveloped jaws may create facial disharmony involving a retrognathic appearance. Such craniofacial deformities can be physically and/or psychologically devastating to the ED patient. A compromised appearance associated with congenital defects may inhibit normal social interactions and subconsciously detract from academic performance.

Conventional prosthodontic treatment for ED has consisted of various combinations of overdentures, complete or partial removable dentures, or fixed partial dentures.^{8,9} Numerous case reports have discussed the use of such traditional approaches for ED patients.¹⁰⁻¹⁴ However, well-fitting conventional dentures have proven difficult to create. Functional instability and poor retention are common because of the extremely thin alveolar ridges and the conical teeth found in such patients. Loading of the edentulous residual ridge at an early age may also cause progressive resorption of the alveolar bone and lead to subsequent prosthetic problems.⁵

¹Prosthodontics Intermedica, Fort Washington, Pennsylvania.

Reprint requests: Dr Glenn J. Wolfinger, Prosthodontics Intermedica, 467 Pennsylvania Avenue #210, Fort Washington, PA 19034. Fax: 215-643-1149. E-mail: PITEAM@aol.com

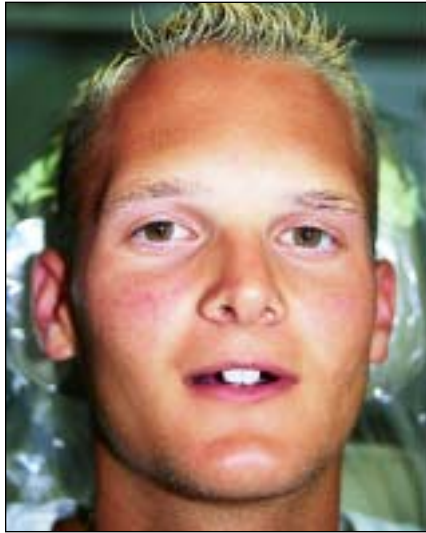

Fig 1 A narrow lower third of the face can be seen in this full frontal view of the patient.

Fig 2 Permanent maxillary central incisors and the residual primary dentition.

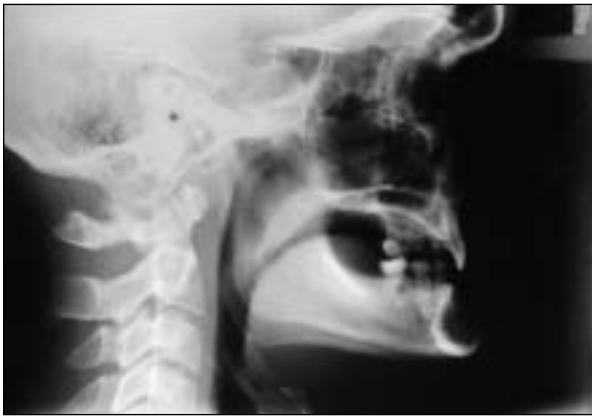
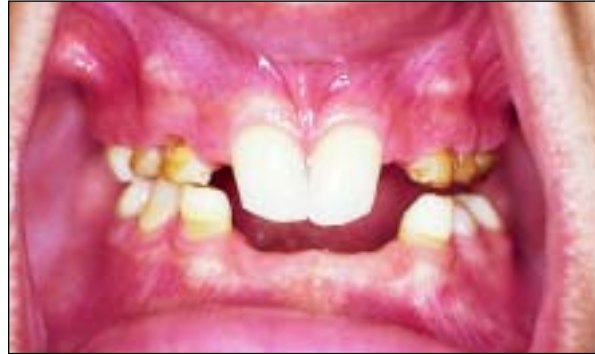
Fig 3 Loss of alveolar bone and severe collapse of the vertical dimension of occlusion are visible in the preoperative lateral cephalometric radiograph.

implants to support nonremovable teeth, bone grafting and tissue engineering, and advanced prosthodontic procedures. The following patient study is presented to illustrate the biomechanical and esthetic advantages of implant-related prosthodontic orofacial rehabilitation for an ED patient.

CASE REPORT

The patient was an otherwise healthy 20-year-old male who had been diagnosed with hypohidrotic ED at approximately age 4. He initially presented with only 2 permanent maxillary teeth, the central incisors (Fig 2). Also present were 6 maxillary primary posterior teeth, as well as 6 mandibular primary teeth (both canines and all first and second molars).

To appear socially acceptable in public, the patient had been using an acrylic resin maxillary overdenture that overlaid his severely deteriorated posterior dentition. An acrylic resin removable partial denture replaced the mandibular anterior teeth. Both of these temporary restorations were fabricated at his existing decreased vertical dimension of occlusion.

A comprehensive clinical and radiographic evaluation was performed. Panoramic, lateral, and cephalometric radiographs revealed significant underdevelopment of the alveolar bone (Fig 3). Intraoral periapical films also were used to diagnose conditions around the natural teeth.

A comprehensive treatment plan was formulated to include Brånemark System dental implants (Nobel Biocare, Yorba Linda, CA) in the anterior and premolar areas of the maxilla to provide cross-arch support for maximum biomechanical stability.

In recent years, endosseous implants have become recognized as an important alternative for ED patients.¹⁵⁻¹⁸ At the time of second-stage surgery, rates of clinical immobility for implants placed in ED patients have been shown to be comparable to those for non-ED edentulous patients.¹⁹ Despite the problems normally associated with placing dental implants in children, some evidence has even emerged that in edentulous children and adolescents with ED, endosseous implants may be placed with a high degree of predictability.⁵ For both adults and children, the stability offered by implant-supported prostheses results in better function and esthetics and may avoid the social drawbacks associated with dentures.

Orofacial rehabilitation of individuals afflicted with severe ED can benefit from modern treatment concepts. These may include the use of dental

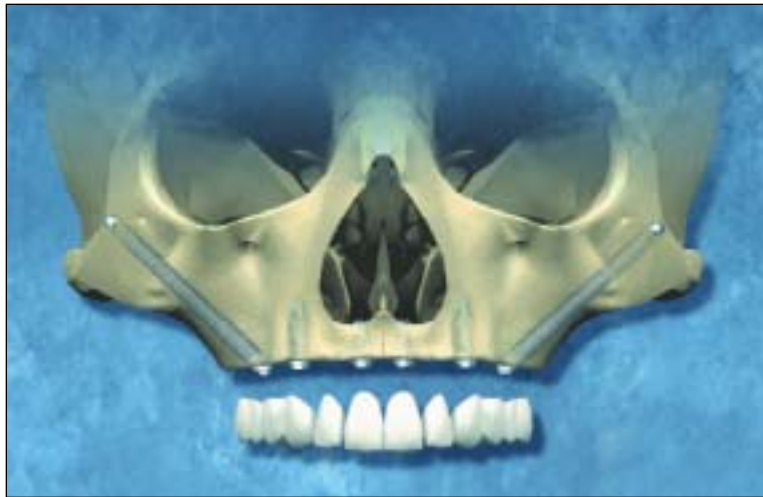


Fig 4 The zygomatic implant.

The decision was made by the authors to remove all of the patient's remaining teeth, both permanent and primary, and to simultaneously place implants. To avoid the need for bone grafting in the severely compromised posterior maxilla, the use of 2 zygomatic implants was also included in the treatment plan. These new and specially designed implants penetrate the zygoma and provide posterior support for a complete maxillary arch reconstruction (Fig 4). Whereas implants placed in maxillary grafted bone have been shown to have a success rate of 90% or higher,²⁰ initial studies of zygomatic implants conducted by Brånemark and coworkers have revealed a 96.8% clinical survival rate to date in 81 patients according to unpublished observations.

The treatment plan was discussed with both the patient and his parents, and several treatment alternatives were also presented. These included iliac bone grafting and long-term use of a complete removable prosthesis. The patient was emphatic that he wanted to be restored with a fully functional nonremovable dentition. The family had had a negative experience with an iliac crest graft several years previously, when the patient's older sister, also diagnosed with ED, had received an iliac crest graft that had subsequently failed.

The family thus decided to proceed with the treatment plan. Diagnostic casts were articulated to replicate the oral and craniofacial position of the existing oral structures 3-dimensionally in space. A diagnostic denture tooth setup was completed to serve as a provisional restoration during the osseointegration period. This denture also provided prototype positioning of the teeth and clarified the appropriate lip and cheek support needed, along with the required vertical dimension.

Under medically monitored general anesthesia in an outpatient setting, the patient's remaining natural teeth were removed. Four 3.75-mm-wide, 15-mm-long standard Brånemark System implants were placed in the anterior mandible between the mental foramina. Distal to the extraction socket of the last primary molar, 2 additional 4×10-mm Brånemark System implants were placed, one on each side. All bone from the mandibular osteotomy sites was harvested for possible use in the maxilla. Cover screws were placed over the implants. After thorough irrigation, the mandibular implant sites were closed with resorbable vicryl sutures.

Attention was then given to the maxilla, which was operated with bilateral antral openings. These created directional visibility for placement of the 2 zygomatic implants (40 mm on the right and 35 mm on the left). After these were placed, 6 additional implants were placed: 4 in the anterior maxilla and 1 each in the bilateral pterygomaxillary areas. The autogenous bone harvested from the mandibular implant osteotomy sites was combined with a natural, bovine-derived bone substitute (Bio-Oss, Osteohealth, Shirley, NY) and a platelet-rich plasma gel treated to release growth factors. This graft material was placed in the antral floor of the maxilla and around the zygomatic implants to increase the bone-to-implant surface contact area. The graft was added to the standard protocol in an effort to increase the extremely thin alveolar bone at the point of the implant penetrating the osseous crest. Platelet-rich plasma is known to improve the healing process.²¹

To minimize swelling and postsurgical discomfort, the patient followed a standard regimen of PenVK antibiotic (Par Pharmaceutical, Spring Valley, NY),

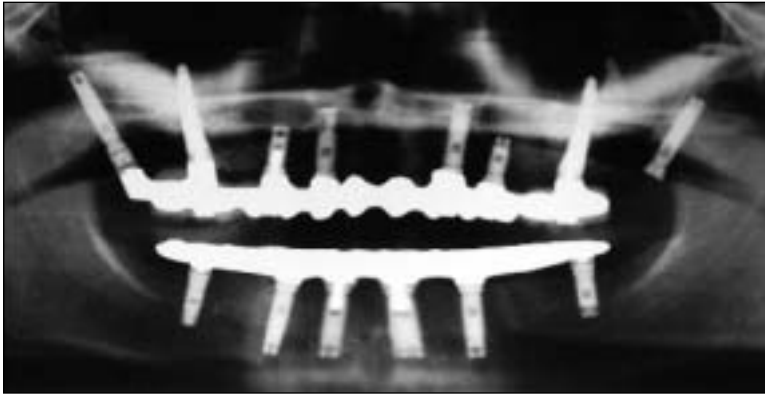

Fig 5a Postoperative panoramic radiograph.

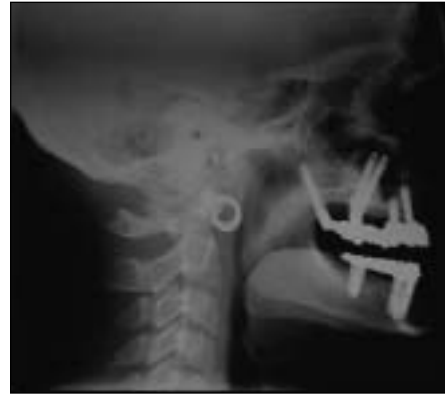

Fig 5b Postoperative lateral cephalometric radiograph.

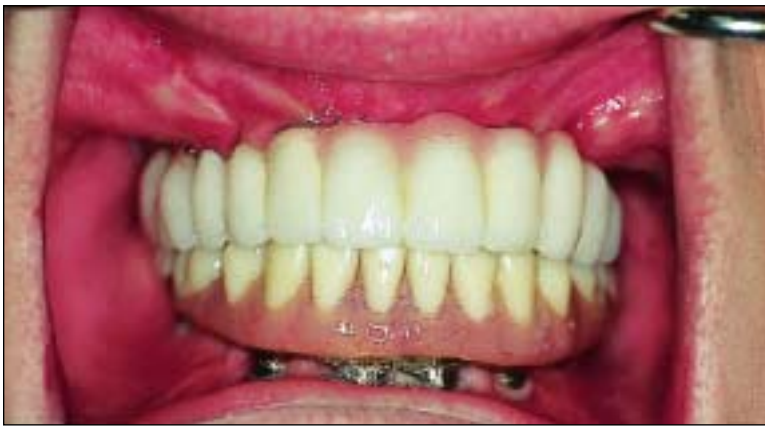

Fig 6a Postoperative intraoral frontal view.

Fig 6b (Right) The functional implant reconstruction and soft tissue support resulted in a pleasing full-face smile.



Decadron cortical steroid (Merck, West Point, PA), and pain medication for the first 48 hours after the implant placement surgery. The patient was also advised to use Peridex antimicrobial mouthwash (Zila Pharmaceuticals, Phoenix, AZ).

Ten days later, the patient returned for suture removal (while vicryl is resorbable, it takes several months for resorption to occur). At the same time, prefabricated temporary maxillary and mandibular removable complete dentures to which a soft lining had been applied were seated. Healing proceeded uneventfully for 3 months, at which point the conventional mandibular second-stage surgery was completed and a traditional implant-supported fixed prosthesis was fabricated with previously determined arch form and vertical dimension.

Second-stage surgery was completed for the maxilla 5 months after the implants had been placed. Angled abutments were used with each zygoma implant to position the prosthetic retaining

screw toward the occlusal table. The left pterygo-maxillary implant exhibited sensitivity and, despite the fact that it was clinically immobile (Figs 5a and 5b), it was not used.

A 1-piece gold casting was designed and created on a master cast obtained from a full-arch plaster impression made 1 hour after the abutments were fastened to the implants. This casting had cross-bars traversing the palate to prevent distortion during the porcelain firing stages, a technique previously developed by one of the authors and Mr Robert Winkleman of the Fort Washington Dental Laboratory (Fort Washington, PA). Buccal support for the lips and cheeks was provided by a conversion prosthesis.²²⁻²⁴ The final ceramometal fixed prosthesis filled the labial and buccal spaces that had been void as a result of the underdevelopment of the maxilla (Fig 6a). A positive smile line that complemented the patient's lip line resulted (Fig 6b).

The patient was shown a video presentation that elucidated proper methods for achieving acceptable hygiene after implant therapy. He was also instructed to continue treatment with oral hygiene visits every 3 months during the first postoperative year, every 4 months the second postoperative year, and every 6 months thereafter.

CONCLUSION

This clinically successful treatment was enhanced by the brevity of the treatment process. Use of the zygomatic implants, which anchored the maxillary prosthesis in stable bone, offered the patient several advantages. It avoided the hospital visit generally required for an iliac crest transplant, reduced the total treatment time by eliminating the months usually required for bone grafts to mature before implants can be placed, and eliminated the necessity of additional healing time required for implants placed in grafted bone.

REFERENCES

- Holbrook KA. Structural abnormalities of the epidermally derived appendages in the skin from patients with ectodermal dysplasia: Insight into developmental errors. In: Salinas CF, Optiz JM, Paul NW (eds). *Recent Advances in Ectodermal Dysplasias*. New York: Alan R. Liss, 1988:15-44.
- Witkop CJ, Brearley LJ, Gentry WC Jr. Hypoplastic enamel, onycholysis, and hypohidrosis inherited as an autosomal dominant trait. A review of ectodermal dysplasia syndromes. *Oral Surg Oral Med Oral Pathol* 1975;39:71-86.
- National Foundation for Ectodermal Dysplasias website: www.nfed.org.
- Newton F-M, Pinheiro M. Ectodermal dysplasias: Some recollections and classification. In: Salinas CF, Optiz JM, Paul NW (eds). *Recent Advances in Ectodermal Dysplasias*. New York: Alan R. Liss, 1988,3-14.
- Kearns G, Sharma A, Perrott D, Schmidt B, Kaban L, Vargervik K. Placement of endosseous implants in children and adolescents with hereditary ectodermal dysplasia. *Oral Surg Oral Med Oral Pathol Oral Radiol Endod* 1999;88:5-10.
- National Foundation for Ectodermal Dysplasias, Mascoutah, Illinois.
- Guckes AD, Roberts MW, McCarthy GR. Pattern of permanent teeth present in individuals with ectodermal dysplasia and severe hypodontia suggests treatment with dental implants. *Pediatr Dent* 1998;20:278-280.
- Bolender CL, Law DB, Austin LB. Prosthodontic treatment of ectodermal dysplasia. (A case report). *J Prosthet Dent* 1964;14:317-325.
- Snawder KD. Considerations in dental treatment of children with ectodermal dysplasia. *J Am Dent Assoc* 1976;93:1177-1179.
- Nortje C, Farman A, Thomas CH, Watermeyer G. X-linked hypohidrotic ectodermal dysplasia: An unusual prosthetic problem. *J Prosthet Dent* 1978;40:137-142.
- Herer P. Treatment of anhidrotic ectodermal dysplasia: Report of case. *J Dent Child* 1975;42:133-136.
- Grinberg S, Jover P, Quiros L, Diaz L, Terron F. Ectodermal dysplasia: Report of two female cases. *J Dent Child* 1980;47:193-195.
- Brodie A, Sarnat B. Ectodermal dysplasia anhidrotic type with complete anodontia. *Am J Dis Child* 1942;64:1046-1054.
- Sarnat B, Brodie A, Kubacki W. Fourteen year report of facial growth in case of complete anodontia with ectodermal dysplasia. *Am J Dis Child* 1953;86:162-169.
- Perrott DH, Sharma A, Vargervik K. Endosseous implants for pediatric patients. *Oral Maxillofac Surg Clin North Am* 1994;6(1):79-88.
- Bergendal T, Eckerdal O, Hallensten A-L, Koch G, Kurol J, Kvint S. Osseointegrated implants in the oral rehabilitation of a boy with ectodermal dysplasia: A case report. *Int Dent J* 1991;41:149-156.
- Guckes AD, Brahim JS, McCarthy GR, Rudy SF, Cooper LF. Using endosseous implants for patients with ectodermal dysplasia. *J Am Dent Assoc* 1991;122:59-62.
- Smith R, Vargervik K, Kearns G, Bosch C, Koumjian J. Placement of an endosseous implant in a growing child with ectodermal dysplasia. *Oral Surg Oral Med Oral Pathol* 1993;75:669-673.
- Guckes AD, Brahim JS, Rudy SF, McCarthy GR. Use of titanium screw implants in individuals with ectodermal dysplasia [abstract no. 1771]. *J Dent Res* 1991;70:487.
- Jensen OT, Shulman LB, Block MS, Iacono VJ. Report of the Sinus Consensus Conference of 1996. *Int J Oral Maxillofac Implants* 1998;13(suppl):11-32.
- Marx RE, Carlson ER, Eichstaedt RM, Schimmele SR, Strauss JE, Georgeff KR. Platelet-rich plasma: Growth factor enhancement for bone graft. *Oral Surg Oral Med Oral Pathol Oral Radiol Endod* 1998;85(6):638-646.
- Balshi TJ. The Biotec conversion prosthesis: A provisional fixed prosthesis supported by osseointegrated titanium implants for restoration of the edentulous jaw. *Quintessence Int* 1985;16:667-677.
- Balshi TJ. The conversion prosthesis: A provisional fixed prosthesis supported by osseointegrated titanium implants. In: van Steenberghe D, Albrektsson T (eds). *Tissue Integration in Oral and Maxillo-facial Reconstruction: Proceedings of an International Congress, May 1985, Brussels. Amsterdam: Excerpta Medica, 1986:354-365.*
- Balshi TJ, Wolfinger GJ. Conversion prosthesis: A transitional fixed implant-supported prosthesis for an edentulous arch—A technical note. *Int J Oral Maxillofac Implants* 1996;11:106-111.