

# Oral Rehabilitation with Osseointegrated Implants in a Patient with Oromandibular Dystonia with Blepharospasm (Brueghel's Syndrome): A Patient History

Miguel Peñarrocha, MD, DDS<sup>1</sup>/Jose Maria Sanchis, MD, DDS<sup>2</sup>/  
Javier Rambla<sup>3</sup>/M. Angeles Sánchez, MD, DDS<sup>4</sup>

*Oromandibular dystonia with blepharospasm (also known as Brueghel's syndrome, Meige's syndrome, or idiopathic orofacial dystonia) is characterized by intense and involuntary spasms of the orofacial muscles, with a frequent loss of teeth and occlusal alterations that worsen the dystonic manifestations and cause mucosal lesions that can lead to complete edentulism. The history of a patient with oromandibular dystonia who was rehabilitated with mandibular overdentures supported by endosteal implants is presented. Oral rehabilitation with implant-supported overdentures improved the situation, despite serious problems with instability. Mandibular overdentures supported by endosteal implants were satisfactorily used to re-establish occlusion, ensuring prosthetic stability and improving the dynamics of the masticatory muscles. (INT J ORAL MAXILLOFAC IMPLANTS 2001;16:115-117)*

**Key words:** blepharospasm, Brueghel's syndrome, oromandibular dystonia

Oromandibular dystonia with blepharospasm (also known as Brueghel's syndrome, Meige's syndrome, or idiopathic orofacial dystonia) is an adult disorder (the usual age of onset is over 50 years) with an unknown etiology characterized mainly by prolonged symmetric dystonic contractions of the orofacial muscles. It occurs more frequently in women. Patients with this disorder exhibit bizarre facial contortions and are frequently disabled. In Brueghel's syndrome, the orofacial dystonic movements are characteristically slow and intense and last for 20 to 30 seconds. The movements can be triggered by emotional stress, reading,

watching television, fatigue, or speech.<sup>1</sup> Both blepharospasm and orofacial dystonia may occur in patients with known diseases of the basal ganglia, such as those that cause symptomatic torsion dystonia, or are subjected to treatment with antipsychotic agents. The condition may also present as isolated dystonia in middle or late adult life in otherwise normal individuals.<sup>2</sup> The patient presented here demonstrated spasms and contractions of the facial, lingual, and masticatory muscles typical of idiopathic oromandibular dystonia.<sup>2</sup>

Blepharospasm consists of involuntary shutting of the eyelids and is characterized by the presence of tonic bilateral and more or less symmetric and arrhythmic contractions of the orbital muscles.<sup>3</sup> Oromandibular dystonia in turn consists of prolonged spasmodic contractions of the muscles of the mouth and jaws; these dystonic movements appear to be distinct from the chewing, lip-smacking, and tongue-rolling choreiform movements seen in more familiar orofacial dyskinesia.<sup>2</sup>

The present article describes a patient with oromandibular dystonia who was rehabilitated with mandibular overdentures supported by endosteal implants.

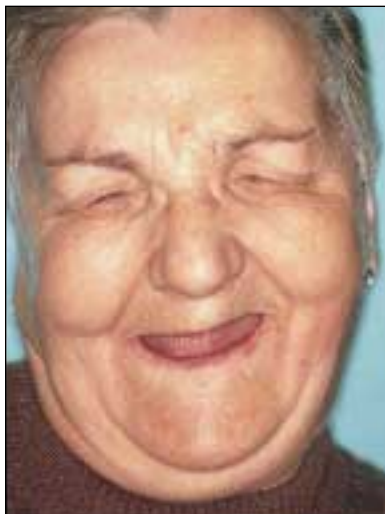<sup>1</sup>Assistant Professor of Oral Medicine, Valencia University Dental School, Valencia, Spain.

<sup>2</sup>Associate Professor of Oral Surgery, Valencia University Dental School, Valencia, Spain.

<sup>3</sup>Dentist, Valencia University Dental School, Valencia, Spain.

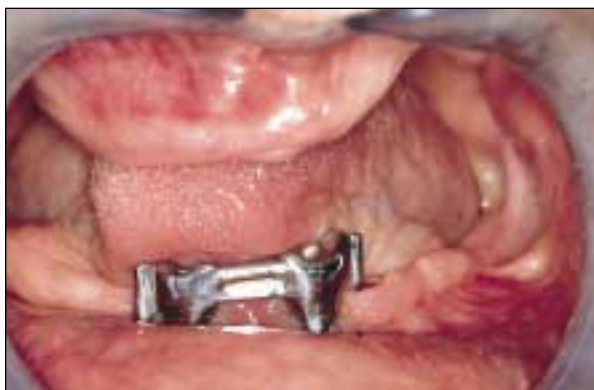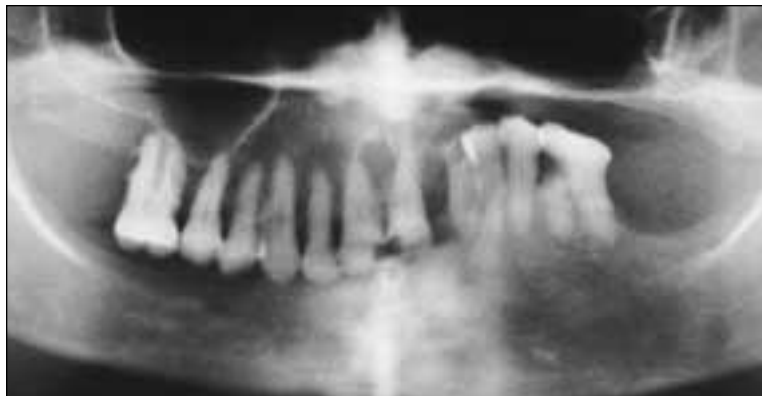
<sup>4</sup>Associate Professor of Oral Surgery, Barcelona University Dental School, Barcelona, Spain.

**Reprint requests:** Dr M. Peñarrocha-Diago, Clínica Odontológica, c/o Gascó Oliag 1, 46021 Valencia, Spain. Fax: +34-96-3864785.



**Fig 1** (Left) Facial view of the patient showing orofacial dystonic movements and blepharospasm.

**Fig 2** (Below) Panoramic radiograph showing the presence of teeth in the right maxilla and left mandible.



**Fig 3** Intraoral view of the implants and bony-mucosal support for the overdentures.

## CASE REPORT

A 67-year-old woman who had suffered oromandibular dystonia for the previous 2 years presented with repeated traumatic ulcerations of the lower lip. There were no other personal or family antecedents of interest. The dystonia was being treated with clonazepam (6 mg/day) and amitriptyline (75 mg/day). She presented small, involuntary, continuous positional dystonic movements of the mandible, lips, and tongue (Fig 1). Oral examination revealed numerous edentulous spaces in both jaws, which prevented stable occlusion and caused multiple ulcerations of the mucosa of the alveolar processes (Fig 2).

The remaining teeth were removed, with alveoplasty of the maxillary and mandibular processes. After a 4-week healing period, 2 cylindrical 3i implants (Implant Innovations, Inc, West Palm

Beach, FL) were surgically positioned within the chin region. The postoperative course was uneventful. Four months later, a mandibular overdenture supported by 2 endosteal implants, as well as a conventional complete maxillary denture, were positioned (Fig 3).

The patient reported that the oral rehabilitation improved mastication and speech, although the oromandibular spasms progressed. Associated blepharospasm developed 2 years later, and although botulin toxin infiltration afforded initial improvement, the movements subsequently became refractory to treatment. Five years after placement of the implants, the latter show osseointegration with prosthesis stability, and the patient maintains adequate occlusion.

## DISCUSSION

The significance of dental alterations in dystonia is not entirely clear, although tooth loss is thought to cause a decrease in afferent proprioceptive impulses and an alteration of the modulation mechanisms of the central nervous system, which may trigger or worsen the dystonia.<sup>4-6</sup> According to Fletcher et al,<sup>4</sup> dystonia may be precipitated by peripheral injuries. In some patients, oromandibular dystonia has been seen to develop after dental treatment, and in blepharospasm, a history of preceding local ocular disease has been documented in about 12% of cases. Similar observations apply to tardive dyskinesia, which is facilitated or exacerbated by edentulism<sup>7</sup>; occlusal rehabilitation may thus afford improvement of anomalous movements in these patients.<sup>8</sup>

Management of the dental aspects of the condition should seek to preserve as much tissue as possible.<sup>5</sup> Prosthetic rehabilitation is important in helping to ensure a normal occlusion that is capable of securing a stable mandibular position and adequate muscle rest without worsening the dystonic movements. In this sense, complete denture rehabilitation poses serious difficulties, especially in the mandible, because of the marked instability involved. This problem can be resolved by placing mandibular implants that facilitate adequate prosthetic stability and the restoration of occlusion.

In the present situation, as in the patient with tardive dyskinesia reported by Kelleher et al,<sup>9</sup> partial tooth loss and occlusal alterations preceded the appearance of involuntary movements, and therefore it was decided to utilize a mandibular overdenture supported by endosteal implants. Both the surgical phase and the prosthetic rehabilitation period were uneventful and, in the 5 years of follow-up, the patient slowly stabilized her oromandibular dystonic movements, with improved function and esthetic results. In contrast, the blepharospasm worsened. A review of the literature yielded no descriptions of patients with idiopathic orofacial dystonia rehabilitated with implants.

## REFERENCES

1. Tolosa ES. Clinical features of Meige's disease (idiopathic orofacial dystonia). A report of 17 cases. *Arch Neurol* 1981; 38:147-151.
2. Marsden CD. Blepharospasm-oromandibular dystonia syndrome (Brueghel's syndrome). A variant of adult-onset torsion dystonia? *J Neurol Neurosurg Psychiatr* 1976;39: 1204-1209.
3. Burguera JA, Del Olmo A, Peñarrocha M, Chumillas MJ, López Arlandis JM, Yayá R. Blefarospasmo-distonías craneales. Revisión de 19 casos de nuestra casuística. *Rev Neurol* 1988;16:163-172.
4. Fletcher NA, Harding AE, Marsden CD. The relationship between trauma and idiopathic torsion dystonia. *J Neurol Neurosurg Psychiatr* 1991;54:713-717.
5. Stevens MR, Wong ME. Meige syndrome: An unusual cause of involuntary facial movements. *Oral Surg Oral Med Oral Pathol* 1988;66:427-429.
6. Peñarrocha M. Enfermedades del sistema motor orofacial. In: Bagán JV, Ceballos A, Bermejo A, Aguirre JM, Peñarrocha M (eds). *Medicina Oral*. Barcelona: Masson, 1995:432-433.
7. Myers DE, Schooler NR, Zullo TG, Levin H. A retrospective study of the effects of edentulism on the severity rating of tardive dyskinesia. *J Prosthet Dent* 1993;69:578-581.
8. Sutchter HD, Underwood RB, Beatty RA, Sugar O. Orofacial dyskinesia. A dental dimension. *JAMA* 1971;31: 1459-1463.
9. Kelleher GD, Scott JJ, Djemal S. Case report: Complications of rehabilitation using osseointegrated implants—Tardive dyskinesia. *Eur J Prosthodont Restorative Dent* 1998;6: 133-136.

## JOMI GOES ONLINE IN 2001

*The International Journal of Oral and Maxillofacial Implants* offers a new benefit to subscribers in 2001:

You can now enjoy an online subscription to this valuable resource, with full access to all the articles and images in the print version, at no additional cost.

Just go to the Quintessence website at

**[www.quintpub.com](http://www.quintpub.com)**

and follow the simple, step-by-step instructions for registering your online subscription to JOMI. It's as easy as that.

*Access to the JOMI Web Edition is free for a limited time to anyone who visits the site, so encourage your colleagues to visit!*