

Healing of Dehiscence Defects at Delayed-Immediate Implant Sites Primarily Closed by a Rotated Palatal Flap Following Extraction

Carlos E. Nemcovsky, DMD¹/ Zvi Artzi, DMD¹/ Ofer Moses, DMD²/ Ilana Gelernter, MA³

In 21 patients, 28 maxillary teeth were extracted because of periapical or periodontal infection, root fracture, or untreatable caries. A rotated palatal flap procedure was used to achieve primary soft tissue closure over extraction sites. At 5 to 7 weeks postextraction, 28 implants were placed. Buccal dehiscence-type defects were treated with guided bone regeneration procedures using bovine bone mineral and resorbable collagen membranes. Mean defect area at the time of implant placement (23.7 mm², SD 11.49) was significantly reduced at uncovering (0.7 mm², SD 0.99). The mean percentage of defect reduction (clinical bone fill) was 97% (SD 4.26). Implants placed in compromised sites shortly postextraction according to the presented 2-stage protocol gave good short-term clinical results. (INT J ORAL MAXILLOFAC IMPLANTS 2000;15: 550–558)

Key words: alveolar bone loss, dental implants, endosseous dental implantation, guided tissue regeneration

Immediate implant procedures are carried out at the time of tooth extraction, whereas in delayed-immediate implant procedures, soft tissues overlying the extraction socket are allowed to heal for 30 to 60 days before implant placement. In the classical staged approach, soft and hard tissue healing is advanced or completed by the time of implant placement.^{1–3}

Implants placed immediately postextraction have proven to be a successful, predictable treatment modality.^{4–14} The number of surgical appointments and length of the surgical-restorative procedure are reduced, thereby presenting esthetic and functional

benefits.^{5,7} An occlusive barrier membrane is not always necessary in small bony enveloped defects when placing implants in fresh extraction sites.^{8–12,15,16} However, in larger defects a barrier membrane is used with or without bone grafting materials.^{17–20} There are certain disadvantages that could jeopardize the success of immediate implant procedures, such as lack of soft tissue closure over the extraction site,^{6,7,10–12,17,19,21–23} varying dimensions of implant and empty alveolus, a partially or totally missing bony housing, and periapical and/or periodontal infection.^{6,24,25} Membrane dehiscence in immediate implant procedures is more common than in implant procedures carried out 6 to 8 weeks postextraction.^{13,26} Early exposure of barrier membranes has a detrimental effect on bone regeneration around implants.^{9,19,20,27–34} Immediate implant placement in the presence of an active infection has been reported.^{6,35} However, this protocol may influence treatment outcome³⁵ and complicate surgery because of the difficulty in flap manipulation and in obtaining appropriate elimination of the infection from hard tissues.^{6,24,25}

Primary wound closure is important in achieving earlier higher tensile strength of the wound.³⁶ Several different flap designs to achieve primary closure over extraction sites have been described.^{15–17,37–41}

¹Lecturer, Department of Periodontology, The Maurice and Gabriela Goldschleger School of Dental Medicine, Tel Aviv University, Tel Aviv, Israel.

²Clinical Lecturer, Department of Periodontology, The Maurice and Gabriela Goldschleger School of Dental Medicine, Tel Aviv University, Tel Aviv, Israel.

³Statistical Consultant, Statistical Laboratory, Department of Mathematics, Sackler Faculty of Exact Science, Tel Aviv University, Tel Aviv, Israel.

Reprint requests: Dr Carlos E. Nemcovsky, Department of Periodontology, The Maurice and Gabriela Goldschleger School of Dental Medicine, Tel Aviv University, Tel Aviv, Israel. Fax: +972-3-6409250.

Table 1 Pre- and Postoperative Measurements of the Height and Width of Bony Defects for All Implants in Both (1 and 2 Proximal Implants) Groups

Implant no.	Age	Tooth	Height (mm)		Width (mm)	
			Preop	Postop	Preop	Postop
Group I (1 implant)						
1	55	L. central incisor	9	5	1	1
2	59	R. lateral incisor	7	6	0	0
3	37	R. lateral incisor	11	6	0	0
4	62	L. central incisor	4	4	0	0
5	41	R. central incisor	7	4	0	0
6	59	R. lateral incisor	5	4	0	0
7	51	R. central incisor	6	4	2	2
8	60	L. lateral incisor	7	4	0	0
9	47	L. first premolar	8	4	0	0
10	52	L. central incisor	6	4	1	1
11	55	R. lateral incisor	5	4	1	1
12	48	L. central incisor	8	5	1	2
13	66	R. canine	10	5	0	0
14	67	R. central incisor	5	5	0	0
Group II (2 implants)						
1a	49	L. lateral incisor	5	4	1	1
1b		L. canine	10	4	0	0
2a	54	R. canine	4	3	0	0
2b		R. first premolar	7	4	1	1
3a	46	R. second premolar	5	3	1	1
3b		R. first molar	8	6	1	2
4a	61	L. second premolar	4	3	0	0
4b		L. first molar	7	5	2	2
5a	64	R. canine	10	5	1	1
5b		R. first premolar	4	3	0	0
6a	50	L. first premolar	7	5	2	2
6b		L. second premolar	3	3	0	0
7a	65	R. central incisor	10	5	1	1
7b		R. lateral incisor	5	4	1	1

A surgical approach, based on a full-thickness rotated palatal flap (RPF), to obtain primary soft tissue coverage over single extraction sites after immediate implant placement has been presented, but it does not allow for simultaneous use of a barrier membrane.¹²

The purpose of the present study was to evaluate the use of a RPF procedure to achieve primary soft tissue closure over fresh maxillary extraction sockets prior to delayed-immediate implantation combined with guided bone regeneration procedures carried out 5 to 7 weeks postextraction. The outcome of clinical bone healing of the buccal dehiscence-type defects in this particular 2-stage surgical protocol was assessed.

MATERIALS AND METHODS

In 21 patients (mean age 54.9 years, SD 8.29) selected from a group of patients scheduled for max-

illary tooth extraction, 28 consecutive maxillary teeth were extracted because of periapical or periodontal infection, root fracture, or untreatable caries. Immediate implantation was not carried out because of large bony defects, infection, and/or treatment convenience. A single tooth was extracted in 14 patients, and 2 proximal teeth were extracted in 7 patients, for a total of 8 central and 7 lateral incisors, 4 canines, 4 first and 3 second premolars, and 2 first molars (Table 1). Proximal teeth were extracted in the same clinical session. Draining fistulae and clinical signs of periapical and/or periodontal inflammation were evident in the treatment area in 12 patients. Patients who smoked more than 10 cigarettes a day were excluded. All patients willing to participate signed an informed consent form, and the study was approved by the University Ethics Committee.

The following protocol was used to place 28 consecutive delayed-immediate implants. After local anesthesia was administered, thickness of the palatal soft tissues was determined with a millimetric

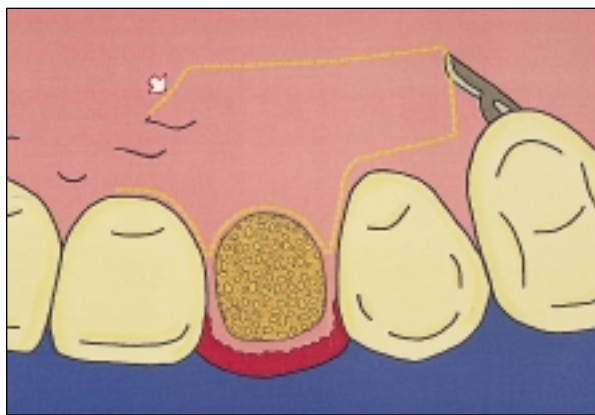


Fig 1a Diagram of incision for RPF. An internal beveled incision delineating a pedicled full-thickness palatal flap was made. An oblique proximal incision facilitated rotation of the pedicle (arrow), which was wider than 5 mm.

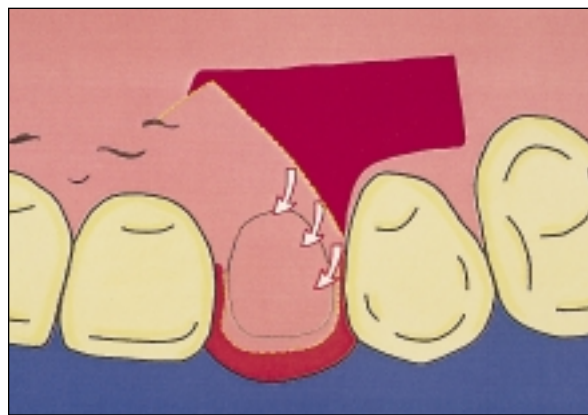


Fig 1b The palatal flap is rotated (arrows), tucked, and sutured under the minimally reflected buccal flap, covering the fresh empty alveolus.

periodontal probe.¹² An intrasulcular incision was made around the maxillary tooth (or teeth) to be extracted and the proximal palatal aspect of the adjacent teeth. A palatal approach was used for careful, atraumatic tooth extraction, followed by elimination of granulation tissue, epithelium, and bone-inserting Sharpey's fibers. At this time, a Miller spoon-shape contra-angulated surgical curette (Hu-Friedy Mfg Co Inc, Chicago, IL) was used to explore and estimate the integrity of the bony walls of the alveolus. The present delayed-immediate implant protocol was always selected when there were draining fistulae and/or need for bone augmentation procedures with use of a barrier membrane necessitated by a largely damaged buccal bony plate accompanied by 4 mm or less of palatal tissue.

Primary closure over extraction sockets was achieved through an RPF. This surgical approach was presented previously.¹² Briefly, a minimal buccal flap, including only interdental papillae and marginal gingiva, was reflected in the extracted tooth (or teeth) area only. An internal beveled incision delineating a pedicled full-thickness palatal flap was made (Fig 1a). The pedicle should preferably be distal to the midline of the extracted teeth to receive nourishment and avoid cutting the palatal vessels. The extension was sufficient to completely cover the alveolus. An oblique proximal incision facilitated rotation of the pedicle (Fig 1a). The RPF was raised, rotated, tucked, and sutured under the minimally reflected buccal flap to achieve primary soft tissue closure over the empty alveoli (Fig 1b). The portion of the RPF covered by the buccal flap was de-epithelialized before suturing. Additional sutures secured the RPF in the palatal tissues. No filler was used at this stage. Sutures were removed after 7 to 10 days.

After 5 to 7 weeks of healing (Fig 2a), a second procedure was carried out to place the implants. Screw-type implants were procured from Steri-Oss (Yorba Linda, CA, $n = 20$) and Calcitek (Splintec, Carlsbad, CA, $n = 8$). Their surface was either micro-textured titanium ($n = 8$) or titanium plasma-sprayed ($n = 20$). Implant diameters were either 3.75 mm (3.8 mm) or 4.5 mm. Implant length ranged from 12 to 16 mm (2 implants were 12 mm, 9 implants were 14 mm, 8 implants were 15 mm, and 9 implants were 16 mm). Different implant types and manufacturers were not compared because of the small subgroups.

A straight palatal incision, parallel to the bone crest at the level of the disto- and mesiopalatal line angles, and 2 proximal releasing incisions, extending beyond the mucogingival junction, delineated a full-thickness buccal flap. Buccal and palatal flaps were reflected. All soft tissue was eliminated from the vacated alveolus. Implant receptor sites were prepared by sequential cutting according to a previously prepared surgical guide, with reduced low speed with internally and/or externally irrigated drills (Fig 2b). Implants were placed into the prepared sites level with or 1 mm apical to the height of the most coronal wall of the bony housing, but not less than 3 mm and not more than 5 mm apical to the cemento-enamel junction of proximal teeth.⁴² In instances of gingival recession, these measurements were related to the gingival margin, which was marked on the surgical guide (Fig 2c). Implants were placed apically, extending beyond the tooth socket, and primary stability was achieved for all implants.

After implant placement, the distance from the most apical aspect of the buccal crestal bone to the coronal aspect of the implant body (defect height) and the widest mesiodistal dimension of the buccal bony

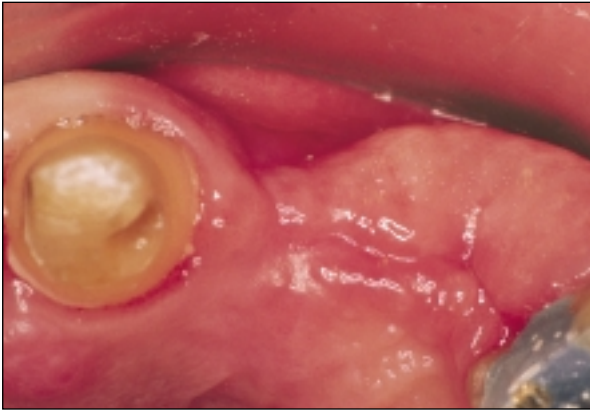

Fig 2a Treatment area 5 weeks postextraction. Note soft tissue healing and preservation of ridge form.

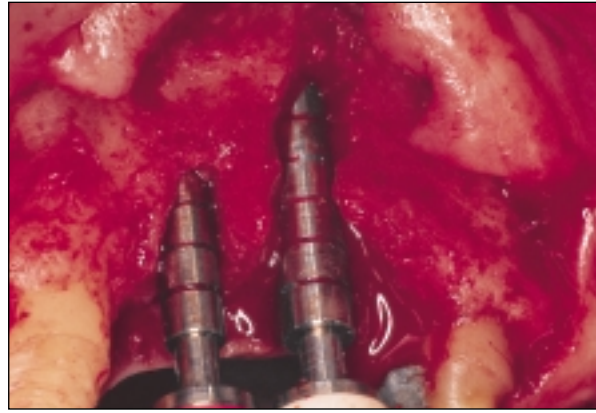


Fig 2b Following implant site preparation, implant body try-ins are placed; the dimensions of the bony defect can be seen.

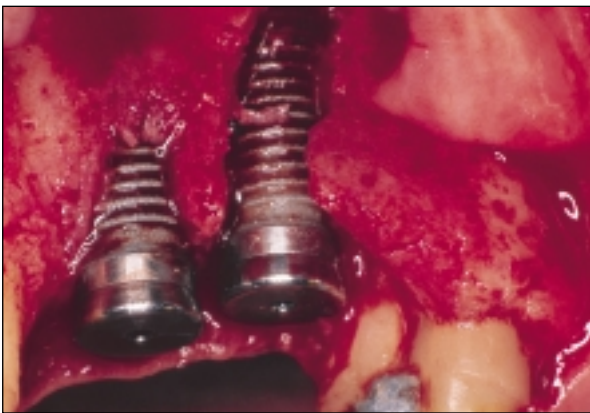


Fig 2c Implants in place. Note large bone dehiscence around implants. The implant in the area of the left canine is extensively exposed.

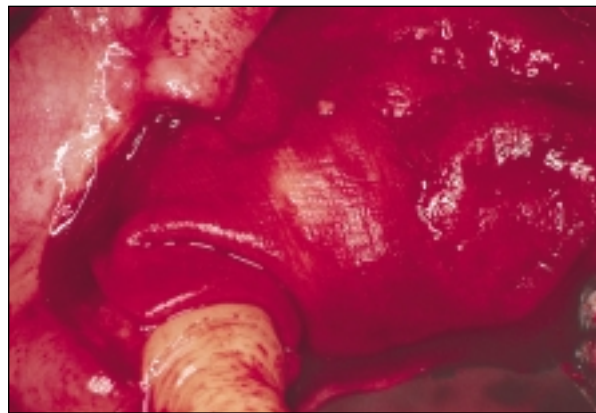


Fig 2d Treatment area following bone grafting with bovine bone mineral and application of a resorbable collagen membrane.

defect (defect width) were measured. A 15-mm color-coded periodontal probe (Hu-Friedy Mfg Co), placed parallel and perpendicular, respectively, to the long axis of the implant, was used. Measurements were recorded to the nearest millimeter. At this time, the need for a bone regenerative procedure was evaluated. The decision as to whether or not to use a membrane was based on the dimensions of the bony defect around the implant. Further augmentation procedures were not used when implants were within a bony envelope, even if partially missing. However, a membrane was applied when larger defects, exceeding a 4-mm dehiscence, were evident or where the bony housing was missing and more than one-fourth of the implant perimeter, at its final position, was exposed.

The present study included only those implants for which a guided bone regeneration procedure was applied accordingly. A resorbable collagen membrane (Bio-Gide, Geistlich Sohne AG, Wolhusen, Switzerland) and bone grafting with a bovine bone mineral (Bio-Oss, Geistlich Sohne AG) were used.

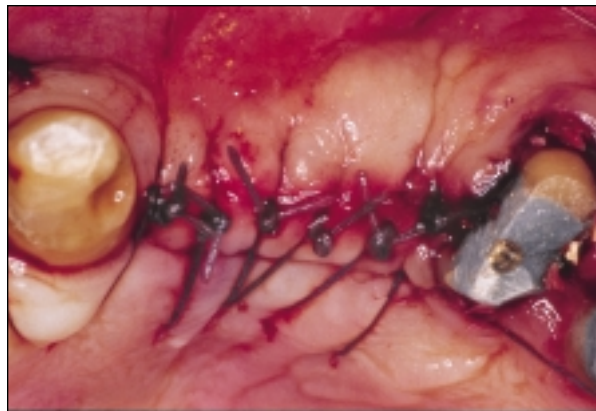


Fig 2e Surgical site following implantation and guided bone regeneration procedures. Note palatal incision within the RPF and primary soft tissue closure.

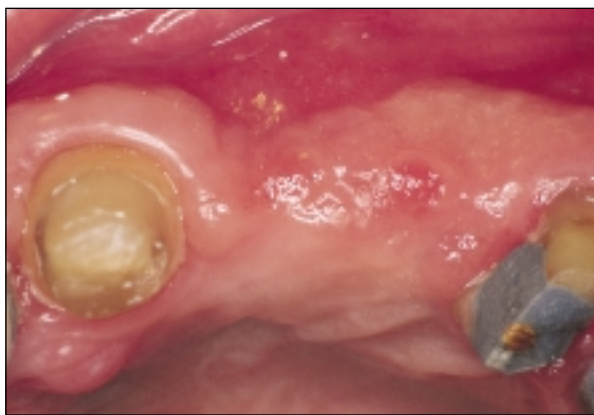

Fig 3a Occlusal aspect of ridge 7 months postoperatively, before implant uncovering.

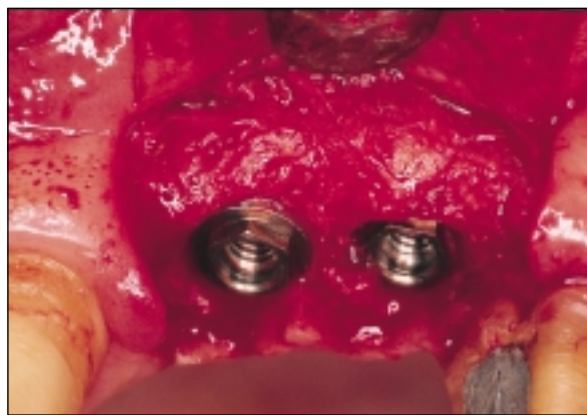


Fig 3b Clinical bone regeneration is evident at the time of implant uncovering. The bone defects are completely healed.

Since both implants and bone graft material supported the membrane, no further support was used (Fig 2d). An apical periosteal fenestration with undermining sharp dissection provided a partial-thickness buccal flap, which could be coronally displaced and sutured without tension to the palatal tissues (Fig 2e). Complete soft tissue coverage of the membrane was achieved. Sutures were removed after 7 to 10 days.

Implants were uncovered after 6 to 8 months (Figs 3a and 3b). The height and width of the buccal bony defect were measured again. The surface area of the bony defect was calculated as half ellipses by multiplying the defect width by the defect height by $\pi/4$ (≈ 0.79). The percentage of defect fill at second-stage implant surgery was calculated as:

$$\frac{\text{area at baseline} - \text{area at second-stage surgery}}{\text{area at baseline}} \times 100^{2,26,28}$$

Non-parametric Wilcoxon signed ranks test and non-parametric Mann-Whitney test were used to analyze the data; group 1 (1 implant) and group 2 (2 implants) were independently analyzed and compared. Where 2 implants were placed simultaneously, results were combined and their mean was used.

RESULTS

Postsurgical pain and swelling were minimal after tooth extraction and RPF procedures. The pedicled flap blended with the surrounding tissue. Immediate postsurgical bleeding in the palate was rare; when it did occur, it was easily controlled with extra

palatal sutures. There was no late postsurgical bleeding. During the early healing phase, a small cleft could be seen in several sites between the RPF and the buccal flap, but it healed. After 5 to 7 weeks, soft tissue over the extraction sites was completely healed clinically (Fig 2a). Full soft tissue closure was easily achieved at the time of implant placement, combined with bone regenerative procedures. There was no early exposure of the implant body cover screw in any of the implants. At the time of uncovering, all implants were clinically stable. The mucogingival junction appeared to be congruent with proximal teeth or only slightly coronally displaced.

Pre- and postoperative measurements of the height and width of the bony defects for all 28 implants (from both groups) are presented in Table 1. Mean and median values and ranges are presented in Table 2. According to the Wilcoxon signed ranks test, the difference between the 2 surgical phases in the dehiscenced area around the implants was statistically significant ($P = .018$ for the single-implant group and $P = .015$ for the 2-implant group). The Mann-Whitney test revealed a statistically non-significant difference between groups ($P = .08$) in the reduction of the exposed area around implants.

DISCUSSION

During the first 3 to 6 months postextraction, marked resorption of residual alveolar bone usually takes place, during which the quality and prognosis of the final restoration can deteriorate.^{5,7,36} Defect morphologies that allow for improved bone regeneration usually occur in immediate or short-term

Table 2 Means, Medians, and Ranges of Pre- and Postoperative Defect Size Measurements (in mm) for All Implants, Independently for Each Group

	Mean	SD	Median	Range
<i>Group I (1 implant)</i>				
Preoperative				
Height	6.7	2.23	7.0	4.0 to 11.0
Width	4.3	0.90	4.0	4.0 to 6.0
Area	23.7	11.49	21.98	12.56 to 51.81
Postoperative				
Height	0.6	0.69	0.00	0.0 to 2.00
Width	0.7	0.77	0.00	0.0 to 2.00
Area	0.7	0.99	0.00	0.0 to 3.14
Defect fill (%)	97.0	4.26	100.00	83.3 to 100.00
<i>Group II (2 implants)</i>				
Preoperative				
Height	6.36	1.029	6.50	5.00 to 7.50
Width	4.07	0.345	4.00	3.50 to 4.50
Area	20.57	4.424	22.12	15.21 to 26.66
Postoperative				
Height	0.79	0.267	1.00	0.50 to 1.00
Width	0.86	0.378	1.00	0.50 to 1.50
Area	0.59	0.395	0.79	0.20 to 1.19
Defect fill (%)	97.05	1.955	97.04	94.87 to 99.17

delayed placement.²⁶ Therefore, when delayed or late implantation is considered, this fact should be weighed. A delayed-immediate implant procedure in which placement is delayed for several weeks postextraction overcomes a number of these disadvantages while providing advantages of its own.⁴³

Resorption of the alveolar crest postextraction may be delayed by timely placement of the implant,^{2,5,26,44} and longer implants could be used in early compared to late implantation procedures.² Generally, early implantation procedures are preferred in the anterior maxillary region, which is frequently affected by a significant degree of atrophy immediately postextraction and where esthetics is of prime importance. In the mandible and posterior maxilla, where the atrophic process is slower, delayed implantation may be more convenient.¹³

Draining fistulae and clinical signs of infection were evident in 43% of the sites. Although placement of immediate implants into chronically infected sites resulting from periapical pathosis has been clinically reported,⁴⁵ a histomorphometric study in dogs has shown that bone-to-implant contact is higher when there is no infection at the time of tooth extraction.³⁵ The presented 2-phase protocol enables elimination of infection previous to implantation and bone augmentation procedures.^{24,25}

A histopathologic study of extraction wounds in dogs⁴⁶ has shown that sockets are covered with sur-

face epithelium and young fibrous connective tissue 28 days postextraction. In studies conducted on wound healing in dermal tissues, a timeline of tensile strength has shown that after 1 week the wound had only 3% of the strength of unwounded skin,³⁶ after 3 weeks it had 20%, and after 3 months it was approximately 80%. Primary wound closure over extraction sites influences the time to complete wound healing. Healing by primary or secondary intention determines the role of wound contraction in the healing process.⁴⁷ In wound healing, epithelial cells migrate at a rate of about 0.2 mm per day and granulation tissue serves as the bed for the advancement of those cells.⁴⁷ Approximation of wound edges and early primary coverage of the extraction site by the flaps are important in accelerating wound healing by reducing the mass of granulation tissue and appropriately obliterating the dead wound space.^{36,48} Restoration of tissue continuity and early development of tissue strength following wounding are initially achieved by the formation of a myofibroblast-reticulin network, which develops faster if primary closure is procured.⁴⁹

Several flap designs have been proposed to achieve primary closure over extraction sites.^{15-17,37-41} The described surgical approach is advantageous since the RPF preserves part of its blood supply. A minimal buccal flap is raised; consequently, adherence of the periosteum to bone is not interrupted. The osseous

surface is not exposed at the time of tooth extraction, which further reduces unnecessary bone plate resorption. Striking resorption of bone occurs where a mucoperiosteal flap is raised. This process starts with accelerated resorptive activity and, in humans, begins within a few days postsurgery, typically peaks at 1 to 2 months, and may take more than 6 months to subside.⁵⁰

Primary flap closure and maintenance over augmented implants are important for final results.^{9,18-20,26-33,51,52} In early implant procedures, wound dehiscence is more common than in later procedures.^{2,13,26} During flap elevation for implant placement, the soft tissue covering the extraction site, which presents diminished strength, tears easily. Sutures placed across the previous extraction site before flap elevation could eliminate this inconvenience.¹ In the present surgical procedure, the incision is placed within the previous RPF. Since this tissue was rotated as a whole, soft tissue surgical management complications are minimal.

The current study includes only those patients in whom large bony defects, exceeding a 4-mm dehiscence of the buccal plate, were present and a large portion of the bony housing around the implants was missing.^{53,54} The 2-stage surgical approach allows for the bone defect around the implants to be covered by a membrane. A resorbable collagen barrier membrane was used in all instances, since this material is not as stiff as the non-resorbable membranes. The addition of filler as a graft is indicated to prevent the membrane's collapse and maintain the space beneath for bone regeneration. Collagen barrier membranes, combined with bovine bone mineral, have been shown clinically and histologically to facilitate guided bone regeneration around exposed implant threads.^{2,26,55} However, contradictory results have also been reported.¹⁰

In a previous study, complete bone healing was not observed in immediate implant sites with the use of a resorbable membrane where the implant body cover screws became spontaneously exposed.¹² Early exposure causes premature collagen membrane breakdown at the exposed site. In the present study, early exposure of the implant body cover screws did not occur. Bone fill around the implants was evident at second-stage implant surgery (Fig 3b). Most of the defects seen at the time of implant placement were apparently healed. However, this was a clinical observation, and no histologic study of the bone-like tissue that filled the defects or of the bone-implant interface was carried out.⁵⁴

Crestal bone healing relative to the initial bone crest-implant distance at the time of implant placement was approximately 91%. All measurements

were assessed to the coronal aspect of the implant body, although the osseous level was expected to be approximately at the level of the first thread shortly after abutment connection.⁵⁶ Overall, 97% of the defect area found at the time of implant placement appeared to be clinically healed at implant uncovering. In 50% of patients, the dehiscence around implants at the time of placement had completely healed. These results were identical to another clinical report in which early implantation was carried out in combination with similar guided bone regeneration (GBR) procedures.²⁶ However, the amount of bone fill was slightly larger than in other studies in which long-term delayed implantation was combined with GBR.^{28,51} This higher percentage of bone fill with earlier implants could be encouraged by the remaining bony walls²⁶ (Fig 2b). In a dog model, 85% of the original bone gain at membrane-augmented implant sites was lost 6 months after loading.⁵⁷ However, in human clinical studies, tissues regenerated in successfully treated implant-associated defects were maintained for short- and long-term periods following prosthetic loading.^{58,59}

In the present study, all 28 implants appeared clinically stable at the time of uncovering. Further soft and hard tissue augmentation procedures were not performed and adequate prosthetic rehabilitation could be completed.

CONCLUSIONS

1. Delayed-immediate implantation is an acceptable treatment approach.
2. Use of an RPF for primary soft tissue healing over maxillary extraction sites prior to delayed-immediate implantation, combined with bone augmentation procedures, is a valuable surgical procedure to improve soft tissue healing and achieve easier flap management.
3. Implants can be placed in compromised sites shortly after tooth extraction, combined with bone regenerative techniques incorporating the use of bovine bone material and resorbable collagen membranes.
4. Healing of large defects can be expected at the time of implant uncovering when the presented 2-phase protocol is applied.

ACKNOWLEDGMENT

The authors wish to thank Rita Lazar for editorial assistance and preparation of the manuscript.

REFERENCES

1. Wilson TG, Weber HP. Classification of and therapy for areas of deficient bony housing prior to dental implant placement. *Int J Periodontics Restorative Dent* 1993;13:451-459.
2. Zitzmann NU, Naef R, Schüpbach P, Schaerer P. Immediate or delayed immediate implantation versus late implantation when using the principles of guided bone regeneration. *Acta Med Dent Helv* 1996;1:221-227.
3. Cavicchia F, Bravi F. Case reports offer a challenge to treatment strategies for immediate implants. *Int J Periodontics Restorative Dent* 1999;19:67-81.
4. Block MS, Kent JN. Placement of endosseous implants into tooth extraction sites. *J Oral Maxillofac Surg* 1991;49:1269-1276.
5. Werbitt MJ, Goldberg PV. The immediate implant: Bone preservation and bone regeneration. *Int J Periodontics Restorative Dent* 1992;12:207-217.
6. Rosenquist B, Grenthe B. Immediate placement of implants into extraction sockets: Implant survival. *Int J Oral Maxillofac Implants* 1996;11:205-209.
7. Gelb DA. Immediate implant surgery: Three-year retrospective evaluation of 50 consecutive cases. *Int J Oral Maxillofac Implants* 1993;8:388-399.
8. Schwartz-Arad D, Chaushu G. Placement of implants into fresh extraction sites: 4 to 7 years retrospective evaluation of 95 immediate implants. *J Periodontol* 1997;68:1110-1116.
9. Becker W, Becker BE, Polizzi G, Bergström C. Autogenous bone grafting of bone defects adjacent to implants placed into immediate extraction sockets in patients: A prospective study. *Int J Oral Maxillofac Implants* 1994;9:389-396.
10. Becker BE, Becker W, Ricci A, Geurs N. A prospective clinical trial of endosseous screw-shaped implants placed at the time of tooth extraction without augmentation. *J Periodontol* 1998;69:920-926.
11. Nemcovsky CE, Artzi Z, Moses O. Rotated split palatal flap for soft tissue primary coverage over extraction sites with immediate implant placement: Description of the surgical procedure and clinical results. *J Periodontol* 1999;70:926-934.
12. Nemcovsky CE, Artzi Z, Moses O. Rotated palatal flap in immediate implant procedures. Clinical evaluation of 26 consecutive cases. *Clin Oral Implants Res* 2000;11:83-90.
13. Mensdorff-Pouilly N, Haas R, Mailath G, Watzek G. The immediate implant: A retrospective study comparing the different types of immediate implantation. *Int J Oral Maxillofac Implants* 1994;9:571-578.
14. Watzek G, Haider R, Mensdorff-Pouilly N, Haas R. Immediate and delayed implantation for complete restoration of the jaw following extraction of all residual teeth: A retrospective study comparing different types of serial immediate implantation. *Int J Oral Maxillofac Implants* 1995;10:561-567.
15. Evian CI, Cutler S. Autogenous gingival grafts as epithelial barriers for immediate implants: Case reports. *J Periodontol* 1994;65:201-210.
16. Landsberg CJ. Socket seal surgery combined with immediate implant placement: A novel approach for single-tooth replacement. *Int J Periodontics Restorative Dent* 1997;17:141-149.
17. Becker W, Becker BE. Guided tissue regeneration for implants placed into extraction sockets and for implant dehiscences: Surgical techniques and case reports. *Int J Periodontics Restorative Dent* 1990;10:376-391.
18. Becker W, Dahlin C, Becker BE, Lekholm U, van Steenberghe D, Higuchi K, Kultje C. The use of e-PTFE barrier membranes for bone promotion around titanium implants placed into extraction sockets: A prospective multicenter study. *Int J Oral Maxillofac Implants* 1994;9:31-40.
19. Gher ME, Quintero G, Assad D, Monaco E, Richardson AE. Bone grafting and guided bone regeneration for immediate implants in humans. *J Periodontol* 1994;65:881-891.
20. Mellonig JT, Nevins M. Guided bone regeneration of bone defects associated with implants: An evidence-based outcome assessment. *Int J Periodontics Restorative Dent* 1995;15:168-185.
21. Block MS, Kent JN. Prospective review of integral implants. *Dent Clin North Am* 1992;36:27-37.
22. Rosenquist B. A comparison of various methods of soft tissue management following the immediate placement of implants into extraction sockets. *Int J Oral Maxillofac Implants* 1997;12:43-51.
23. Wilson TG, Schenk R, Buser D, Cochran D. Implants placed in immediate extraction sites: A report of histologic and histometric analyses of human biopsies. *Int J Oral Maxillofac Implants* 1998;13:333-341.
24. Ibbott CG, Kovach RJ, Carlsson-Mann LD. Acute periodontal abscess associated with an immediate implant site in the maintenance phase: A case report. *Int J Oral Maxillofac Implants* 1993;8:699-702.
25. Maarit AM, Salonen MAM, Oikarinen K, Virtanen K, Pernu H. Failures in the osseointegration of endosseous implants. *Int J Oral Maxillofac Implants* 1993;8:92-97.
26. Zitzmann NU, Naef R, Schärer P. Resorbable versus non-resorbable membranes in combination with Bio-Oss for guided bone regeneration. *Int J Oral Maxillofac Implants* 1997;12:844-852.
27. Gher ME, Quintero G, Sandifer JB, Tabacco M, Richardson AC. Combined dental implant and guided tissue regeneration therapy in humans. *Int J Periodontics Restorative Dent* 1994;14:332-347.
28. Jovanovic SA, Spiekermann H, Richter EJ. Bone regeneration around titanium dental implants in dehiscence defect sites: A clinical study. *Int J Oral Maxillofac Implants* 1992;12:29-45.
29. Lekholm U, Becker W, Dahlin C, Becker B, Donath K, Morrison E. The role of early versus late removal of GTAM membranes on bone formation at oral implants placed into immediate extraction sockets: An experimental study in dogs. *Clin Oral Implants Res* 1993;4:121-129.
30. Gotfredsen K, Nimb L, Buser D, Hjørtting-Hansen E. Evaluation of guided bone regeneration around implants placed into fresh extraction sockets: An experimental study in dogs. *J Oral Maxillofac Surg* 1993;51:879-884.
31. Simion M, Baldoni M, Rossi P, Zaffe D. A comparative study of the effectiveness of e-PTFE membranes with and without early exposure during the healing period. *Int J Periodontics Restorative Dent* 1994;14:167-180.
32. Nowzari H, Slots J. Microbiologic and clinical study of polytetrafluoroethylene membranes for guided bone regeneration around implants. *Int J Oral Maxillofac Implants* 1995;10:67-73.
33. Murphy KG. Postoperative healing complications associated with Gore-Tex periodontal material. *Int J Periodontics Restorative Dent* 1995;15:363-375.
34. Parr GR, Steflik DE, Sisk AL. Histomorphometric and histologic observations of bone healing around immediate implants in dogs. *Int J Oral Maxillofac Implants* 1993;8:534-540.

35. Novaes AB Jr, Vidigal GM Jr, Novaes AB, Grisi MF, Pollini S, Rosa A. Immediate implants placed into infected sites: A histomorphometric study in dogs. *Int J Oral Maxillofac Implants* 1998;13:422-427.
36. Pickett BP, Burgess LPA, Livermore GH, Tzikas TL, Vosoughi J. Wound healing. Tensile strength vs healing time for wounds closed under tension. *Arch Otolaryngol Head Neck Surg* 1996;122:565-568.
37. Bahat O, Handelsman M. Periodontal reconstructive flaps—Classification and surgical considerations. *Int J Periodontics Restorative Dent* 1991;11:481-487.
38. Edel A. The use of a connective tissue graft for closure over immediate implant covered with an occlusive membrane. *Clin Oral Implants Res* 1995;6:60-65.
39. Chen ST, Dahlin C. Connective tissue grafting for primary closure of extraction sockets treated with an osteopromotive membrane technique: Surgical technique and clinical results. *Int J Periodontics Restorative Dent* 1996;16:349-355.
40. Nemcovsky CE, Artzi Z. Split palatal flap: A surgical approach for primary soft tissue healing in ridge augmentation procedures. Technique and clinical results. *Int J Periodontics Restorative Dent* 1999;19:175-181.
41. Hurzeler MB, Weng D. Functional and esthetic outcome enhancement of periodontal surgery by application of plastic surgery principles. *Int J Periodontics Restorative Dent* 1999;19:37-43.
42. Salama H, Salama M. The role of orthodontic extrusive remodeling in the enhancement of soft and hard tissue profiles prior to implant placement: A systematic approach to the management of extraction site defects. *Int J Periodontics Restorative Dent* 1993;13:313-333.
43. Nir-Hadar N, Palmer M, Soskolne WA. Delayed immediate implants: Alveolar bone changes during the healing period. *Clin Oral Implants Res* 1998;9:26-33.
44. Brägger U, Hämmerle CHF, Lang NP. Immediate transmucosal implants using the principle of guided tissue regeneration (II). A cross-sectional study comparing the clinical outcome 1 year after immediate to standard implant placement. *Clin Oral Implants Res* 1996;7:268-276.
45. Novaes AB Jr, Novaes AB. Immediate implants placed into infected sites: A clinical report. *Int J Oral Maxillofac Implants* 1995;10:609-613.
46. Huebsch RF, Hansen LS. A histopathologic study of extraction wounds in dogs. *Oral Surg Oral Med Oral Pathol* 1969;28:187-196.
47. Witte MB, Barbul A. General principles of wound healing. *Surg Clin North Am* 1997;77:509-528.
48. Schilling JA. Wound healing. *Surg Clin North Am* 1976;56:859-874.
49. Forrest L. Current concepts in soft connective tissue wound healing. *Br J Surg* 1983;70:133-140.
50. Yaffe A, Fine N, Binderman I. Regional accelerated phenomenon in the mandible following mucoperiosteal flap surgery. *J Periodontol* 1994;65:79-83.
51. Dahlin C, Lekholm U, Becker W, Becker B, Higuchi K, Callens A, van Steenberghe D. Treatment of fenestration and dehiscence bone defects around oral implants using the guided tissue regeneration technique: A prospective multicenter study. *Int J Oral Maxillofac Implants* 1995;10:312-318.
52. Tolman DE. Reconstructive procedures with endosseous implants in grafted bone: A review of the literature. *Int J Oral Maxillofac Implants* 1995;10:275-294.
53. Knox R, Caudill RF, Meffert RM. Histologic evaluation of dental endosseous implants placed in surgically created extraction defects. *Int J Periodontics Restorative Dent* 1991;11:365-375.
54. Palmer RM, Floyd PD, Palmer PJ, Smith BJ, Johansson CB, Albrektsson T. Healing of implant dehiscence defects with and without expanded polytetrafluoroethylene membranes: A controlled clinical and histological study. *Clin Oral Implants Res* 1994;5:98-104.
55. Hurzeler MB, Kohal RJ, Naghshbandi J, Mota LF, Conrath J, Huttmacher D, Caffesse RG. Evaluation of a new bioresorbable barrier to facilitate guided bone regeneration around exposed implant threads. An experimental study in the monkey. *Int J Oral Maxillofac Surg* 1998;27:315-320.
56. Abrahamsson I, Berglundh T, Lindhe J. The mucosal barrier followig abutment dis/reconnection. An experimental study in dogs. *J Clin Periodontol* 1997;24:568-572.
57. Becker W, Lekholm U, Dahlin C, Becker BE, Donath K. The effect of clinical loading on bone regeneration by GTAM barriers: A study in dogs. *Int J Oral Maxillofac Implants* 1994;9:305-313.
58. Cordioli G, Majzoub Z, Riachi F. Postloading behavior of regenerated tissues in GBR-treated implant sites. *Int J Periodontics Restorative Dent* 1999;19:45-55.
59. Nevins M, Mellonig JT, Clem III DS, Reiser GM, Buser DA. Implants in regenerated bone: Long-term survival. *Int J Periodontics Restorative Dent* 1998;18:35-45.