

---

# Histomorphometric Evaluation of the Effect of Hyperbaric Oxygen Treatment on Healing Around Hydroxyapatite Implants in Irradiated Rat Bone

Xuan Chen, MD, DDS\*/Yoshiro Matsui, DDS, PhD\*\*/  
Kohsuke Ohno, DDS, PhD\*\*\*/Ken-ichi Michi, DDS, PhD\*\*\*\*

The effect of hyperbaric oxygen (HBO) on the tissue reaction around hydroxyapatite (HA) implants in irradiated bone of rats was investigated. A single dose of 15 Gy was delivered to the right leg of 20 rats. HA implants were placed in the bilateral tibial proximal metaphysis 3 months after irradiation. HBO was administered to half of the rats before and after 15-Gy irradiation. The healing process was examined histologically and histomorphometrically. The results indicated that HBO slightly improved trabecular bone formation in the irradiated bone, accelerated bone remodeling in the nonirradiated bone, and improved HA-bone contact in both the irradiated and nonirradiated bones.  
(INT J ORAL MAXILLOFAC IMPLANTS 1999;14:61-68)

**Key words:** hydroxyapatite implants, hyperbaric oxygen, irradiated bone, rat, tibia

---

Prostheses supported by endosteal implants have been developed as an alternative to conventional reconstructive surgery to improve the cosmetic and functional outcomes of patients with malignant oral and maxillofacial tumors. An increasing number of irradiated patients are treated using this technique, because radiotherapy in combination with surgery is the treatment commonly used for malignant tumors in this region.

Bone healing and regeneration are complex and depend on many factors. An adequate vascular system supplying bone tissue is necessary. Fibers and bone cells, as well as undifferentiated mesenchymal cells, must be present for adequate bone formation. Irradiation, however, induces hypocellularity, hypovascularity, and hypoxemia in tissues. Complications such as slow wound healing, long-standing infections, fistulation, loss of implants, and radionecrosis can occur after irradiation treatment. Some clinicians do not use implants because of the risk of postradiation osteonecrosis decreasing the success of a prosthetic restoration.<sup>1</sup> In addition, although the number of patients who have had titanium implants placed after irradiation is limited, the available data suggest a tendency toward higher implant loss frequency among them, compared with nonirradiated patients.<sup>2-4</sup>

Hyperbaric oxygen (HBO) therapy has been increasingly recognized as an effective method of restoring irradiation-damaged tissue. Hyperbaric oxygen therapy exerts its beneficial effects on osteogenesis based on factors secondary to the elevation of  $PO_2$ : the promotion of collagen synthesis, the promotion of vascular proliferation, and the initiation of osteoblast and osteoclast activi-

---

\*Research Fellow, First Department of Oral and Maxillofacial Surgery, Showa University, School of Dentistry, Tokyo, Japan.

\*\*Assistant Professor, First Department of Oral and Maxillofacial Surgery, Showa University, School of Dentistry, Tokyo, Japan.

\*\*\*Associate Professor, First Department of Oral and Maxillofacial Surgery, Showa University, School of Dentistry, Tokyo, Japan.

\*\*\*\*Professor, First Department of Oral and Maxillofacial Surgery, Showa University, School of Dentistry, Tokyo, Japan.

**Reprint requests:** Dr Yoshiro Matsui, First Department of Oral and Maxillofacial Surgery, Dental Hospital, Showa University, 2-1-1 Kitasenzoku Ohta-ku, Tokyo 145-8515, Japan. Fax: +81-3-3787-7104.

ties. In the maxillofacial region, HBO therapy has been useful in both the treatment and prevention of osteoradionecrosis and in reconstruction involving irradiated tissue.<sup>6-8</sup>

Two experimental studies have revealed the effects of HBO therapy on the osseointegration of implants placed in irradiated bone. Larsen et al<sup>9</sup> investigated the potential for osseointegration of cylindrical implants in irradiated tibias of rabbits with and without HBO treatment. They found that HBO therapy significantly improved the amount of histologic osseointegration. Johnsson et al<sup>10</sup> found that HBO therapy can increase the biomechanical force necessary to unscrew titanium implants in irradiated bone by 44%. In agreement with these experimental studies, several clinical reports also found that HBO therapy can improve the success rates of implants placed in irradiated patients.<sup>2-4,11,12</sup> However, Franzen et al<sup>13</sup> reported that osseointegration occurred, although to a lesser extent, without adjunctive hyperbaric oxygen and suggested that such measures are not always necessary in oral rehabilitation after radiotherapy. Thus, the role of HBO therapy in the integration of implants and the healing process around the implant have not yet been fully elucidated.

The present study investigated the tissue reaction after the placement of hydroxyapatite- (HA) coated implants in irradiated tibias of rats undergoing a course of HBO treatment. The objective was to obtain information for the application of implants in irradiated bone accompanied by HBO therapy.

### Materials and Methods

Twenty male Wistar rats 9 weeks old were used. The rats were sedated and a single dose of 15-Gy irradiation was delivered to the right leg of all rats from a Linac source.

Three months after the irradiation, 2-mm-diameter, high velocity flame-sprayed HA cylindrical implants (Asahi Optical, Tokyo, Japan) were placed bilaterally in the tibial proximal metaphysis of each rat. During implantation, general anesthesia was maintained with an intra-abdominal injection of sodium pentobarbital (0.1 mL per 100 g of body weight). The skin and fascia over the medial side of the proximal metaphysis were opened, and the periosteum was elevated. Each HA implant was placed into a site that was prepared with a 2.2-mm twist drill under continuous saline irrigation, as described by Matsui et al.<sup>14</sup> Following implantation, the fascia and skin were closed separately.

Ten rats received HBO therapy. The HBO treatments were administered with the following proto-

col: each fraction was kept at pure oxygen at 2.4 atmospheric absolute pressure (ATA) for 60 minutes in a 10.4-L pressure chamber (Hanyuda P-5100, Hanyuda, Tokyo, Japan). The time required for successive compression up to 2.4 ATA and for decompression was 30 minutes. The CO<sub>2</sub> produced was eliminated with a constant flow of O<sub>2</sub> with a flow rate of 1.0 L per minute. The treatments were done 5 days per week, 2 fractions per day, with a total of 20 fractions prior to surgery and 10 after implant placement. The rats were treated in the pressure chamber without anesthesia.

The implanted sites were divided into 4 groups: (1) left nonirradiated tibia of the non-HBO-treated rats; (2) right irradiated tibia of the non-HBO-treated rats; (3) left nonirradiated tibia of the HBO-treated rats; and (4) right irradiated tibia of the HBO-treated rats. Two rats each from among the non-HBO treated and HBO-treated animals were sacrificed at 7, 14, 28, 56, and 84 days after implantation. The implants with surrounding bone were removed; each specimen was then fixed in 10% buffered formalin, dehydrated, embedded in polyester resin, and sectioned parallel to the axes of the implants with an EXAKT cutting-grinding system (EXAKT, Hamburg, Germany) to a thickness of approximately 15  $\mu$ m. The sections were stained with 1% toluidine blue and inspected under a light microscope.

Histomorphometric measurements were obtained using a computer system with a video camera attached to a microscope (Mitani Corp, Tokyo, Japan) to measure the trabecular bone in the cavity and the percentage of HA-bone contact. Two sections from each specimen were prepared for measurement. The parameters measured were: total bone tissue (TBT); total trabecular bone volume (TTBV); trabecular bone-specific volume (tVsp = TTBV/TBT  $\times$  100); total implant surface area (TIS); total contacting surface area (TCS); and bone-contacting implant surface ratio (% BCSR = TCS/TIS  $\times$  100) (Fig 1).

### Results

**Histologic Findings. Nonirradiated, Non-HBO-Treated Group.** Many trabeculae had formed around the implants by 7 days. The trabeculae were lined by mature osteoblasts and marked osteoids; some had directly contacted the implant surface (Fig 2). After 14 days, many trabeculae were observed around the implant. There was little osteoid at the bone surface, and osteoclasts had resorbed the bone in some regions. Most of the implant surface contacted newly formed bone. At

28 days, the amount of trabecular bone around the implant had begun to decrease. Almost all of the implant surface was in contact with bone. However, the contacting bone thickness had decreased (Fig 3). At 56 days, trabecular bone volume around the implant had decreased again, and the contacting bone was thinner and more mature than that at 28 days. The histologic findings at 84 days were almost identical to those at 56 days.

**Irradiated, Non-HBO-Treated Group.** At 7 days, newly formed bone (mainly woven bone) existed around the implant. However, the bone volume and peripheral osteoid level were less than that in the nonirradiated, non-HBO-treated group. Almost all of the implant surface was covered with immature fibrous tissue (Fig 4). At 14 days, lamellar trabecular bone had formed in the medullary cavity, but the volume was lower than that of the nonirradiated, non-HBO-treated group at this period. Peripheral osteoids were rarely observed. Part of the implant surface directly contacted the newly formed bone. At 28 days, trabecular bone had begun to decrease. Most of the implant surface contacted the newly-formed bone; however, the contacting bone thickness was decreased (Fig 5). At 56 days, trabecular bone volume around the implant and the contacting bone thickness continued to decrease. The HA-bone contact was more prominent than that at 28 days. At 84 days, almost all of the implant surface contacted mature bone, similar to the findings in the nonirradiated, non-HBO-treated group.

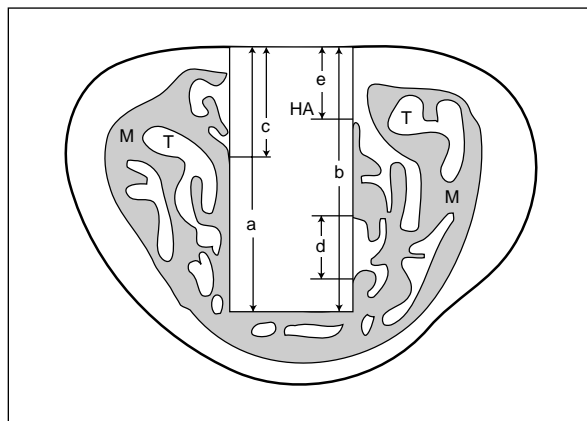
**Nonirradiated, HBO-Treated Group.** At 7 days, trabecular bone had formed in the medullary cavity. Its surface was surrounded mostly by osteoids



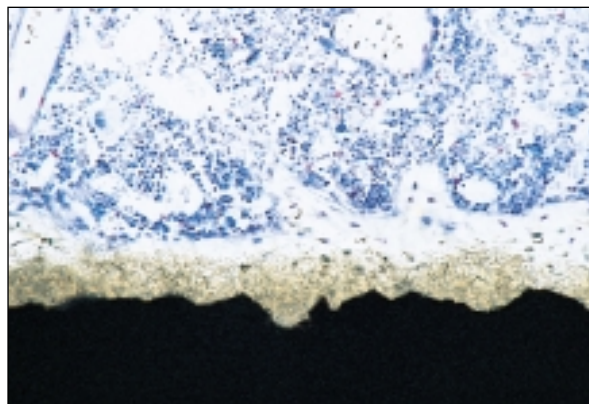
**Fig 2** Nonirradiated, non-HBO-treated group 7 days after implantation (1% toluidine blue stain; original magnification  $\times 50$ ). Many trabeculae, which were lined by mature osteoblasts and marked osteoids, had formed around the implant; some had directly contacted the implant surface. Bone directly contacted the implant surface (arrows).

and mature osteoblasts. Almost all of the implant surface was covered with newly formed, immature lamellar bone (Fig 6). At 14 days, trabecular bone volume around the implant had decreased. Almost all of the implant surface contacted the newly formed bone, but its thickness had decreased. Histologic findings at 28 days (Fig 7) were almost identical to those at 14 days, but trabecular bone volume around the implant and the thickness of the bone on the implant surface continued to decrease until 84 days after surgery.

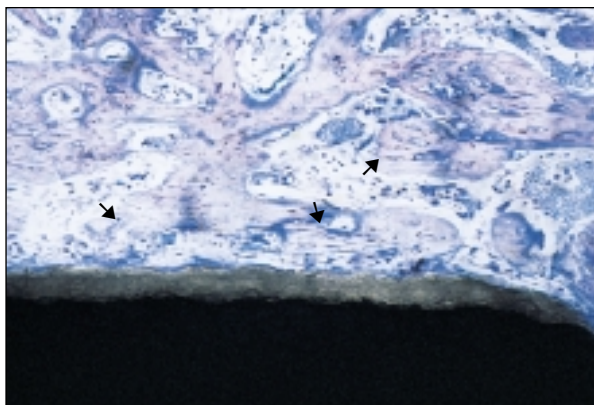
**Irradiated, HBO-Treated Group.** At 7 days, considerable lamellar bone had formed around the implant. Peripheral osteoids were more prominent



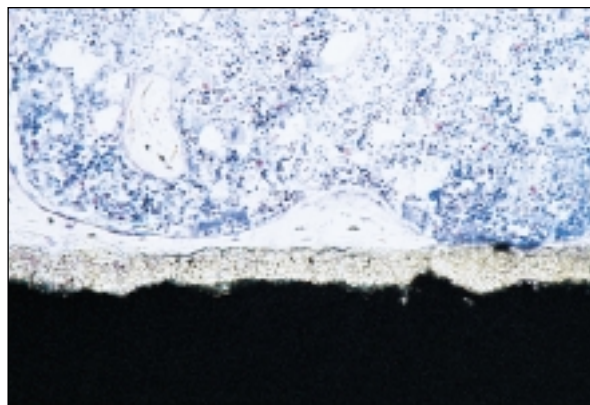
**Fig 1** Histomorphometric parameters. Total implant surface area (TIS) =  $a + b$ . Total contacting area (TCS) =  $c + d + e$ . Trabecular bone-specific volume (tVsp) was calculated by dividing the total volume of the trabecular bone (TTBV) by total bone tissue (TBT, the volume of the medullary cavity) and multiplying by 100. Bone-contacting surface ratio (%BCSR) was equal to  $TCS/TIS \times 100$ . T = trabecular bone; M = medullary cavity.



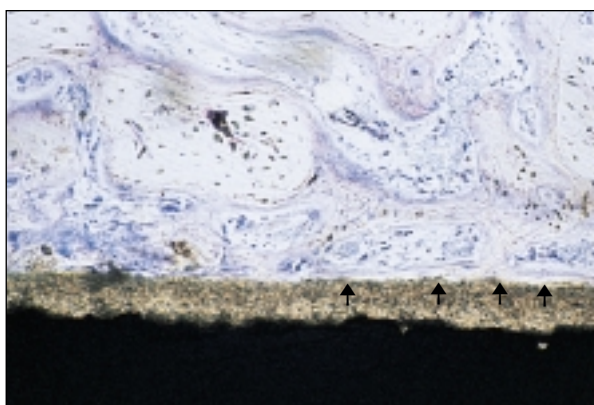
**Fig 3** Nonirradiated, non-HBO-treated group 28 days after implantation (1% toluidine blue stain; original magnification  $\times 50$ ). Almost all of the implant surface was in contact with bone.



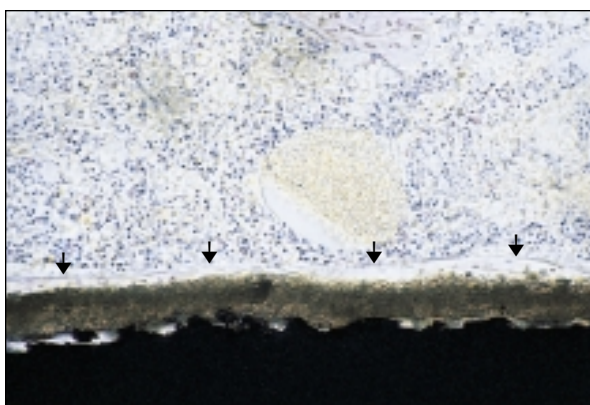
**Fig 4** Irradiated, non-HBO-treated group 7 days after implantation (1% toluidine blue stain; original magnification  $\times 50$ ). Newly formed bone, mainly woven bone, existed around the implant. However, the bone volume and peripheral osteoid level were lower than those of the nonirradiated, non-HBO-treated group. Almost all of the implant surface was covered with immature fibrous tissue. Woven bone was observed around the implant surface (*arrows*).



**Fig 5** Irradiated, non-HBO-treated group 28 days after implantation (1% toluidine blue stain; original magnification  $\times 50$ ). Most of the implant surface contacted the newly formed bone. However, the contacted bone was thin and the trabecular bone had begun to decrease.



**Fig 6** Nonirradiated, HBO-treated group 7 days after implantation (1% toluidine blue stain, original magnification  $\times 50$ ). Trabecular bone had formed in the medullary cavity. Almost all of the implant surface was covered with newly formed immature lamellar bone. Newly formed bone directly contacted the implant surface (*arrows*).

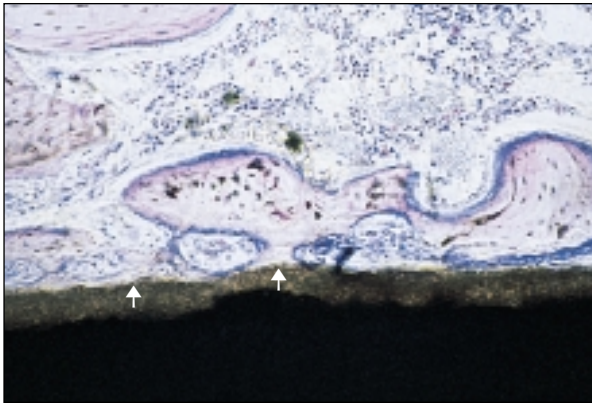


**Fig 7** Nonirradiated, HBO-treated group 28 days after implantation (1% toluidine blue stain; original magnification  $\times 50$ ). Trabecular bone volume around the implant had decreased. The contacting bone was matured and its thickness had decreased. Thin bone directly contacted the implant surface (*arrows*).

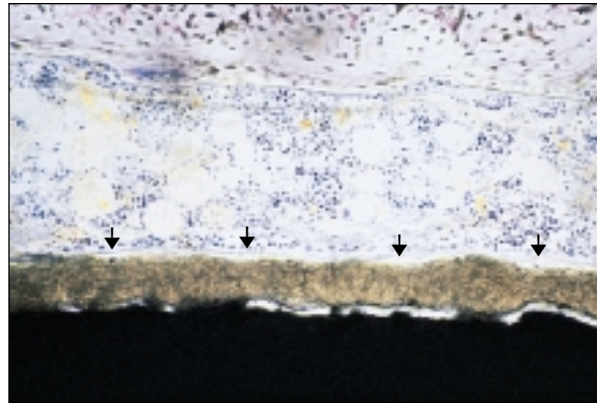
than they were in the irradiated, non-HBO-treated group at this point. Newly formed bone directly contacted part of the HA surface (Fig 8). By 14 days, many newly formed trabeculae were observed around the implant, and most of the HA surface directly contacted newly formed bone. At 28 days, trabecular bone around the implant had begun to decrease. Almost all of the implant surface was in contact with bone, which was thinner than that seen at 14 days (Fig 9). At 56 days, the HA surface contacted mature bone, a finding similar to that of the nonirradiated, non-HBO-treated group at the same point in time. The features of

the medullary cavity and implant-bone interface at 84 days were similar to those at 56 days.

**Histomorphometric Measurements.** *Trabecular Bone-Specific Volume.* In the nonirradiated, non-HBO-treated group, the average tVsp was highest at 7 days and then gradually decreased until 84 days after surgery. The progression observed in the nonirradiated, HBO-treated group was similar to that of the nonirradiated, non-HBO-treated group, but the value was much lower at all times examined. Unlike these 2 groups, the tVsp values of both irradiated groups (HBO-treated and non-HBO-treated) were highest at 14 days after place-



**Fig 8** Irradiated, HBO-treated group 7 days after implantation (1% toluidine blue stain; original magnification  $\times 50$ ). Considerable lamellar bone had formed around the implant, and peripheral osteoids were more prominent than in the irradiated, non-HBO-treated group. The newly-formed bone directly contacted part of the HA implant surface. Newly formed bone directly contacted the implant surface (arrows).



**Fig 9** Irradiated, HBO-treated group 28 days after implantation (1% toluidine blue stain; original magnification  $\times 50$ ). The trabecular bone around the implant had begun to decrease. Almost all of the implant surface was in contact with bone, a finding almost identical to that in the nonirradiated, non-HBO-treated group. Thin bone directly contacted the implant surface (arrows).

ment. All values calculated in the irradiated, HBO-treated group were higher than those of the irradiated, non-HBO-treated group but lower than those of the nonirradiated, non-HBO-treated group at all times examined except one (Table 1, Fig 10).

**Bone-Contacting Implant Surface Ratio.** In the nonirradiated, non-HBO-treated group, the rate of increase of % BCSR was very high from 7 to 14 days after surgery. It exceeded 90% after 14 days and changed very little after this time. In the irradiated, non-HBO-treated group, % BCSR was less than 20% at 7 days. It continued to increase gradually and exceeded 90% at 84 days. However, this group had the lowest value among the 4 groups at each time point examined. In the nonirradiated, HBO-treated group, the average % BCSR was over 90% after 7 days and stabilized at this level through 84 days. In the irradiated, HBO-treated group, the average % BCSR was about 40% at 7 days. It increased gradually between 7 and 28 days and exceeded 90% at 28 days with little further change after that (Table 2, Fig 11).

## Discussion

This study examined the effects of HBO therapy on healing around implants in irradiated bone. A single dose of 15 Gy irradiation was administered 3 months before the placement of HA-coated implants into the rat tibia. Hyperbaric oxygen treatment was performed before and after the operation. Although the radiation dose and delivery schedule may not be sufficient to truly reflect

the common radiation pathology for humans (since the host tissue response has been reported to be species-specific), the administration of 15 Gy in a single dose used in this study is biologically equivalent to 23 2-Gy sessions administered 5 times per week for 4½ weeks in humans.<sup>15</sup>

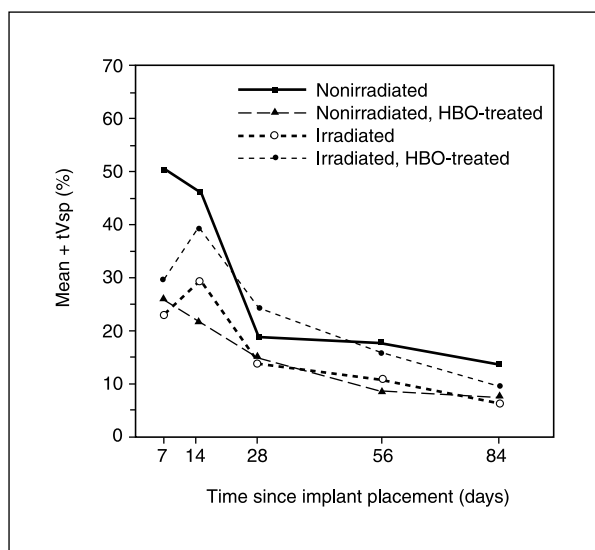
A rat tibia model has been shown to be useful in analyzing the process leading to osseointegration. Osseointegration has been shown to occur at 6 weeks in the rat tibia model, demonstrating many of the same characteristics seen in humans.<sup>16</sup> Placement of the implants was performed 3 months after irradiation in the present study, because HA-bone contact is generally retarded for 3 months after irradiation.<sup>14</sup> Hydroxyapatite is a biologically compatible material.<sup>17</sup>

The HBO therapy protocol used in the present study was as follows: 60 minutes at 2.4 ATA with a 100% inspired flow of oxygen twice a day, with 20 sessions before the operation and 10 sessions after the operation. This protocol was designed to simulate the protocol used for humans as closely as possible. To avoid oxygen toxicity in the use of HBO therapy, safe time-dose limits have been established for humans. Generally, treatments last between 90 and 120 minutes and are administered once or twice daily.<sup>18</sup> Ueda et al clinically investigated the effect of HBO on the osseointegration of titanium implants in irradiated bone. In that study, HBO was performed 20 and 10 times before and after implant surgery, respectively, and the atmospheric pressure inside the chamber was elevated to 2 or 3 ATA.<sup>12</sup>

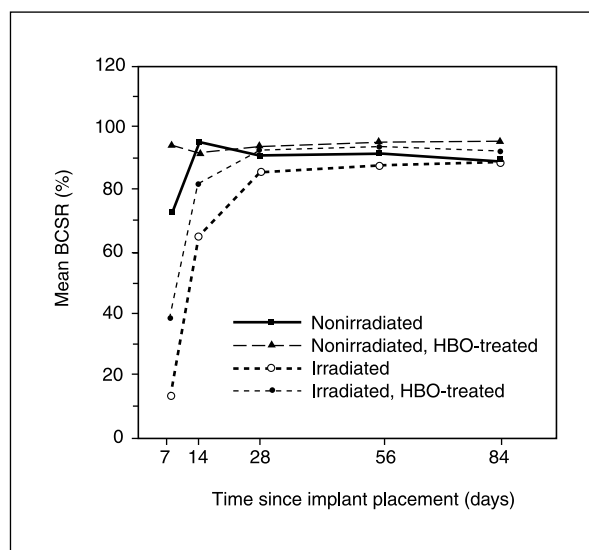
**Table 1** Raw Data of the Percentages of Trabecular Bone–Specific Volume (tVsp) of Each Group at Each Time Point Examined

Sample group examined	7 days	14 days	28 days	56 days	84 days
Nonirradiated, no HBO treatment	53.17	48.23	20.85	19.18	13.48
Irradiated, no HBO treatment	19.79	25.15	17.62	15.47	9.23
Nonirradiated, HBO-treated	28.02	21.82	17.15	13.08	8.75
Irradiated, HBO-treated	32.18	39.48	28.46	21.14	11.23
	27.46	42.02	20.58	11.91	8.25

Two rats were examined at each time point.



**Fig 10** Mean tVsp at each time point for the 4 groups. The HBO treatment lowered the average tVsp in the nonirradiated group and raised it in the irradiated group.



**Fig 11** Mean % BCSR at each time point for the 4 groups. The rate of % BCSR was highest in the nonirradiated, HBO-treated group and lowest in the irradiated, non-HBO-treated group.

**Table 2** Raw Data of the Bone-Contacting Implant Surface Ratio (% BCSR) of Each Group at Each Time Point Examined

Sample group examined	7 days	14 days	28 days	56 days	84 days
Nonirradiated, no HBO treatment	74.14	95.27	93.17	92.87	91.12
Irradiated, no HBO treatment	9.86	63.86	83.46	85.15	89.05
Nonirradiated, HBO-treated	71.10	94.23	91.33	91.17	89.88
Irradiated, HBO-treated	17.80	67.50	88.32	91.95	91.29
	95.41	94.17	95.82	95.18	94.85
	93.69	90.31	92.20	96.66	97.73
	46.18	86.75	91.18	92.15	91.28
	30.64	76.59	94.82	96.41	96.12

Two rats were examined at each time point.

The 2 published experimental studies concerning the effects of HBO therapy on the osseointegration of implants placed in irradiated bone<sup>10,11</sup> revealed that HBO significantly improved the amount of histologic osseointegration. However, changes in the trabecular bone adjacent to the implant and healing around the implant placed in irradiated bone were not investigated. When an implant stimulates an osteoconductive and osteophilic response, a trabecular bone network is formed around the implant surface. The adjacent trabecular bone remodels to a thinner and reduced trabecular bone volume to maintain a steady trabecular bone mass as a compensatory mechanism.<sup>19</sup> The tVsp changed similarly in all groups in this study, although the volume and period of the peak were different among the groups. With HBO therapy, trabecular bone volume decreased in the nonirradiated group.

It has been reported that, following HBO treatment, morphologic changes of increased staining for alkaline phosphatase, acid phosphatase, succinyl dehydrogenase, and NADH2-diaphorase were observed in trabecular bone, whereas staining for lactate dehydrogenase was decreased.<sup>20</sup> These findings are thought to be the result of increased tissue turnover. In the nonirradiated bone of the present study, HBO therapy encouraged the bone adjacent to the implant to remodel faster. On the other hand, the tVsp in the irradiated groups was greater at each examined time point following HBO therapy, implying that the mechanism of the effect of HBO therapy on tVsp differed between bone with and without irradiation.

The differentiation of osteoblasts from mesenchymal cells may be influenced by HBO. Shaw and Bassett<sup>21</sup> have shown that increased oxygen tension caused cellular differentiation in osseous tissue. In irradiated bone, HBO therapy seems to mainly improve the cell population for bone regeneration capacity and then encourage the bone around the implant to remodel at a level close to that of nonirradiated bone.

It was recently reported that HBO therapy decreased implant loss only in the maxilla.<sup>4</sup> The partial increase of tVsp might have contributed to this result. Moreover, the tVsp in the present nonirradiated, HBO-treated group decreased with HBO therapy. It is probable that if less trabecular bone is present around an implant, less force can be absorbed by areas of cancellous bone. In the clinical situation, implants for a patient who has received radiotherapy can also be placed in the nonirradiated area. The results of the present study indicate that implants for patients who receive

HBO therapy should be placed in both irradiated and nonirradiated areas, so the cortical bone area bears an increased amount of force.

The present finding, that most implant surfaces in the HBO-treated animals were directly covered with newly formed bone at an early period, demonstrates that HBO significantly improved the amount of histologic osseointegration. However, in the irradiated groups, HA-bone contact was still delayed, even following HBO therapy, in comparison with the nonirradiated, non-HBO-treated group. Hyperbaric oxygen therapy could shorten, to some degree, the interval between the first and second implant operations. The result, that almost all of the implant surfaces in each group were eventually covered with bone, supports the contention of Larsen<sup>9</sup> that increasing the integration time may improve integration initially; however, when a longer healing period is needed, the modality has less clinical value, because the risks of fibrous encapsulation of the implants and dehiscence of the covered soft tissue increase.

Further studies are needed to determine the optimal radiation fractionation scheme with respect to bone healing, with and without HBO treatment. A single dose of radiation has only one prolonged cellular recovery period after an initial prolonged high-dose damage period. Radiation courses of different fractions in animals will also be influenced by repeated anesthesia. The most suitable HBO protocol for implants placed in irradiated bone must also be determined.

## Conclusions

Although no statistical analysis could be performed because of the limited number of animals, the results of the present study indicated that HBO partially improved trabecular bone formation in irradiated bone, accelerated bone remodeling in nonirradiated bone, and improved HA-bone contact in both irradiated and nonirradiated bone.

## Acknowledgments

This work was supported by a grant from the Ministry of Education, Science and Culture, Japan (c)08672330.

## References

1. Watzinger F, Ewers R, Henninger A, Sudasch G, Babka A, Woelfl G. Endosteal implants in the irradiated lower jaw. *J Craniomaxillofac Surg* 1996;24:237-244.
2. Parel SM, Tjellström A. The United States and Swedish experience with osseointegration and facial prostheses. *Int J Oral Maxillofac Implants* 1991;6:75-79.

3. Granström G, Bergström K, Tjellström A, Brånemark P-I. A detailed analysis of titanium implants lost in irradiated tissues. *Int J Oral Maxillofac Implants* 1994;653-662.
4. Niimi A, Fujimoto T, Nosaka Y, Ueda M. A Japanese multicenter study of osseointegrated implants placed in irradiated tissues: A preliminary report. *Int J Oral Maxillofac Implants* 1997;12:259-264.
5. Mainous EG. Osteogenesis enhancement utilizing hyperbaric oxygen therapy. *HBO Rev* 1982;3:181-185.
6. Marx RE. Osteoradionecrosis: A new concept of its pathophysiology. *J Oral Maxillofac Surg* 1983;48:283-287.
7. Marx RE, Ames JR. The use of hyperbaric oxygen therapy in bony reconstruction of irradiated and tissue deficient patient. *J Oral Maxillofac Surg* 1982;40:412-420.
8. Marx RE, Johnson RP, Kline SM. Prevention of osteoradionecrosis: A randomized prospective clinical trial of hyperbaric oxygen versus penicillin. *J Am Dent Assoc* 1985;111:49-54.
9. Larsen PE, Stronczek MJ, Beck FM, Rohrer M. Osseointegration of implants in radiated bone with and without adjunctive hyperbaric oxygen. *J Oral Maxillofac Surg* 1993;51:280-287.
10. Johnsson K, Hansson A, Granström G, Jacobsson M, Turesson I. The effects of hyperbaric oxygenation on bone-titanium implant interface strength with and without preceding irradiation. *Int J Oral Maxillofac Implants* 1993;8:415-419.
11. Wolfaardt JF, Wilkes GH, Parel SM, Tjellström A. Craniofacial osseointegration: The Canadian experience. *Int J Oral Maxillofac Implants* 1993;8:197-204.
12. Ueda M, Kaneda T, Takahashi H. Effect of hyperbaric oxygen therapy on osseointegration of titanium implants in irradiated bone: A preliminary report. *Int J Oral Maxillofac Implants* 1993;8:41-44.
13. Franzen L, Rosenquist JB, Rosenquist KI, Gustafsson I. Oral implant rehabilitation of patients with oral malignancies treated with radiotherapy and surgery without adjunctive hyperbaric oxygen. *Int J Oral Maxillofac Implants* 1995;10:183-187.
14. Matsui Y, Ohno K, Michi KI, Tachikawa T. Histomorphometric examination of healing around hydroxylapatite implants in 60Co-irradiated bone. *J Oral Maxillofac Surg* 1994;52:167-172.
15. Jacobsson M, Tjellström A, Albrektsson T, Turesson IE. Short- and long-term effects of irradiation on bone regeneration. *Plast Reconstr Surg* 1985;76:841-850.
16. Clokie CML, Warshawsky H. Development of a rat tibia model for morphological studies of the interface between bone and titanium implants. *Compendium* 1995;16:56-68.
17. Block MS, Kent JN, Kay JF. Evaluation of hydroxylapatite-coated titanium dental implants in dogs. *J Oral Maxillofac Surg* 1987;45:601-607.
18. Nemiroff PM, Rybak LP. Applications of hyperbaric oxygen for the otolaryngologist-head and neck surgeon. *Am J Otolaryngol* 1988;9:52-57.
19. Styfstad GT, Urist MR. Bone aging. *Clin Orthop Rel Res* 1982;162:288-297.
20. Granström G, Nilsson LP, Rockert HOE, Magnusson BC. Experimental mandibular fracture. Effect on bone healing after treatment with hyperbaric oxygen. In: Bitterman N, Lincoln R (eds). *Proceedings of the 25th European Underwater and Baromedical Society scientific meeting, Eilat, Israel, 1989b*:290-297.
21. Shaw JL, Bassett CA. Effects of varying oxygen concentrations on osteogenesis and embryonic cartilage in vitro. *J Bone Joint Surg [Am]* 1967;49:73-80.