

---

# Assessment of the Blood Supply to the Mental Region for Reduction of Bleeding Complications During Implant Surgery in the Interforaminal Region

Ursula Hofschneider, MD\*/Gabor Tepper, MD\*/André Gahleitner, MD\*/  
Christian Ulm, MD\*\*

Several life-threatening complications caused by hemorrhage that can occur during the placement of dental implants in the mandibular interforaminal region have been described in the literature. The aim of this study was to assess the vascular supply to this region and delineate the relative contribution and importance of the sublingual artery versus the submental artery. Thirty-four human cadavers were dissected. Special attention was directed to the presence of a branch of the submental artery that perforates the mylohyoid muscle and thus participates in the blood supply to the floor of the mouth together with the sublingual artery. A sublingual artery was found in 71% of the specimens. A large branch of the submental artery perforating the mylohyoid muscle was found in 41% of the specimens. The point of perforation was located an average of 31 mm posterior to the menton. The high risk of injuring the vessels of the floor of the mouth can be explained by the close vicinity of these vessels to the mandibular lingual cortical plate. To prevent complications in cases of unclear anatomic identification of the fossa sublingualis, preoperative lingual probing or elevation of the periosteum of the lingual aspect of the mandible is necessary. An alternative diagnostic procedure is precise preoperative noninvasive imaging (eg, computed tomography).

(INT J ORAL MAXILLOFAC IMPLANTS 1999;14:379-383)

**Key words:** endosseous implants, floor of the mouth, hemorrhage, vessels

---

The literature contains several reports on often seemingly small, irrelevant injuries that occurred during host site preparation for implant placement in the mandibular interforaminal region and caused hemorrhage of the floor of the mouth, which can result in a life-threatening obstruction of the upper respiratory tract. Ratschew et al<sup>1</sup> reported on an 80-year-old female patient who was treated with 4 cylindrical implants in the mandibular premolar and canine regions, respectively. When the host sites were prepared, the mandibular lingual compact bone in the mandibu-

lar left canine region was slightly perforated during the pilot hole drilling, so that the drill slipped caudally by no more than 3 to 4 mm. This seemed to have no major consequences, and the preparation was continued after the drill had been moved further labiocaudally. However, during the second drilling procedure, a hematoma was found in the region of the right sublingual sulcus; it expanded and resulted in severe swelling of the floor of the mouth superiorly after completion of the operation. This resulted in mechanical obstruction of the upper respiratory tract. Because of the resultant respiratory distress, the patient required intubation and hemorrhage control by means of tamponades and compression. Following successful extubation, after 3 days, the patient was transferred from the intensive care unit to a normal inpatient ward and was discharged from the hospital after another 8 days. Similar cases have been described by others.<sup>2-7</sup> Many of these reports have indicated a latency period of several hours until the occurrence of hemorrhage.

---

\*School of Dental Medicine, University of Vienna, Vienna, Austria.

\*\*Professor, Department of Radiology and MRI, School of Dental Medicine, University of Vienna, Vienna, Austria.

**Reprint requests:** Dr Ursula Hofschneider, School of Dental Medicine, Währingerstrasse 25, 1090 Vienna, Austria. Fax: +43-1-40635204.

Perforation of mandibular lingual compact bone and resultant injury of a vessel of the floor of the mouth have been assumed to be the cause of this complication. Similar complications have also been observed during other dental procedures. Among the causes have been lingual local anesthesia, injuries caused by drilling, removal of a ranula, biopsies, and even tooth extractions.

### Materials and Methods

Seventeen mandibles and associated structures of human cadavers, which had been supplied by the Institute of Anatomy of the University of Vienna, were examined in this study. Eleven of the specimens were female and 6 were male. The age of the subjects, most of whom were Central Europeans, ranged between 59 and 102 years, the mean being 80.81 years. The specimens' vessels had been filled with phenol and stored in a fixation medium (4% formalin and 10% phenol dissolved in water) for several months.

A total of 34 bilateral extraoral dissections of the submental and submandibular triangles were made. The submental artery was traced in the submandibular triangle to discern a possible branch perforating the mylohyoid muscle. The presence of a perforating branch indicated that it played a role in supplying blood to the floor of the mouth. Therefore, the diameters of both the perforating branch and the submental artery, in a portion before the point of origin of the perforating branch, were measured using a millimeter ruler. Furthermore, the distance between the site of perforation through the mylohyoid muscle and the menton was measured in mm. The latter orthodontic reference point was chosen because it is near the surgical site, easily palpable, and constitutes the deepest point of the mandibular symphysis. Furthermore, the diameter of the facial artery was measured in mm to obtain a reference value for orientation. To assess the sublingual artery, all 17 original bilateral specimens were bisected by means of a mediansagittal section. As a result, 34 skull halves were available for dissection of the floor of the mouth.

The sublingual artery was evaluated in its full length, its course, and its relationship with topographically adjacent structures; its branches were documented and its diameter was assessed using the method described above. When both a perforating branch and a sublingual artery were found, the course of the latter was checked for a possible anastomosis between these 2 vessels.

### Results

**Parameters of the Sublingual Artery.** Twenty-four (70%) of the 34 dissected specimens showed a sublingual artery in the region of the floor of the mouth. The sublingual artery originated from the lingual artery at the anterior border of the hyoglossus muscle. The diameter of the 24 sublingual arteries examined ranged between 1.5 and 2.5 mm. The mean value was 2.04 mm.

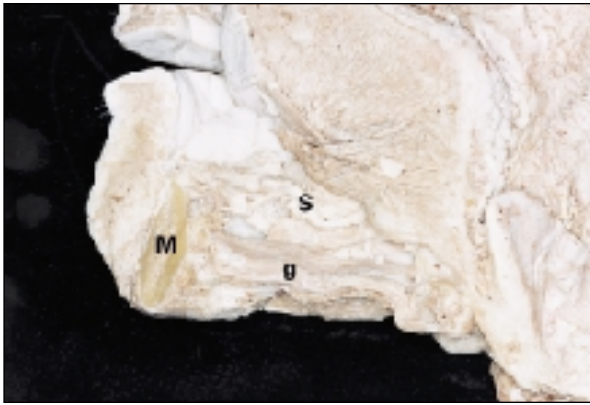
*Course of the Sublingual Arteries.* Because of the different courses of the sublingual arteries, the following 4 groups were established:

- Group I: The main branch of the sublingual artery divides into a medial and a lateral branch. Each of these branches enters the body of the mandible via a foramen. Three specimens (8.8%) had this configuration.
- Group II: The sublingual artery divides into an ascending and a descending branch. This division occurs about halfway between the cranial and the caudal borders of the sublingual gland. Fifteen specimens (44.1%) were of this type. These end-arteries also entered the body of the mandible via foramina (interalveolar, lateral, supraspinal, interspinal, and subspinal foramina).
- Group III: The sublingual artery divides into a cranial branch, which has the largest diameter; a middle branch; and a caudal branch. Four specimens (11.8%) belonged to this group.
- Group IV: Group IV consisted of 1 specimen, which constituted a special case because the sublingual artery originated from the facial artery. The sublingual artery first coursed on the surface and then perforated the geniohyoid muscle, entering the floor of the mouth latero-caudally to the body of the hyoid bone.

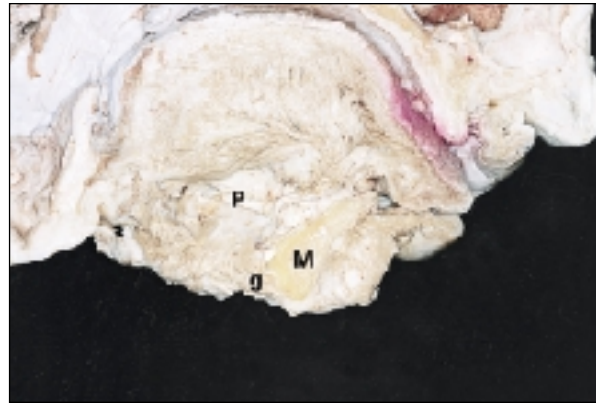
**Parameters of the Perforating Branch.** A perforating branch was found in 14 of 34 dissected specimens (41.2%). This artery branched off the submental artery in the submandibular region and perforated through the mylohyoid muscle at a variable distance from the menton. The diameter of the perforating branches ranged between 1 and 3 mm. The mean value was 2.11 mm.

The distance between the perforating branches and the menton perforation ranged between 2.4 and 47 mm. The mean value was 30.58 mm.

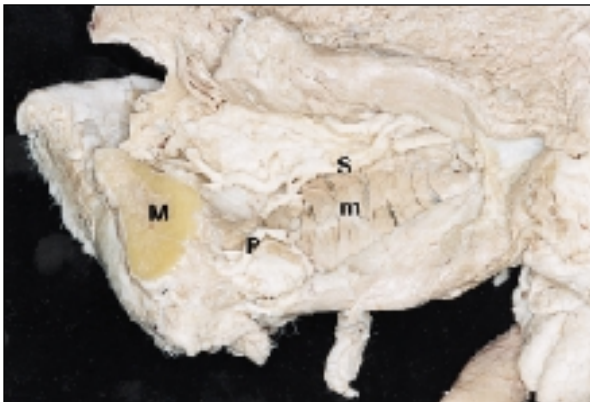**Establishment of 3 Classes.** In view of the goal of this study, a classification of the aforementioned resulted in 3 classes, based on the dominating type of vessel:



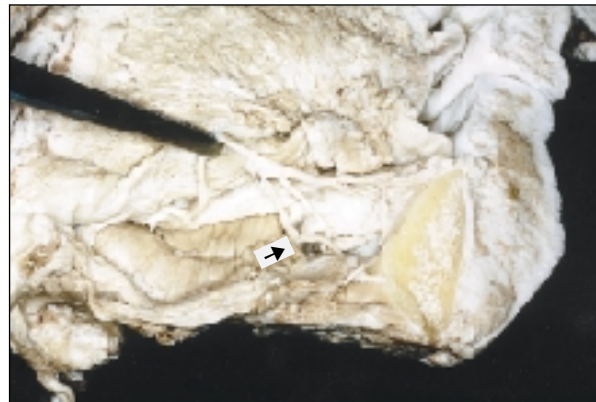
**Fig 1** Example of a class I situation (sublingual artery with no perforating branch). M = mandible; S = sublingual artery; g = geniohyoid muscle.



**Fig 2** Example of a class II situation (perforating branch; no sublingual artery). M = mandible; P = perforating branch; g = geniohyoid muscle.



**Fig 3** Example of a class III situation (presence of sublingual artery and a perforating branch). M = mandible; S = sublingual artery; m = mylohyoid muscle; P = perforating branch.



**Fig 4** Anastomosis of sublingual artery and the perforating branch (*arrow*).

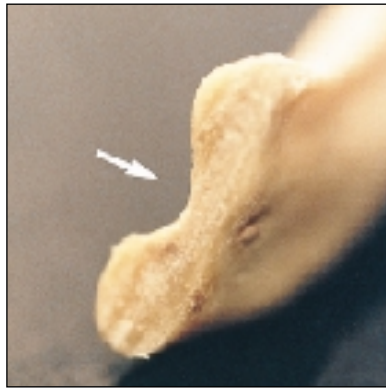- Class I is characterized by the presence of a sublingual artery that has no perforating branch (Fig 1). This class was found in 20 of 34 (58.8%) dissected specimens.
- Class II is characterized by the presence of a perforating branch and an absence of the sublingual artery (Fig 2). This class was found in 10 (29.4%) specimens. A notable finding was that 2 of these specimens displayed 2 perforating branches simultaneously.
- Class III is characterized by the presence of both a sublingual artery and a perforating branch (Fig 3), which anastomose in some cases (Fig 4). This group comprised 4 specimens (11.8%).

**Sex Differences.** Twenty-two female and 12 male specimens were examined and compared with each other. Fourteen of 22 female specimens

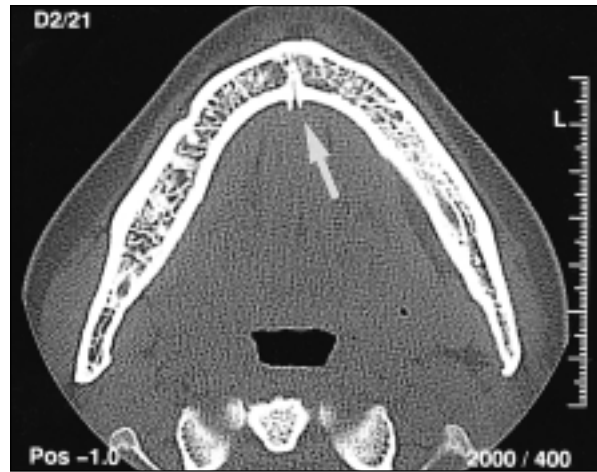
(63.6%) belonged to Class I, 5 specimens (22.7%) belonged to Class II, and 3 specimens (13.6%) belonged to Class III. Six of 12 male specimens (50.0%) belonged to Class I, 5 specimens (41.7%) belonged to Class II, and 1 specimen (8.3%) belonged to Class III. Both specimens that displayed 2 perforating branches stemmed from male skulls.

**Symmetry.** To assess a possible symmetry of the vessels supplying the floor of the mouth, the sides of the 34 specimens were compared with each other. The blood supply was generally consistent on both sides, ie, both sides were assigned to the same class in 12 of the 17 bilateral specimens (70.6%).

**Age.** The age of the specimens examined in this study ranged from 59 to 102 years. No correlation was found between the age of the specimens and the type of blood supply.



**Fig 5** Anatomic view of the sublingual fossa of the mandible (*arrow*).



**Fig 6** Bone channel (*arrow*) in the interforaminal region (transverse dental CT scan of the mandible, 1.5-mm slice thickness, high resolution bone window).

## Discussion

The findings of this study clearly indicate that there is a potential risk of complications resulting from injuries of the floor of the mouth during implant placement. The interforaminal region in particular involves a high risk of injuries, since the majority of vascular branches enter the mandibular bone in this region. The vessels are very intertwined and course closely to the sublingual gland and the sublingual fossa. The results of this study also indicate that the injured vessels are most likely branches of the sublingual artery and not of the submental artery. However, in many specimens, the submental artery gave off a branch that perforated through the mylohyoid muscle and supplied the region of the floor of the mouth, either alone or in combination with the sublingual artery.

Previous studies<sup>8-11</sup> have focused on examining the arterial supply to the mandibular bone, rather than on documenting the course and importance of these vessels. Some anatomic studies have indicated greater involvement of the submental artery in the blood supply to the floor of the mouth.<sup>12,13</sup> Bavitz et al<sup>14</sup> were the first to investigate the relative contribution and importance of the sublingual artery versus the submental artery. Their findings suggested that the submental artery is the main arterial blood supply to the floor of the mouth. However, they did not report any cases with both a sublingual artery and a perforating branch.

The latency period until the formation of a hematoma that has been observed in some hemorrhages can be explained by the interaction of several factors. For example, hemorrhages from cleanly severed vessels can stop by themselves as a result of initial contraction, intinospasm, and retraction, while these processes rarely occur when the vascular wall is merely torn.<sup>15,16</sup> Another risk factor is the specific anatomic condition of the mandible. For example, a very pronounced sublingual fossa can contribute to a perforation of the lingual compact bone during implant placement, because there is no firm bone left in the apical region, as is normally the case<sup>7,17,18</sup> (Fig 5). To avoid this complication, a careful preoperative and intraoperative approach should be chosen.

Intraoperatively, a careful subperiosteal dissection that preserves the vessels entering the bone should be carried out in cases of unclear identification of the fossa sublingualis, because only this approach allows an adequate view of the local anatomic conditions in this region and the prevention of injuries to vessels at risk. The demonstration of the cranial portion of the alveolar process or the occlusal surface alone or permucous implant placement do not suffice in these anatomic conditions. An alternative would be diagnostic imaging, eg, dental computed tomography (CT) or possibly spiral tomography. Dental CT seems to be particularly suitable, since the high-resolution analysis of the entire body of the mandible provides not only an image of the skeletal conditions, but also of the sites of entrance of the vessels into the lingual mental region<sup>19</sup> (Fig 6).

## Summary

The cause of the problem is evident because of the perforation of the sublingual artery or the perforating branch. The goal of this investigation was to identify these problems and to underline the need for imaging in preventing complications during implantation surgery. Computed tomography seems to be an ideal tool for accurately identifying the fossa sublingualis and evidence of transmandibular vascular branches. Because of the knowledge of preinterventional CT, the misinterpretation of a pronounced fossa sublingualis with the likelihood of vessel perforation can be decreased.

## References

1. Ratschew C, Czernicky W, Watzek G. Lebensbedrohliche Blutung nach Implantation im Unterkiefer. *Dtsch Zahnärztl Z* 1994;49:65-67.
2. Mordenfeld A, Andersson L, Bergström B. Hemorrhage in the floor of the mouth during implant placement in the edentulous mandible: A case report. *Int J Oral Maxillofac Implants* 1997;12:558-561.
3. Ten Bruggenkate CM, Krekeler G, Kraaijenhagen HA, Foitzik C, Oosterbeek HS. Hemorrhage of the floor of the mouth resulting from lingual perforation during implant placement: A clinical report. *Int J Oral Maxillofac Implants* 1993;8:329-334.
4. Laboda G. Life-threatening hemorrhage after placement of an endosseous implant: Report of case. *J Am Dent Assoc* 1990;121:599-600.
5. Mason ME, Tripplet RG, Alfons WF. Life-threatening hemorrhage from placement of a dental implant. *J Oral Maxillofac Surg* 1990;48:201-204.
6. Krenkel CH, Holzner K, Poisel S. Mundbodenhämatome nach oralchirurgischen Eingriffen und ihre anatomischen Besonderheiten. *Dtsch Z Mund Kiefer Gesichtschir* 1985;9:448-451.
7. Krenkel C, Holzner K. Die linguale Knochenperforation als Kausalfaktor einer bedrohlichen Mundbodenblutung bei einem Einzelzahnimplantat der Eckzahnregion. *Die Quintessenz* 1986;6:1003-1008.
8. Kattan B, Snyder H. Lingual artery hematoma resulting in upper airway obstruction. *J Emerg Med* 1991;9:421-424.
9. Staudt J, Breustedt A. Untersuchungen über die arterielle Versorgung des Unterkiefers beim Menschen. *Stomatol DDR* 1978;28:529-537.
10. Ragot B, Poirot G. Contribution à l'étude anatomique de la vascularisation de la région antérieure de la mandibule. *Rev Odonto-Stomatol* 1983;12:49-54.
11. Cadenat H, Barthélémy R. Importance de la vascularisation mandibulaire en chirurgie maxillo-faciale. *Rev Stomatol* 1972;73:60-65.
12. De Brul EL (ed). *Sicher's Oral Anatomy*, ed 7. St. Louis: Mosby, 1980.
13. Williams P, Warwick R, Dyson M, Bannister L (eds). *Gray's Anatomy*, ed 37. Edinburgh: Churchill Livingstone, 1989.
14. Bavitz B, Harn S, Homze E. Arterial supply to the floor of the mouth and lingual gingiva. *Oral Surg Oral Med Oral Pathol* 1994;77:232-235.
15. Staubesand J. Zum Spontanverschluß verletzter Arterien. *Die Medizinische* 1957;45:1663-1666.
16. Imparato A, Riles T. Peripheral arterial diseases. In: Schwartz SI (ed). *Principles of Surgery*, vol 1. New York: McGraw-Hill, 1989.
17. Samson J, Bernard J-P, Hausler B, Fiore-Donno G, Laurent F. Inclusions intramandibulaires de tissu salivaire. *Rev Mens Suisse Odont Stomatol* 1983;12:1138-1156.
18. Becker S, Härle F. Die latente Knochenhöhle, ein Fall seltener Lokalisation. *Dtsch Z Mund Kiefer Gesichtschir* 1986;10:60-61.
19. Williams MYA. The role of computerized tomography in dental implantology. *Int J Oral Maxillofac Implants* 1992;7:373-380.