
SHORT COMMUNICATION

Allergy and infections: Long-term improvement of vernal keratoconjunctivitis following viral conjunctivitis

R. SGRULLETTA^{1,2}, S. BONINI^{1,2}, A. LAMBIASE^{1,2}, S. BONINI³

¹Interdisciplinary Center for Biomedical Research (CIR), Laboratory of Ophthalmology, University of Roma "Campus Bio-Medico"

²G.B. Bietti Eye Foundation, IRCCS

³Internal Medicine, Second University of Napoli and Institute of Neurobiology and Molecular Medicine, Italian National Research Council, Roma - Italy

PURPOSE. *Vernal keratoconjunctivitis (VKC) is a severe, chronic allergic inflammatory disease of the ocular surface poorly responsive to antiallergic treatments and possibly leading to permanent visual impairment. VKC, because of mast cell, eosinophil, and Th2-type inflammation, polyclonal IgE activation, and tissue remodeling, is considered to be a typical Th2-driven disease. Viral infection stimulates a Th1 type immune response, potentially attenuating allergen-induced inflammation. The purpose of this report is to describe the effect of viral keratoconjunctivitis in a patient with VKC.*

METHODS. *The authors report on a patient with a severe form of VKC, poorly responsive to antiallergic treatments, who developed a viral keratoconjunctivitis. Signs, symptoms, and cytologic findings were recorded during the 5-year follow-up period.*

RESULTS. *The authors observed a prompt and permanent improvement of signs and symptoms of the allergic condition after the viral infection. Conjunctival scraping confirms that the inhibition of the eosinophilic inflammation lasts at least for 5 years.*

CONCLUSIONS. *In this case, the viral infection seemed to induce a clinical recovery of allergic disease, suggesting that an immune deviation induced by Th1-polarizing agents may revert an ongoing Th2 inflammation. (Eur J Ophthalmol 2006; 16: 470-2)*

KEY WORDS. *Allergic conjunctivitis, Epidemic keratoconjunctivitis, Th1, Th2, Vernal keratoconjunctivitis, Viral infection*

Accepted: December 3, 2005

INTRODUCTION

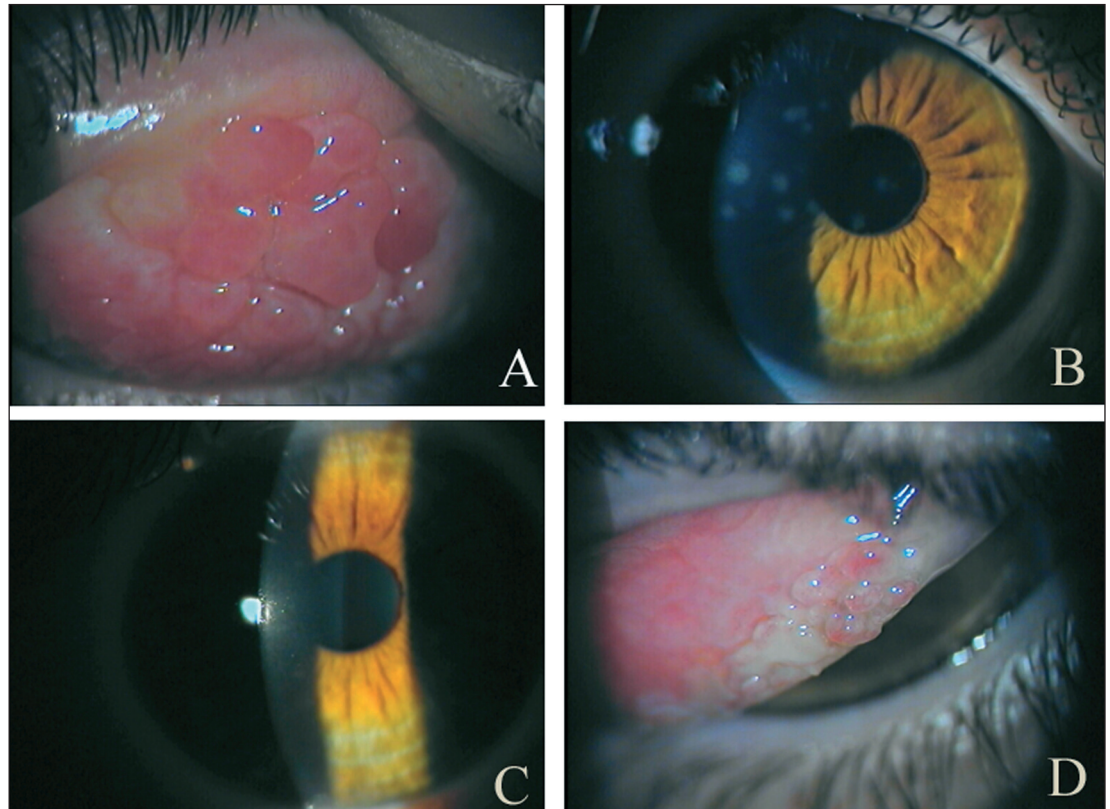
Vernal keratoconjunctivitis (VKC) is a chronic allergic inflammatory disease of the ocular surface affecting young boys in their first decade of life (1). The disease is characterized by typical clinical signs and symptoms, including itching, photophobia, mucous discharge, giant papillae on the upper tarsal conjunctiva or at the limbus, superficial keratopathy, and corneal shield ulcers. In some cases, permanent changes of the corneal transparency may occur, leading to permanent visual impairment (1).

In the present report, we describe the clinical improvement of a severe and chronic form of VKC which occurred after a superinfection of epidemic viral keratoconjunctivitis.

Case report

In October 1998, a 9-year-old boy was referred to our clinic for symptoms of intense ocular itching and photophobia, persisting for 2 years and worsening during spring. Personal history for allergic diseases was negative. Skin tests showed a weak positivity for rye-grass al-

Fig. 1 - The patient with vernal keratoconjunctivitis (VKC) for 2 years shows giant papillae on the upper tarsal conjunctiva (A). The patient had viral keratoconjunctivitis with subepithelial corneal infiltrates (B). Six weeks after the viral infection, the cornea cleared (C). After 3 years of follow-up the patient had no symptoms of VKC and showed a decrease in the size of the giant papillae associated with a mild subepithelial fibrosis (D).



lergen. Biomicroscopic examination showed the presence of giant papillae on the upper tarsal conjunctiva (Fig. 1A) associated with a sticky mucous discharge, conjunctival hyperemia, and chemosis. Conjunctival scrapings revealed the presence of numerous eosinophils. A diagnosis of VKC was made and treatment was started with topical anti-allergic drugs. In spite of a moderate relief of symptoms, recurrent exacerbations of ocular inflammation occurred during 1999, requiring brief courses of topical steroids.

In April 2000, the patient presented again because of what he believed to be a recurrence of VKC. Itching was less intense while predominant symptoms were a severe stinging and burning of the eyes. Ocular examination showed an acute, bilateral, follicular conjunctivitis with lymphocyte accumulation (no eosinophils), microhemorrhages, tarsal pseudomembranes, and diffuse subepithelial corneal infiltrates associated with a preauricular lymphadenopathy (Fig. 1B). A clinical diagnosis of epidemic keratoconjunctivitis was made and symptomatic treatment commenced (2). After 2 weeks, we observed a complete recovery from the signs and symptoms of the viral infection. However, subepithelial infiltrates of the cornea

persisted for 6 weeks before complete recovery (Fig. 1C).

During the following 5 years, the patient had no symptoms of VKC and clinical examination did not reveal any sign of allergic inflammation such as eosinophils in conjunctival scrapings, suggesting a complete recovery of VKC. A progressive decrease in the size of giant papillae as well as a mild subepithelial fibrosis were observed over the 5-year follow-up period (Fig. 1D).

DISCUSSION

Relationships between allergies and infections represent an interesting issue of theoretical and clinical relevance (3). We report a case of viral overinfection in VKC which was associated with a prompt and persistent recovery from a severe and longstanding allergic inflammation.

Overinfections of viral origin do not generally occur during VKC and are not reported in large clinical series of patients with this allergic disease (1).

In our patient, the diagnosis of viral keratoconjunctivitis was made on the basis of clinical criteria. Even if we did not perform any laboratory test to prove viral infections, we

observed the presence of lymphocytic follicular infiltrates, microhemorrhages, tarsal pseudomembranes, and preauricular lymphadenopathy, which are considered as pathognomonic of viral infection of the ocular surface (4, 5).

Although it is difficult to state a causal relationship between the occurred viral infection conjunctivitis and the recovery from VKC, our studies and follow-up of a large cohort of patients with VKC indicate that spontaneous resolution of VKC generally occurs after puberty, with slow and progressive remission of signs and symptoms over years (1). In contrast, in our patient recovery was abrupt, complete, and longstanding.

The pathogenesis of VKC as well as other atopic diseases is attributed to a T-helper 2 (Th2) cytokine profile (IL-4, IL-5, IL-6, IL-9, IL-10, and IL-13) associated with IgE hyperproduction, activation of mast cells, and accumulation of eosinophils, neutrophils, and their toxic products (6, 7).

Several studies indicate that viral proteins stimulate a Th1 type immune response, leading to an increase in IFN γ , which in turn attenuates experimental allergen-induced inflammation (8-11). Contrasting data by Stern et al suggest that inhibition of IFN- γ induces a decrease in the number of eosinophils infiltrating the conjunctiva in an animal model of allergy. Indeed, the same author demonstrated that anti-IFN- γ antibody administration during the

induction phase of the immune response exacerbated allergic conjunctivitis (12). In agreement with this experimental and clinical evidence it appears sound to suggest that the immediate and persistent improvement of VKC observed in our patient was due to inhibition of the ongoing Th2 immune response induced by the Th1 response induced by the viral infection.

Should the hypothesis that an immune deviation induced by Th1-polarizing agents may revert an ongoing Th2 inflammation be correct, new interventional approaches for the treatment of this sight-threatening disease should emerge. In fact, several agents such as microbial products, cytokines, and hormones have been proposed as modulators of the Th2/Th1 balance, indicating a novel strategy for the prevention and therapy of allergic diseases in general and of ocular allergy in particular (13).

The authors have no conflict of interest.

Reprint requests to:
Prof. Stefano Bonini
Interdisciplinary Center for Biomedical Research (CIR)
Laboratory of Ophthalmology
University of Roma "Campus Bio-Medico"
Via Emilio Longoni 83
00155 Roma, Italy
s.bonini@unicampus.it

REFERENCES

1. Bonini S, Bonini S, Lambiase A, et al. Vernal keratoconjunctivitis revisited: a case series of 195 patients with long-term follow up. *Ophthalmology* 2000; 107: 1157-63.
2. Kaufman HE. Treatment of viral diseases of the cornea and external eye. *Prog Retin Eye Res* 2000; 19: 69-85.
3. Marsland BJ, Kopf M, Le Gros G. Viral infection and allergy. *Nat Immunol* 2004; 5: 865-6.
4. American Academy of Ophthalmology. Infectious diseases of external eye: clinical aspects. In: *Basic and Clinical Science Course 2002-3. External Disease and Cornea*. Ch. 7. San Francisco, CA: American Academy of Ophthalmology, 2003; 130-4.
5. Kanski JJ. *Clinical Ophthalmology: A Systematic Approach*. 5th ed. Ch. 4. Boston: Butterworth Heinemann; 2003: 68-9.
6. Maggi E, Biswas P, Del Prete G, et al. Accumulation of Th2-like helper T cells in the conjunctiva of patients with vernal conjunctivitis. *J Immunol* 1991; 146: 1169-74.
7. Bonini Se, Bonini St, Lambiase A, et al. Vernal keratoconjunctivitis: a model of 5q cytokine gene cluster disease. *Int Arch Allergy Immunol* 1995; 107: 95-8.
8. Behera AK, Kumar M, Lockey RF, Mohapatra SS. Adenovirus-mediated interferon gamma gene therapy for allergic asthma: involvement of interleukin 12 and STAT4 signaling. *Hum Gene Ther* 2002; 13: 1697-709.
9. Molinier-Frenkel V, Lengagne R, Gaden F, et al. Adenovirus hexon protein is a potent adjuvant for activation cellular immune response. *J Virol* 2002; 76: 127-35.
10. Magone MT, Whitcup SM, Fukushima A, et al. The role of IL-12 in the induction of the late-phase cellular infiltration in a murine model of allergic conjunctivitis. *J Allergy Clin Immunol* 2000; 105: 299-308.
11. Fukushima A, Fukata K, Ozaki A, et al. Exertion of the suppressive effects of IFN- γ on experimental immune mediated blepharoconjunctivitis in Brown Norway rats during the induction phase but not the effector phase. *Br J Ophthalmol* 2002; 86: 1166-71.
12. Stern M, Siemasko K, Gao J, et al. Role of interferon- γ in a mouse model of allergic conjunctivitis. *Invest Ophthalmol Vis Sci* 2005; 46: 3239-46.
13. Matricardi PM, Bonini S. Mimicking microbial "education" of the immune system: a strategy to revert the epidemic trend of atopy and allergic asthma? *Respir Res* 2000; 1: 129-32.