

# Basic research conducted on alloplant biomaterials

E.R. MULDASHEV, S.A. MUSLIMOV, R.T. NIGMATULLIN, Y.I. KIIKO, V.U. GALIMOVA,  
A.Y. SALIKHOV, N.E. SELSKY, R.T. BULATOV, L.A. MUSINA

Russian Eye and Plastic Surgery Center, Ufa - Russia

**ABSTRACT:** Purpose. To reduce antigenicity of allografts and stimulate their replacement by natural recipient tissues.

Methods. Experimental allotransplantation of different tissues (fascias, tendons, derma, fat, etc.) with histological, histochemical, electron microscopical, electron histochemical examination 3, 5, 7, 14, 21, 30, 60, 120, 180 and 360 days postoperatively.

Results. Allografts of different tissues with glucosaminoglycans extracted from collagen fibers have low antigenicity and can be replaced by natural tissues. Allografts with these properties were named 'Alloplant'.

Conclusions. Alloplant biomaterials can selectively stimulate natural tissue regeneration. Hence, Alloplant biomaterials can be utilized in surgery for the restoration of different tissues. (*Eur J Ophthalmol* 1999; 9: 8-13)

**KEY WORDS:** Allografts, Antigenicity, Tissue regeneration, Glucosaminoglycans, Scar

Accepted: September 30, 1998

## INTRODUCTION

The use of different grafts for repair of the eyeball, eyelid and orbit is a pressing problem. Yet, artificial grafts (silicone etc.) are known to cause complications, such as chronic inflammation, scarring around the implants, and possible rejection (1). Autografting implies additional surgical trauma to the patient. Xenotransplantation of tissues is associated with a subsequent immunologic incompatibility of tissues and rejection (2). Allografting in ophthalmology is limited to transplantation of the cornea and sclera (TBI, annual report, 1992), since other tissues usually induce severe immune reaction or rejection (3), resorption of the transplant (4) or scarring after grafting (5, 6).

Our preliminary studies of tissue allotransplantation revealed that the allogenicity of allografts depends on the peculiarities of tissue (structure, histochemical content, etc.). Allografts can also stimulate recipient tissue regeneration during the resorption of transplanted tissue (7). We discovered that allografts are in most cases replaced by natural recipient tissues, but scarring sometimes takes place.

Thus, basic theoretical research on the antigenicity decrease of allografts and stimulation of natural


recipient tissue regeneration is of great interest. A solution to these problems could provide new opportunities in terms of regeneration in ophthalmosurgery and in other fields of surgery.

It was the purpose of the investigation to reduce the antigenicity of allografts and stimulate their replacement by natural recipient tissues.

## METHODS

The materials of the study included different tissues (fascia, tendon, derma, fat, conjunctiva, tarsus, sclera) of 56 human cadavers (aged 13 to 45 years) designed for allografting. Experimental allotransplantation was also used (rabbits - 84, rats - 36), studied 3, 5, 7, 14, 21, 30, 60, 120, 180, 270 and 360 days postoperatively.

The methods of investigation used were: histomorphologic (staining: Van Gieson, Mallory's, hematoxylin and eosin, silver impregnation), light polarization microscopy (8), morphometry using the computer program Bioscan 2 (Kanako, Belarus), histochemical analysis by means of cryotom tissue sections with Alcian blue staining (9, 10), electron and electron his-



**Fig. 1** - Electron histochemical micrograph demonstrating glucosaminoglycan extraction from allografts: **a**) - 7 days after implantation of the native allograft (x 30000), **b**) - After the chemical treatment of allogenic tissue (x 19000).

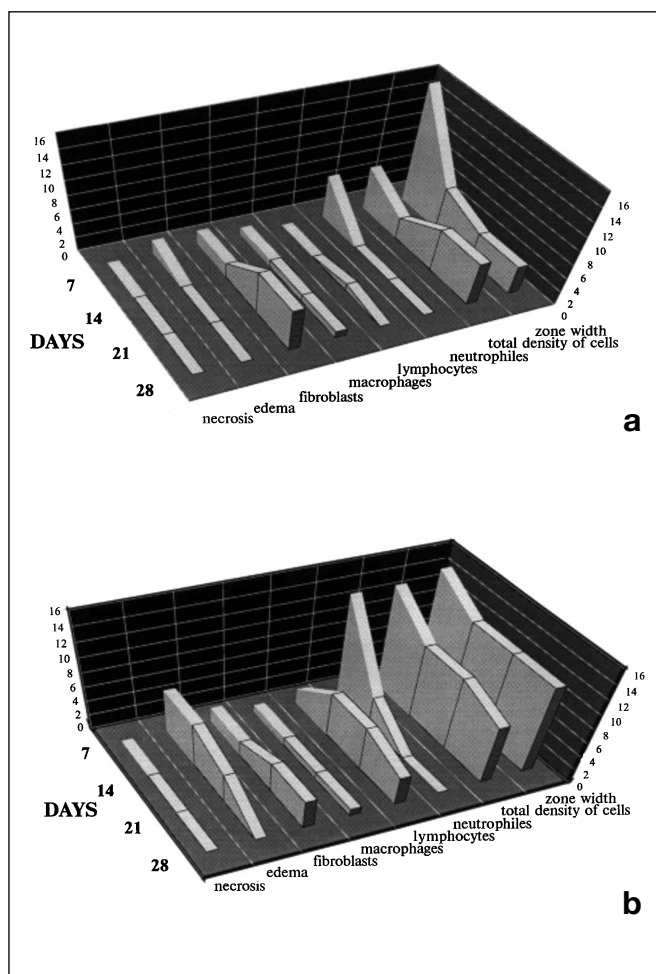
tochemical (11, 12) as well as immunologic methods, namely, passive hemagglutination, indirect leukocyte inhibition test, leukocyte immune phenotyping with monoclonal antibodies (Sigma, USA).

A comparative study of native versus chemically treated allografts (fascia, tendon, derma) was carried out in 24 rabbits and 36 rats. Tissue reaction to allografts was evaluated using the modified Sewell method (13).

The purpose of the scarring process study after tissue allotransplantation was to reveal the dependence of scarring on allograft fibroarchitecture and replaced tissues. Two experimental models were used for this purpose: a) eyelid tarsus repair with a specially selected allograft (plantar derma) and allograft of fascia lata as a control; b) conjunctiva repair with a specially selected allograft (visceral fascia) and allograft of conjunctiva as a control. A total of 30 rabbits were used in each series. The rate of scarring was evaluated using the morphological signs of scarring (14, 15).

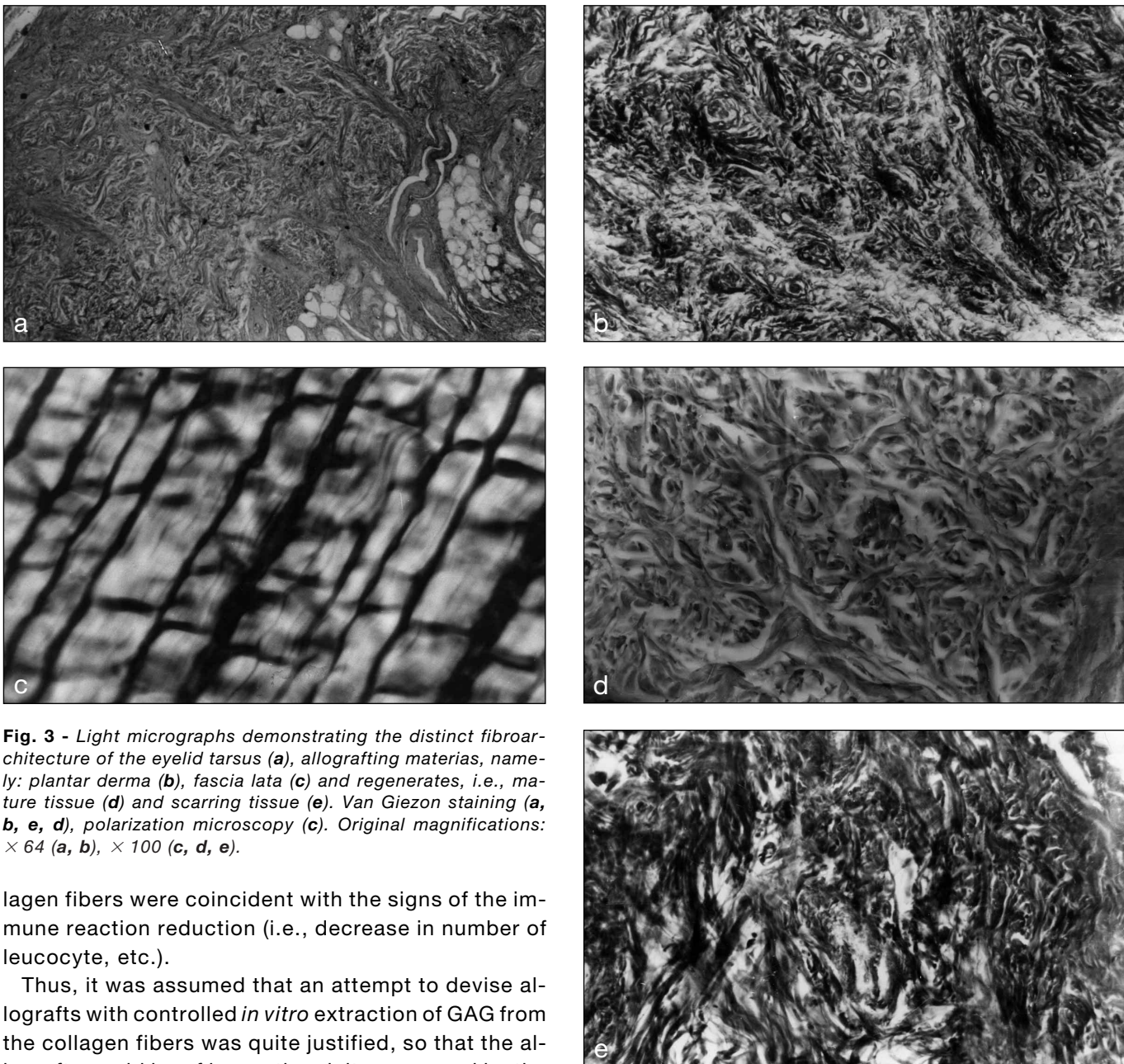
## RESULTS

Histologic studies revealed a severe immune reaction (edema, hyperemia, lymphocytic and neutrophilic infiltration, etc.) around the native allografts at 20 days, and there was a reduction in immune reaction later on. Electron histochemical study showed that the reduction was related to the extraction of glucosaminoglycans (GAG) from the collagen fibers of the allograft (Fig. 1a). The period of GAG extraction (20 days) and the position of GAG between the col-



**Fig. 2** - Tissue reaction (by Sewell) on allografts with controlled GAG extraction (**a**) and native allografts (**b**). Fig. **a** shows the lower edema, lymphocyte infiltration, lower density of immune cells, and width of the response area.





**Fig. 3** - Light micrographs demonstrating the distinct fibroarchitecture of the eyelid tarsus (a), allografting materias, namely: plantar derma (b), fascia lata (c) and regenerates, i.e., mature tissue (d) and scarring tissue (e). Van Gieson staining (a, b, e, d), polarization microscopy (c). Original magnifications:  $\times 64$  (a, b),  $\times 100$  (c, d, e).

lagen fibers were coincident with the signs of the immune reaction reduction (i.e., decrease in number of leucocyte, etc.).

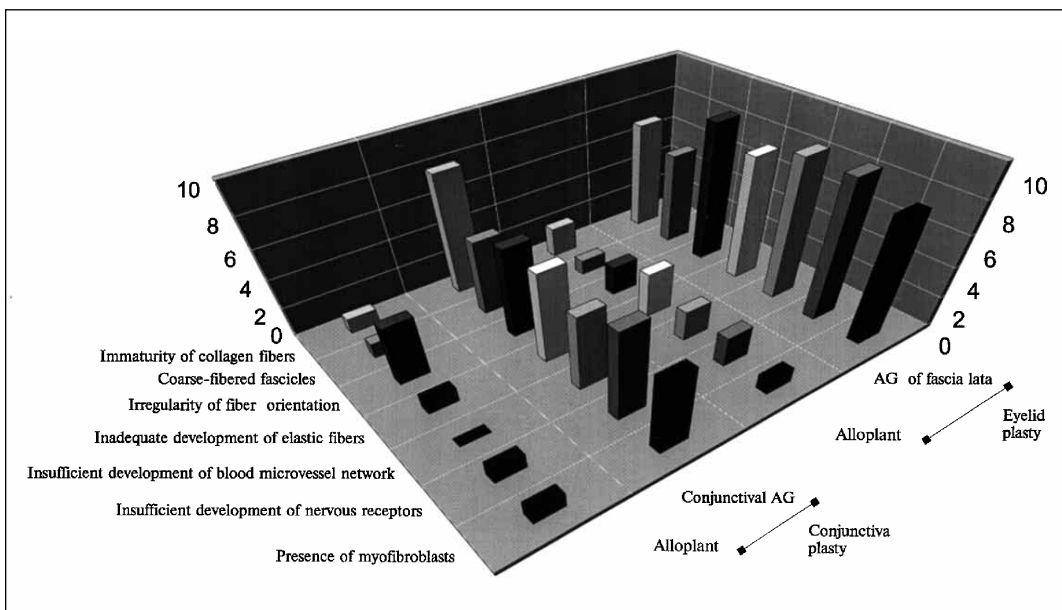
Thus, it was assumed that an attempt to devise allografts with controlled *in vitro* extraction of GAG from the collagen fibers was quite justified, so that the allografts could be of low antigenicity as proved by the above-mentioned studies. It was observed that GAG can be extracted from the collagen fibers using chemical treatment of cadaveric tissues (Fig. 1b).

The immunologic evaluation of the allografts with the controlled GAG extraction confirmed the significantly lower immunogenic properties thereof. A comparison of tissue reaction as opposed to the native allografts revealed lower edema, lymphocytic infiltration, density of immune cells, and width of the response area (Fig. 2). Immunologic studies using blood

and tears from the animals revealed that there was a slighter immune response after using allografts with controlled GAG extraction as opposed to native allografts. Hence, the controlled extraction of GAG from collagen fibers allows for a reduction in allograft antigenicity.

Experimental morphological studies showed that allografts with partially extracted GAG were gradually replaced by recipient tissues. In those studies 2 types of allograft replacement were observed: scar regen-

**Fig. 4** - Comparative estimation of the morphological signs of scarring during allograft replacement in the conjunctiva and eyelid plasty with allografts (AG) having different fibroarchitectures.



eration and regeneration of the natural tissue with a perfect structure. It is obvious that the scarring type of allograft replacement is undesirable, since severe postoperative complications may take place due to scarring.

A profound comparative histologic analysis showed that the scarring type of regeneration is caused by a substantial difference between the fibroarchitecture of the allograft and the reconstructed tissue. For example, tarsus repair using an allograft of fascia lata (Fig. 3c), which is very different from the tarsus (Fig. 3a), led to cicatricial deformation of the eyelid. A complete structural identity (e.g., tarsus repair with a tarsus allograft) also led to scarring (Fig. 3e).

We observed the relatively quick resorption of the allograft in relation to time, and its replacement by the connective tissue imperfect in structure. However, a slight structural difference between allograft and reconstructed tissue, e.g., tarsus repair using a plantar dermal allograft (Fig. 3b), led to replacement of the graft by the tarsus-like recipient tissue with much less scarring (Fig. 3d).

A similar regularity in conjunctivoplasty was observed. When histologically investigated, there was poor development in the newly-formed tissue of such differentiated elements as blood vessels, nerve endings, etc.

A morphometric examination of tissue fibroarchitecture disclosed that natural tissue regeneration dur-

ing allograft replacement can take place when about 70% structural resemblance of the allograft and reconstructed tissues are present. In order to prove this by using the scarring signs, two series of the experimental studies were carried out, revealing the following. In the first series of animals, the tarsus was repaired with allografts of plantar derma that had about 70% structural resemblance, and fascia lata that had about 35%. In the second series, the conjunctiva was repaired with allografts of visceral fascia (70% structural similarity) and allogenic conjunctiva (100% similarity). The studies showed that in both series signs of scarring were fourfold less in cases with 70% resemblance of the allograft and reconstructed tissues (Fig. 4).

Therefore, the allograft selected according to the morphometric estimation allowed for a delay in the scarring process and allograft replacement by natural tissues.

## DISCUSSION

The present work may be considered a basis for the elaboration of a systematic approach to allograft application in ophthalmosurgery.

The first problem that we were trying to solve was that of a reduction of allograft antigenic properties. The common assumption is that transplant antigenicity

---

*Basic research conducted on alloplant biomaterials*


---

is conditioned by water-soluble proteins contained in the cellular elements and that removal thereof from the tissues to be transplanted is sufficient for a reduction in antigenicity (16, 17). However, in some publications proteoglycans are also considered to be antigenic components (4), collagen being the only non-immunogenic component.

Our histological and electron histochemical studies showed that allograft antigenicity correlates with the acid glucosaminoglycan extraction from the primary structure of collagen fibers. The albuminous core of proteoglycans extracted during the chemical processing of the transplants, is also probably antigenic. However, antigenicity conditioned by the above-mentioned albuminous core does not cause an immune reaction, rather it is sufficient to stimulate tissue regeneration. This can explain why allografts with controlled GAG extraction induce a slight inflammatory reaction and are gradually resorbed with further simultaneous replacement by the regenerating tissue (the regenerate).

Another aspect of our studies, i.e., prevention of scar formation after allografting, is essential especially in delicate aspects of microsurgery.

The scarring type of transplant replacement is observed in cases of orthotopic alloplasty (18) when the transplant structure does not differ from the structure of the reconstructed tissue. This phenomenon can also be found after implantation of aldehyde-preserved allografts which are surrounded by fibrotic connective tissue (4, 19), the latter also being cicatricial

because of its avascular texture. Moreover, from a morphological point of view the fibrotic capsule around the transplant is a newly formed scar tissue without merging with the allograft. In this case there is no way we can talk about a regenerate, since the allograft does not undergo any changes, being, in fact, a foreign body with a fibrotic capsule that has grown around it.

The outcome of our experimental and morphologic studies was the development of a criterion for allograft selection based on the grade of morphological conformity of the allograft and reconstructed tissue. Our results demonstrate that the no-scar regenerate develops with about 70% structural resemblance of the allograft and the reconstructed tissue. This permits adequate selection of allogenic tissues for particular types of ophthalmosurgery, as well as allograft replacement by a structurally appropriate newly-formed tissue (the regenerate) and efficient prevention of regenerate scarring. Thus, the results of our basic research showed that Alloplant biomaterials can selectively stimulate natural tissue regeneration. Hence, Alloplant biomaterials can be utilized in surgery for the restoration of different tissues.

Reprint request to:  
 Prof. Ernst R. Muldashev  
 Russian Eye and  
 Plastic Surgery Center  
 47 Koltseraya str.  
 Ufa 450040, Russia

---

**REFERENCES**

1. Williams DF, Roaf R. *Implants in surgery*. London, Philadelphia, Toronto: WB Saunders, 1973. Moscow: Medicina, 1978; 552.
2. Imamaliev AS, Dadashev HD. Allotendinous plasty with the use of allotransplants sterilized in the formalin steam. In: *Transplantation of the biological tissues, sterilized and preserved in formalin*. Leningrad: Vreden's Institute, 1980; 59-64.
3. Klen R. *Preparation and preservation of tissues*. Prague, Moscow: Medicina, 1962; 316.
4. Tauro JC, Parsons JR, Ricci J, Alexander H. Comparison of bovine collagen xenografts to autografts in the rabbit. *Clin Orthop* 1991; 266: 271-84.
5. Vrabec MP, Weisenthal RW, Elsing SH. Subconjunctival fibrosis after conjunctival autograft. *Cornea* 1993; 12: 181-3.
6. Titova AT, Yarchuk HI, Rumyantseva VO. The usage of the allogenic fascia for the elimination of the facial defects. *Stomatologia* 1979; 5: 26-31.
7. Muldashev ER, Gabbasov AG, Nigmatullin RT, et al. Some approaches to the selection of the allografts in ophthalmic surgery. In: *Topical problems of organs and tissues transplantation*. Moscow: II Moscow Medicine Institute, 1978; 21-2.
8. Wolman M, Kasten FH. Polarized light microscopy in the study of collagen and reticulin. *Histochem* 1986; 85: 41-9.
9. Luppia H. *Grundlagen der Histochemie*. Berlin: Akademie-Verlag, 1977; Moscow: Mir, 1980; 343.

10. Scott JE, Dorling J. Differential staining of acid glycosaminoglicans (mucopolysaccharides) by Alcian blue in salt solutions. *Histochemie* 1965; 5: 221-33.
11. Scott JE. Contribution of light and electron histochemical technique to the study of proteoglican function in cartilage. *Acta Biol Hung* 1984; 34: 227-32.
12. Behnke O, Zelander UT. Preservation of intercellular substances by the cationic dye Alcian blue in preparative procedures for electron microscopy. *J Ultrastruct Res* 1970; 31: 424-38.
13. Sewell WR, Wiland J, Craver BN. New method of comparing sutures of ovine catgut with sutures of bovine catgut in three species. *Surg Gynecol Obstet* 1955; 100: 483-9.
14. Serov VV, Shekhter AB. *Connective tissue*. Moscow: Medicina, 1981; 312.
15. Fenchin KM. *Healing of the wounds*. Kiev: Zdrov'ja, 1979; 168.
16. Seiffert KE. Biological aspects of collagenous homografts. *Acta Otorhinolaryngol Belg* 1970; 24: 27-33.
17. Bujia J, Wilmes E, Bartual-Pastor J, Hammer C. Estudio comparativo del efecto de distintos procedimientos quimicos sobre la antigenicidad de transplantes allogenos de traquea humana. *Acta Otorhinolaringol Esp* 1993; 44: 209-16.
18. Salamon A, Hamori J. Development of collagenous fibres in autologous and preserved homologous tendon grafts. *Acta Morphol Acad Sci Hung* 1976; 24: 11-22.
19. Schmidt T, Leipert KP, Fellbaum C. Tarsusplastik mit Chondroplast. *Fortschr Ophthalmol* 1991; 88: 279-82.