

New forceps and spatula for easy retropupillary implantation of iris claw lenses in aphakia: Experience in 4 years of use

W. SEKUNDO

Department of Ophthalmology, Gutenberg University of Mainz, Mainz - Germany

PURPOSE. *Retropupillary implantation of an iris claw lens offers a rapid and atraumatic approach for rehabilitation of aphakic eyes. The difficulty in the implantation process arises because of the possibility of losing the intraocular lens (IOL) into the vitreous cavity and the need to change the hand holding the forceps during the enclavation.*

METHODS. *The new forceps design radically changes the method of grasping an IOL. It contains an extendable supporting plate with a hook-like end. The instrument achieves a horizontal three-point fixation at the edge of the implant in the 6 and 12 o'clock position in order to prevent slippage into the vitreous cavity during the inclination. The supporting plate also has a horizontal mark to facilitate the centration of the IOL behind the pupil level. A long vitreoretinal-type shaft has been turned 90° to exclude the possibility of an accidental release during implantation. A special slender long spatula with an internal twist enables one-hand enclavation through the same side port without the need to change the hand holding the forceps.*

RESULTS. *The author has implanted over 100 iris claw IOLs during the last 4 years without any intra- or postoperative complications.*

CONCLUSIONS. *The new forceps and spatula enable safe, easy, and rapid implantation of iris claw IOLs into the retropupillary space. (Eur J Ophthalmol 2008; 18: 442-4)*

KEY WORDS. *Forceps, Spatula, Implantation of iris claw IOLs, Retropupillary space*

Accepted: November 3, 2007

INTRODUCTION

The Worst iris claw intraocular lens (IOL) (Artisan™, Verisyse™) has been in use for many years as an anterior chamber IOL in aphakic eyes without capsular support. Amar (1) was the first author to suggest a retropupillary implantation as an alternative method to the anterior fixation. However, because of the possibility of pigment dispersion due to rubbing of the anterior IOL surface at the posterior pigmented layer of the iris, this approach was left unnoticed for many years. Mohr et al (2) solved this problem by implanting the IOL in the inverted position: with the convex side up, toward the posterior iris. These

authors used traditional implantation forceps which sandwich the IOL optic from above and below. The danger of this type of forceps is that the surgeon has to keep a firm hold on the IOL when it dives behind the iris in order not to release the lens into the vitreous cavity.

The aim of our design was to create a new forceps that can ensure a safe grip on the IOL, at the same time enabling a good centration of the implant. Moreover, the cumbersome change of the hand holding the forceps (using conventional forceps) inevitably produces some movement of the IOL behind the iris. Thus, this maneuver may become traumatic to the gentle iris structures, such as iris pigment epithelium.


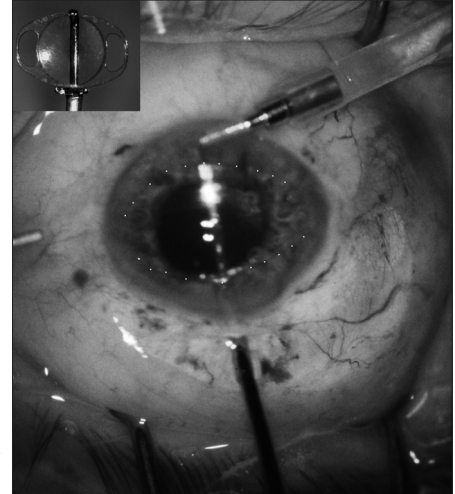


Fig. 1 - Drawing of the new forceps (top). The intraocular part features an extendable supporting plate with a hooked end that locks the intraocular lens against the opposite counterpart hooks (inset on the top). A slender elongated spatula (bottom) has been designed for the enclavation of both haptics through one side port (also see Fig. 3).

METHODS

The new forceps design radically changes the method of grasping an IOL. Instead of being grasped in the vertical plane from the anterior and the posterior surface as in all traditional designs, the lens is now grasped in the horizontal plane. This is achieved by an extendable supporting plate with a hook-like end (Fig. 1, top). The IOL is locked in the horizontal plane by three-point fixation at the edge of the implant at the 6 and 12 o'clock position in order to prevent slippage into the vitreous cavity during the inclination. We enabled a nice and snug fit of the IOL optic and the supporting plate by adjusting the inner curvature of the plate to the outer convex curvature of the inverted aphakic iris claw IOL of +25 D power. The supporting plate also has a horizontal mark to facilitate the centration of the IOL behind the pupil level. A long vitreoretinal forceps-type shaft has been turned 90° (Fig. 1, top). Initially, the surgeon holds the new forceps with the thumb and the index finger with the middle (second) finger resting (like holding a pencil exerting pressure by the thumb and the index finger). The supporting plate at the tip extends when the branches at the shaft are pressed with the thumb and the index finger together. Once the IOL is in the desired position under good visualization within the anterior chamber, the branches at the shaft are released and the supporting plate is withdrawn, firmly pressing the IOL against the other two hook ends. Now the surgeon holds the shaft more with the middle finger and the thumb. The index finger rests in a supporting fashion only: this excludes the possibility of inadvertent pressure onto the shaft branches during the enclavation process, with a subsequent accidental

Fig. 2 - After the inverted iris claw lens has been introduced into the anterior chamber and rotated into 3 and 9 o'clock position the new forceps is inserted under the intraocular lens (IOL) which becomes engaged between the claws (hooks) of the forceps. The transparent IOL is highlighted by a dotted line. The inset in top left corner demonstrates the working principle of the forceps.



IOL release into the vitreous cavity.

After the IOL has been brought behind the iris, and the pupil constricted with acetylcholine, a new specially designed spatula (Fig. 1, bottom) is inserted into the anterior chamber filled with some viscoelastic. This special spatula has a very long, slender tip, which can easily reach the opposite peripheral iris across the entire width of the anterior chamber. In addition, the spatula has an internal twist for a comfortable enclavation position. Thus, iris tissue can be gently "fed" between the IOL claws through the same side port with the nondominant hand only. There is no need to change the hand holding the forceps (Figs. 2 and 3 for details).

The author has safely and easily implanted over 100 iris claw IOLs into the retropupillary space.

DISCUSSION

Despite the fact that the iris claw IOL for aphakia was designed by Jan Worst for anterior chamber (AC) implantation, its popularity as a posterior chamber (PC) implant has been continuously rising in Germany since the modified technique was described by Mohr et al (2). The implantation of the Worst IOL into the posterior chamber has several advantages:

1. Reduced corneal endothelial trauma.
2. Reduced reflection of incoming light rays.
3. Better cosmetic, more anatomic result compared to the AC position.
4. Reduced surgical trauma as compared to iris or sclera sutured PC IOLs.

New forceps and spatula for implantation of iris claw lenses

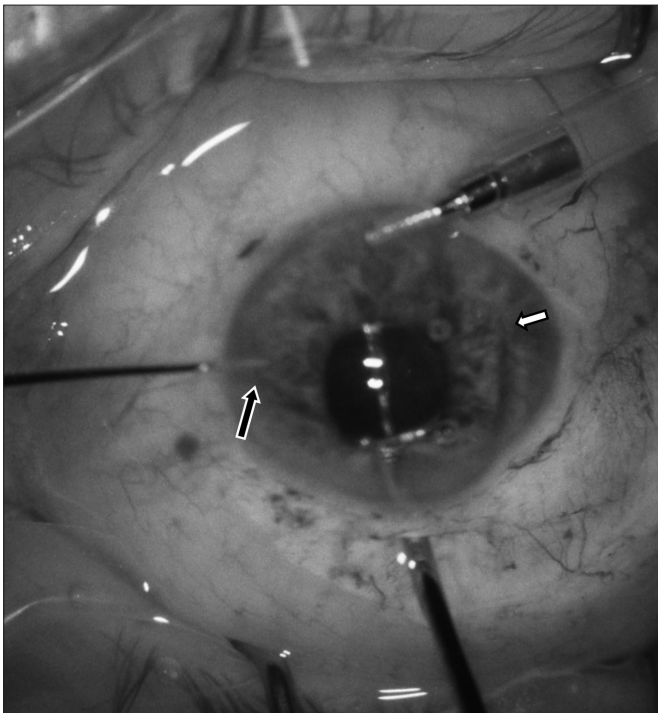


Fig. 3 - After the intraocular lens (IOL) has been introduced into the retropupillary space, the pupil was brought down by an injection of acetylcholine. The new special spatula is introduced through the side port by a nondominant hand; the IOL is slightly tilted to identify the position of the haptic claws. The distal iris has already been enclavated (short arrow). The peripheral iris tissue at the proximal haptic is being fed in between the haptic claws by the spatula (long arrow).

Turning the optic of the plan-convex IOL with the convex surface pointing toward the posterior segment has both positive and negative aspects. On one hand, there is almost no iris pigment epithelium shaving at the optic; on the other hand, there is a negligible increase in optical aberrations, as recently shown by Kaymac et al (presented at the annual ESCRS meeting; Lisbon; 2005). As the vast majority of our patients were of advanced age, their scotopic pupil was well below 4 mm. Optical aberrations are low when the aperture is small. We believe this to be the reason why there were no clinical complains from our patients. Nevertheless, younger patients might be better off being implanted with a large optic sutured PC IOL.

The popularity of the retropupillary iris claw lens implantation also reflects the experience of a short duration. In an already vitrectomized eye the entire surgery lasts no longer than 15 to 20 minutes, resulting in a very satisfactory anatomic appearance (Fig. 4).

In conclusion, the new forceps and the spatula presented here combine easy handling with a relatively short learning

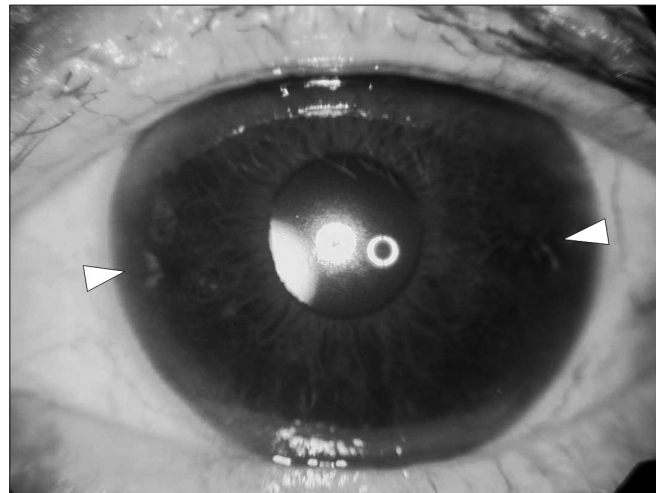


Fig. 4 - Slit-lamp photograph on the first day of follow-up (different case). The iris folds are barely distinguishable (arrowheads), the pupil is round, and the intraocular lens is well centered behind the iris.

curve and unique safety features. The chance of losing the IOL into the vitreous cavity has been significantly reduced.

ACKNOWLEDGEMENTS

The concept of this new forceps/spatula set would be impossible without the craftsmanship of Norbert Braun, instrument maker at Geuder GmbH, Heidelberg, Germany.

This instrument received the Leonhard-Klein award of the German Ophthalmological Society in 2007.

The author has no financial or proprietary interest in any material or method mentioned.

Reprint requests:
 Prof. Walter Sekundo, MD
 Department of Ophthalmology
 Universitäts-Augenklinik
 Langenbeckstr. 1
 D-55131 Mainz, Germany
 sekundo@augen.klinik.uni-mainz.de

REFERENCES

1. Amar L. Posterior chamber iris claw lens. *Am Intraoc Implant Soc J* 1980; 6: 27.
2. Mohr A, Hengerer F, Eckard C. Retropupillare Fixation der Irisklauenlinse bei Aphakie. *Ophthalmologe* 2002; 99: 580-3.