

Effect of pterygium surgery on corneal topography

K. ERRAIS, J. BOUDEN, I. MILI-BOUSSEN, R. ANANE, O. BELTAIF, A. MEDDEB OUERTANI

Department of Ophthalmology, Charles Nicolle University Hospital, Tunis - Tunisia

PURPOSE. To evaluate the effect of successful pterygium surgery on corneal topography.

METHODS. Computerized corneal topography was performed on 20 eyes with pterygium before and 3 months after successful excision and limbo-conjunctival autograft surgery. Corneal shape, corneal spherical power, simulated keratometric astigmatism, surface regularity index (SRI), and surface asymmetry index (SAI) were assessed before and after surgery. Pre- and postoperative uncorrected visual acuity (UCVA), best spectacle-corrected visual acuity (BSCVA), and manifest refraction spherical equivalent (MRSE) were also evaluated.

RESULTS. Changes in corneal shape were mainly a decrease in midline corneal flattening. Corneal spherical power was 41.65 ± 3.29 diopters (D) (mean \pm SD) preoperatively and 44.58 ± 1.55 D postoperatively ($p=0.04$). Simulated keratometric astigmatism was 5.47 ± 3.45 D preoperatively and 1.79 ± 1.52 D postoperatively ($p=0.0005$). SRI was 1.39 ± 0.93 preoperatively and 1.10 ± 0.57 postoperatively ($p=0.03$). SAI was 1.17 ± 1.09 preoperatively and 0.75 ± 0.73 postoperatively ($p=0.02$). UCVA was 0.31 ± 0.33 preoperatively and 0.52 ± 0.32 postoperatively ($p=0.04$). BSCVA was 0.73 ± 0.20 preoperatively and 0.89 ± 0.16 postoperatively ($p=0.008$). MRSE was -0.54 ± 3.29 D preoperatively and -1.30 ± 3.05 D postoperatively ($p=0.45$).

CONCLUSIONS. Corneal topographic changes caused by the pterygium are almost reversible after surgical treatment. Successful pterygium surgery significantly reduces topographic astigmatism, SRI, SAI, and corneal flattening. However, precise prediction of these refractive changes is not always accurate. (*Eur J Ophthalmol* 2008; 18: 177-81)

KEY WORDS. Astigmatism, Corneal topography, Pterygium

Accepted: September 18, 2007

INTRODUCTION

Pterygium is a fibrovascular connective tissue overgrowth of bulbar conjunctiva and underlying subconjunctival tissue onto the cornea (1). It is a proliferative disease characterized by conjunctivalization of the cornea due to localized ultraviolet induced damage to the limbal stem cells (2). Indications for its surgical removal include not only recurrent inflammation, restriction of ocular motility, and cosmetic problems, but also visual impairment due to marked changes in refractive state and corneal curvature before entering the optical zone. The astigmatism associated with pterygia might result from different mechanisms

which lead to flattening of the cornea central to the apex. The aim of the current prospective study was to investigate the effect of successful pterygium surgery on corneal topographic features.

MATERIALS AND METHODS

A prospective clinical study was performed. The study sample consisted of 20 eyes of 17 patients undergoing primary pterygium removal surgery from January 2003 through November 2004, at the Department of Ophthalmology of Charles Nicolle Hospital, University of Tunis,

Tunisia. Patients were 14 women and 3 men. Their mean age was 49.3 ± 19.64 years (range: 29–66 years). Exclusion criteria were history of corneal trauma, history of ocular surgery including pterygium surgery, corneal scarring, and pterygium recurrence after surgery.

Computerized corneal topography and videokeratography (TMS-2, Computed Anatomy Inc., New York, NY) was obtained on the 20 eyes with pterygium before surgery. The TMS-2 topographic modelling system relies upon Placido-type concentric ring reflections. The program identifies the location of 256 circumferential points of each mire. This information is used to compute the power in diopters and the radius of curvature at each circumferential point (3). For each eye, acquisitions were repeated until a well focused image was obtained. This image was then captured and analyzed. Corneal shape is first assessed in color-coded contour maps. On these maps, areas with the same refractive power are on the same contour and are therefore depicted in the same color. Warmer colors (red, orange, yellow) represent the steeper areas whereas cooler colors (green and blue) mark the flatter ones (3).

We analyzed the most useful statistical indices (3). The corneal spherical power is the effective refractive power of the cornea within the 3 mm pupil zone. It is calculated using data from all meridians. The simulated keratometry readings are calculated by determining the average power along each meridian within the 3 mm central zone. The major axis is that with the greatest power and the minor axis is at 90° to it. The keratometric astigmatism is the difference between the major and minor axis. The surface asymmetry index (SAI) is a quantitative indicator of the differences in corneal power between corresponding points on the TMS-2 mires 180° apart. Normal corneas generally have SAI values less than 0.5. The surface regularity index (SRI) is a parameter calculated from the local regularity of the surface of the cornea enclosed by an approximative average virtual pupil of 4.5 mm. SRI is an indicator of corneal optical quality; it has relatively low normal values.

Manifest refraction using the fogging technique and evaluation of uncorrected visual acuity (UCVA) and best spectacle-corrected visual acuity (BCVA) were also performed before surgery.

Indications for surgical pterygium removal included visual impairment, chronic inflammation, and cosmetic problems.

The surgical procedure was as follows. Under topical

and/or subconjunctival local anesthesia, the pterygium head was taken off the cornea and dissected from the corneal surface. The pterygium head and the body tissue were then resected from the underlying sclera 4 to 5 mm from the limbus. Sharp dissection of subconjunctival fibrous tissue was performed, leaving a bare scleral bed. The defect area was covered with a free limbo-conjunctival autograft moved from the superior bulbar conjunctiva and free from the Tenon capsule. It was then secured at the limbus with interrupted 10-0 monofilament nylon sutures, and peripherally to the surrounding conjunctiva and episclera by 7-0 Vicryl sutures.

Postoperatively, the patients were started with topical corticosteroids, tapered over 4 weeks, and topical antibiotics for 2 weeks.

Computed corneal videokeratography, manifest refraction, and visual acuity measurement were performed 3 months after surgery, once corneal shape was stabilized.

Statistical analysis

Data are expressed as mean \pm standard deviation. Comparison between pre- and postoperative values was done with the paired two-tailed test; a p value less than 0.05 was considered statistically significant.

RESULTS

Before surgery, corneal topography map assessment showed a corneal flattening at the midline and nasal quadrant, where the pterygium is located (Fig. 1A). This change in corneal topographic feature decreased or disappeared after surgery (Fig. 1B).

Changes in refractive parameters after surgical removal are summarized in Table I. Surgery significantly increased spherical power of the cornea from 41.65 ± 3.29 to 44.58 ± 1.55 diopters (D) ($p=0.04$) (Tab. I, Fig. 2). The preoperative simulated keratometric astigmatism at the central 3 mm decreased in 16 eyes, increased in 2 eyes, and remained unchanged in 2 eyes (Fig. 3). Its mean value decreased significantly from 5.47 ± 3.45 D preoperatively to 1.79 ± 1.52 D postoperatively ($p=0.0005$). Yet no linear correlation was observed between pre- and postoperative keratometric astigmatism ($p=0.073$). The astigmatism axis was unchanged after surgery. Mean preoperative axis of the steepest corneal meridian was 85.5° (range 4° – 167°).

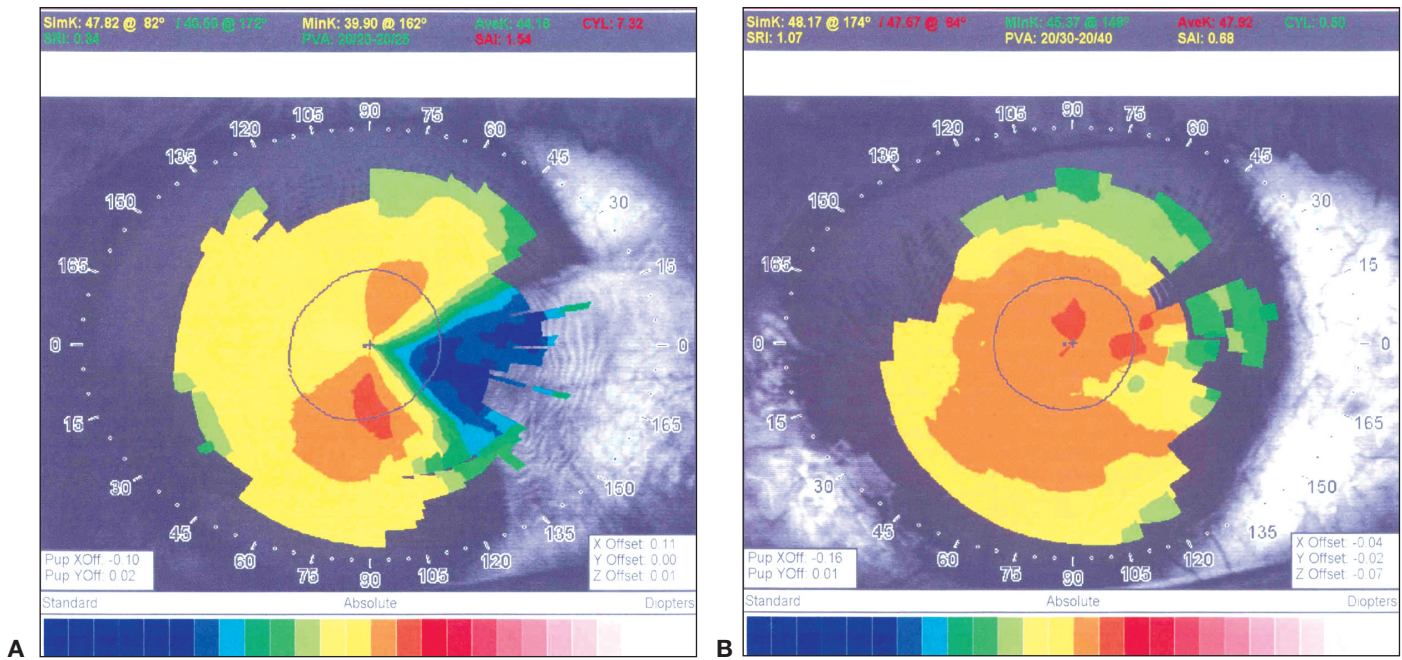


Fig. 1 - (A) Preoperative topographic picture of an eye with primary pterygium. There are 7 diopters of regular astigmatism and increased value of SAI to 1.54. **(B)** Postoperative topographic picture of the same eye showing decreased regular astigmatism to 0.5 diopters and decreased value of SAI to 0.68.

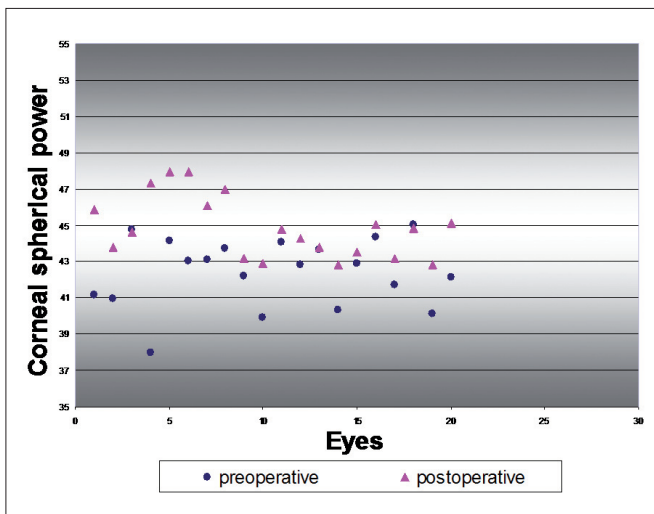


Fig. 2 - Pre- and postoperative corneal spherical power. Significant difference between pre- and postoperative corneal spherical power ($p=0.04$).

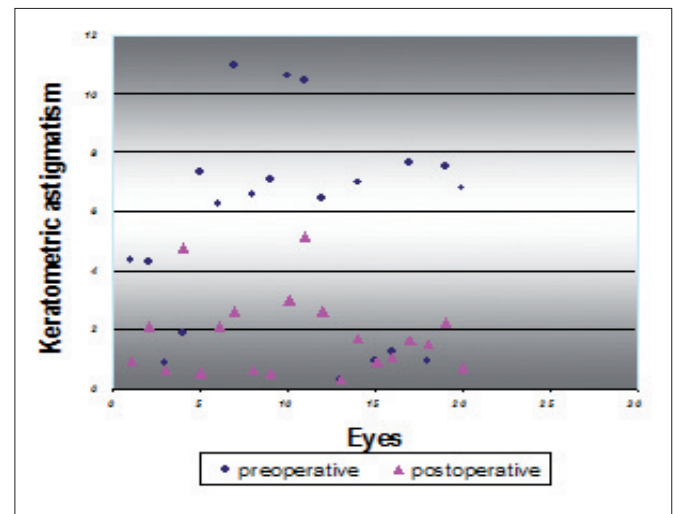


Fig. 3 - Pre- and postoperative keratometric astigmatism. Significant difference between pre- and postoperative corneal astigmatism ($p=0.0005$).

Postoperatively, it was 79.2° (range 11° – 174°). Surgery significantly decreased surface asymmetry and regularity indexes (SAI and SRI). SAI decreased from 1.17 ± 1.09 to 0.75 ± 0.73 ($p=0.02$), and SRI from 1.39 ± 0.93 to 1.10 ± 0.57 ($p=0.03$) (Tab. I).

Manifest refraction spherical equivalent changed from -0.54 ± 3.29 D to -1.31 ± 3.05 D ($p=0.45$) (Tab. I). UCVA improved significantly from 0.31 ± 0.33 to 0.52 ± 0.32 ($p=0.04$) and BSCVA improved significantly from 0.73 ± 0.20 to 0.89 ± 0.16 ($p=0.008$) (Tab. II).

TABLE I - CHANGES IN REFRACTIVE PARAMETERS AFTER PTERYGIUM REMOVAL SURGERY

Parameter	Preoperative (mean ± SD)	Postoperative (mean ± SD)	p value*
Keratometric astigmatism (D)	5.47±3.45	1.79±1.52	0.0005
Spherical power (D)	41.65±3.29	44.58±1.55	0.04
SRI	1.39±0.93	1.10±0.57	0.03
SAI	1.17±1.09	0.75±0.73	0.02
MRSE (D)	-0.54±3.29	-1.30±3.05	0.45

*Paired two-tailed t test.

D = Diopters; SAI = Surface asymmetry index; SRI = Surface regularity index; MRSE = Manifest refraction spherical equivalent

TABLE II - CHANGES IN VISUAL ACUITY AFTER PTERYGIUM REMOVAL SURGERY

Parameter	Preoperative (mean ± SD)	Postoperative (mean ± SD)	p value*
UCVA	0.31±0.33	0.52±0.32	0.04
BSCVA	0.73±0.20	0.89±0.16	0.008

*Paired two-tailed t test.

UCVA = Uncorrected visual acuity; BSCVA = Best spectacle-corrected visual acuity

DISCUSSION

It has been established that, before entering the optical zone, pterygium can cause flattening of the central cornea, often resulting in within-the-rule astigmatism (4, 5). More corneal topographic changes have been revealed using computerized corneal topography systems. In this study, videokeratoscopic images obtained by TMS-2 system allowed us to analyze corneal surface changes induced by pterygium and their reversibility after successful surgery.

Several mechanisms have been reported to explain corneal flattening induced by pterygium. Yasar et al (6) have recently postulated that the pooling of tears at the pterygium apex plays an important role in corneal topographic changes. In fact, a tear meniscus developing between the corneal apex and elevated pterygium may flatten the normal corneal curvature in that area (7, 8).

Besides, subepithelial fibrosis beneath the head of the pterygium can cause localized flattening by a direct traction effect on the underlying stroma (3).

This mechanism seems unlikely (3, 6), since no myofibroblast cells were found within the head and body specimen of pterygium tissue (7). However, Touhami et al (9), using immunostaining with cell specific markers and ultrastructural analysis, have recently found myofibroblast

cells in the fibrovascular tissue around the head and body of the studied pterygia. This may explain the pterygium traction effect.

As pterygium mainly results from stem cells deficiency (2), and because of the low recurrence rates reported after this technique (10), we chose pterygium excision with a limbo-conjunctival autograft as a surgical procedure.

As reported in the current study, horizontal flattening is the most frequent corneal topographic shape in eyes with pterygia (1, 4, 6). Yet this change in corneal topographic feature often decreases or disappears after successful surgery (1, 11).

Bahar et al (11) reported a significant decrease in corneal astigmatism at the central 3 mm after pterygium surgery. Tomidokoro et al (1) similarly reported that surgery decreases corneal astigmatism with no change in the axis; it also decreases SAI and SRI but significantly increases spherical power of the cornea (1). Moreover, the surgically induced changes in spherical power and corneal astigmatism significantly correlated with the pterygium preoperative extension (1).

Similarly, in the present study, mean keratometric astigmatism significantly decreased from 5.47 to 1.79 D following surgery. We have found no effect of surgery on the axis of pterygium induced astigmatism. As in some other reports (11), we found no correlation between pre- and

postoperative degree of corneal astigmatism. Indeed, astigmatism up to 3 diopters persisted in some cases; some patients had even their preoperative astigmatism increased after surgery. This finding has been reported by others (1, 11, 12). Bahar et al (11) described it as "unexpected effect of surgery on corneal shape." It could be attributed to corneal feature itself, since all cases have undergone the same surgical procedure.

In our study, SAI and SRI were also decreased by surgery, indicating better optical quality of corneal surface. We believe that UCVA and BSCVA improvement after surgery, as was reported by other authors (11, 13), could be explained by better optical quality associated to corneal astigmatism decrease.

Through the significant increase in spherical corneal power after surgery, we could demonstrate that flattening of the central cornea caused by pterygium is reversible by surgical removal. Besides, this increase in spherical corneal power may have induced the slight non-statistically significant myopic shift noted after surgery (Tab. I).

Thus, as was previously suggested (1), we believe that

cataract or refractive surgery, if considered in these patients, should be performed after pterygium surgery so as to have a stabilization of corneal refractive components.

Our study confirms that successful pterygium surgery significantly reduces topographic astigmatism, SRI, SAI, and corneal flattening. Corneal topographic changes caused by the pterygium are almost reversible after surgical treatment. However, precise prediction of refractive changes is sometimes needed especially if further cataract or refractive surgery is considered.

There was no financial support for this study and the authors have no commercial or proprietary interest in any aspect of the article.

Reprint requests to:
Khalil Errais, MD
5 Rue El-Birouni
1082, Tunis, Tunisia
erraiskhalil@planet.tn

REFERENCES

- Tomidokoro A, Myata K, Sakaguchi Y, Samejima T, Tokunaga T, Oshika T. Effects of pterygium on corneal spherical power and astigmatism. *Ophthalmology* 2000; 107: 1568-71.
- Dushku N, Reid TW. Immunohistochemical evidence that human pterygia originate from an invasion of vimentin-expressing altered limbal epithelial basal cells. *Curr Eye Res* 1994; 13: 473-81.
- Corbett MC, Rosen ES, O'Brart DPS. Presentation of topographic information. *Corneal Topography: Principles and Applications*. London: BMJ Books, 1999; 32-58.
- Lin A, Stern GA. Correlation between pterygium size and induced corneal astigmatism. *Cornea* 1998; 17: 28-30.
- Pavilack MA, Halpern BL. Corneal topographic changes induced by pterygia. *J Refract Surg* 1995; 11: 92-5.
- Yasar T, Ozdemir M, Cinal A, Demirok A, Ilhan B, Durmus AC. Effects of fibrovascular traction and pooling of tears on corneal topographic changes induced by pterygium. *Eye* 2003; 17: 492-6.
- Oldenburg JB, Garbus J, McDonnell JM, McDonnell PJ. Conjunctival pterygia: mechanisms of corneal topographic changes. *Cornea* 1990; 9: 200-4.
- Corbett MC, Rosen ES, O'Brart DPS. Corneal surface disease. *Corneal Topography: Principles and Applications*. London: BMJ Books, 1999; 101.
- Touhami A, Di Pascuale MA, Kawatika T, et al. Characterisation of myofibroblasts in fibrovascular tissues of primary and recurrent pterygia. *Br J Ophthalmol* 2005; 89: 269-74.
- Fernandes M, Sangwan VS, Bansal AK, et al. Outcome of pterygium surgery: analysis over 14 years. *Eye* 2005; 19: 1182-90.
- Bahar I, Loya N, Weinberger D, Avisar R. Effect of pterygium surgery on corneal topography: a prospective study. *Cornea* 2004; 23: 113-7.
- Cinal A, Yasar T, Demirok A, Topuz H. The effect of pterygium surgery on corneal topography. *Ophthalmic Surg Lasers* 2001; 32: 35-40.
- Walkow T, Daniel J, Meyer CH, Rodrigues EB, Mennel S. Long-term results after Bare sclera pterygium resection with excimer smoothing and local application of mitomycin C. *Cornea* 2005; 24: 378-81.