

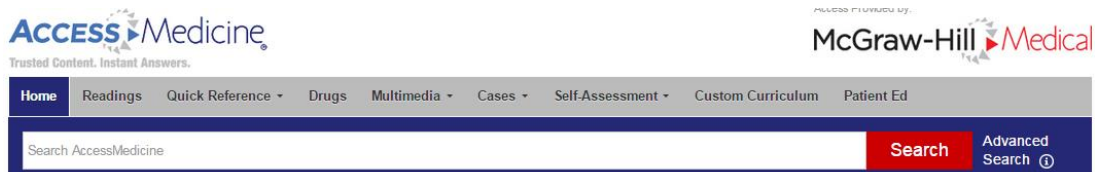SUBJECT	의학 전반
PUBLISHER	McGraw- Hill Education (http://www.mheducation.com)
접속 URL	http://www.accessmedicine.com
EDITION	Title 마다 최신 edition 제공
DATA TYPE	HTML

출판사소개 **McGraw-Hill Education**
1888년부터 출판을 시작하였으며 의학, 경영, 과학 등 분야에 있어 주요 title 을 전 세계 대학 및 연구기관에게 제공하는 major 출판사로 그 역할을 하고 있습니다.


내용 및 특징

I. AccessMedicine?

- 1. 제공 title 수: 99 titles (매년 title 추가!!!)
- 1) Clinical Library: 22 titles+ **Harrison's Principles of Internal Medicine** 포함
- 2) LANGE Educational Library: 53 titles+
- LANGE Basic Science: 23 titles+ / LANGE Clinical Science: 30 titles+



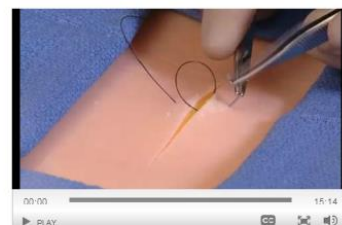Read



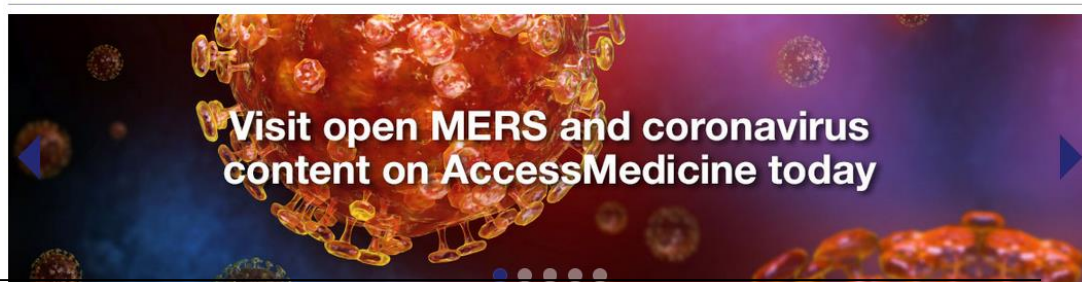
Learn



Watch




Featured



II. 기타 유용한 부가 서비스

1) Multimedia

- AccessMedicine의 Title과 관련된 주제의 내용을 알기 쉽게 동영상 및 애니메이션으로 제공



2) Self-Assessment tool - 문제풀이

- AccessMedicine의 Title과 관련된 문제 및 해설을 제공함으로 학습 및 이해력 증진

(Source: Harrison's Online, Williams Obstetrics, Lange Self-Assessment tool 등)

ACCESSMedicine

Harrison's Principles of Internal Medicine: Self-Assessment and Board Review, 18e

< Back to Main Test Results

Question 1 of 1

You incorrectly answered A. The correct answer is D

A 24-year-old woman seeks evaluation for a rash that is present diffusely on her back, buttocks, elbows, and knees. The rash began abruptly and the patient is complaining of severe pruritus and burning associated with the rash. A biopsy of the rash demonstrates neutrophilic dermatitis within the dermal papillae, and immunofluorescence highlights granular deposition of IgA in the papillary dermis and along the epidermal basement membrane zone. What treatment do you recommend for this patient?

A. Dapsone 100 mg daily

B. Gluten-free diet

C. Prednisone 40 mg daily

D. A and B

E. All of the above

The answer is D.

Dermatitis herpetiformis (DH) is an immunologic skin disorder characterized by severe pruritus with skin lesions symmetrically distributed along the extensor surfaces, buttocks, back, scalp, and posterior neck. The lesions of DH may be papular, papulovesicular, or urticarial plaques. Because of the severity of the associated pruritus, many patients do not exhibit the primary skin lesions but have excoriations and crusted papules. Burning and stinging are also frequently reported along with the pruritus, and these symptoms are present prior to the manifestation of skin lesions. Almost all patients have an associated gluten-sensitive enteropathy, although it may be clinically unrecognized on presentation. Pathologically, the lesions demonstrate a neutrophilic inflammatory infiltrate in the dermal papillae. On immunofluorescence, granular deposits of IgA are found in the papillary dermis and along the epidermal basement membrane. The primary treatment of DH is dapsone at doses of 50–200 mg daily with most patients reporting remarkable improvement within 24–48 hours. At doses greater than 100 mg daily,

3) Drug 정보 제공

- 전 세계 약물 정보 제공 (Chemical Structure, Classification, Dosage 등 제공)

ACCESSMedicine

Acetaminophen

Scale = 1/8" or 3.175mm

Strength: 325 mg

Labeler: Teva Pharmaceuticals USA Inc

Scored: Yes

Discontinued: Yes

Discontinued Date: 2010-05-13

Route: oral

Imprint: 44 104

Generic: Yes

Class: OTC

NDC: 00182-1000

AccessMedicine © 1978-Present McGraw-Hill and/or its respective owners.

4) 기타

- DDX : 1,000가지 이상의 가장 일반적인 질병, 진단에 대해 symptoms, disease, organ system 으로 검색 가능

- DX TEST : 실험실 테스트(laboratory tests)에서 일반적으로 많이 이용되는 정보 제공